

## Minimally Invasive Treatment of a Left-Ventricular Aneurysm Via a Left-Thoracic Thoracotomy as Re-Do

Felix Fleissner\*, Bakr Mashaqi, Constanze Merz, Axel Haverich and Issam Ismail

Division of Cardiac, Thoracic, Transplantation and Vascular Surgery, Hannover Medical School, Hannover, Germany

### Abstract

We report an 82-year male with a left ventricular a left-ventricular aneurysm via a left-thoracic thoracotomy as re-do. The patient received a supracommissural replacement of the aorta as well as a mitral valve repair half a year before the reoperation. He was diagnosed with an apical left ventricular aneurysm six months after the first operation and was re-administered to our clinic. He received a minimally invasive treatment of the left-ventricular aneurysm via a left-thoracic thoracotomy as re-op.

**Keywords:** Left ventricular aneurysm; Surgery; Minimally invasive

### Introduction


Acquired pseudo-aneurysm of the left ventricle is a disorder that usually occurs after transmural myocardial infarction or after cardiac surgery [1-3]. The danger of secondary rupture is real for large pseudo-aneurysms, but under discussion for smaller ones. Untreated pseudo-aneurysms have an approximately 30% to 45% risk of rupture [4]. The surgical risk of repair is barely known, due to the small number of series published. Left ventricular pseudo-aneurysms usually present with symptoms, but about 10% of patients are asymptomatic [4]. This 82-year-old patient was diagnosed with an apical left ventricular aneurysm in a routine post-operative control during rehabilitation. There are different surgical techniques for surgery and each individual case requires careful decision making.

### Case Report

A 82 year old male was primarily operated due to severe mitral valve regurgitation and a concomitant aneurysm of the ascending aorta. He received a supracommissural replacement of the ascending aorta and a mitral valve repair. He recovered fine after this operation. A postoperative echocardiography showed a patent mitral valve after replacement. He was administered for rehabilitation in good state. However, an echocardiogram three weeks later, after completion of rehab showed signs of an apical left ventricular pseudo-aneurysm. Left ventricular ejection fraction was estimated with 45%. He was re-administered to our clinic a trans-esophageal echocardiography a computed tomography showed an apical left ventricular pseudo aneurysm of approximately 5 cm to 6 cm diameter with a neck of approximately 1.5 cm (Figure 1). He was operated via a left antero-lateral thoracotomy. Cardiopulmonary bypass was established via the right femoral artery and vein. He received a modified DOR plasty using a Dacron patch (Figure 2). The left anterolateral thoracotomy was performed via the 5th intercostal space. The endocardial scar was characterized with a whitish appearance and was extensively identified in the anteroseptal and lateral area. The aneurysm was resected and a large thrombus revealed and removed (Figure 2). The endoventricular circular suture using pledgeted valve sutures and a 4-0 prolene circumferential suture was used to attach a Dacron approximately 2 × 5 cm in diameter. After hemostasis was secured, the excluded myocardial edge was re-approximated directly above the patch using another 4-0 prolene suture. The cardiopulmonary bypass was discontinued uneventfully. Postoperative course was uneventful and the patient recovered fast. Postoperative echocardiography revealed a left ventricular ejection fraction of 60% with a restored left ventricle. He was discharged ten days after the operation.

### Discussion

Because of the rareness of the disease each patient must be considered individually and the best possible care should be applied. The repair of postsurgical pseudoaneurysms is technically demanding because of adhesions and possible presence of bypass grafts. The minimally invasive approach is technically feasible and by using a separate thoracotomy, adhesions and bypass grafts are avoided. The pseudoaneurysm can be easily approached and repaired from the outside of the heart. Other surgeons have reported an approach from the inside of the heart with exclusion of the pseudoaneurysm. In this approach, the left atrium is opened, the mitral valve temporarily removed, and the neck of the pseudoaneurysm directly closed or covered with a patch [4]. However, this approach requires a medial sternotomy which in the case of a postsurgical pseudoaneurysm is prone for complications due to adhesions and possible bypass grafts. By the approach via the left anterolateral thoracotomy complications involving problems following a sternotomy (e.g. sternum instability) are avoided. The Dor plasty restores the circular ventricular architecture by excluding the antero-septal scar, reduces the cavity to restore wall tension toward normal by means of the Laplace relationship, and thereby improves hemodynamic status. In our patient, the left ventricular ejection fraction recovered completely [5].



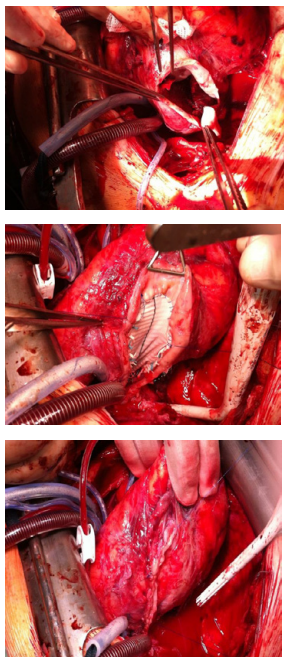
**Figure 1:** a) Computed tomography showing the large ventricular aneurysm after the primary cardiac surgery (\*). The patient also presented with large pleural effusions due to the developed cardiac insufficiency. b) Echocardiographic two chamber view showing the left ventricular pseudoaneurysm (#).

**\*Corresponding author:** Felix Fleissner, Division of Cardiac, Thoracic, Transplantation and Vascular Surgery, Hannover Medical School, Hannover, Germany, Tel: +495115322184; Fax: +495115329833; E-mail: Fleissner.Felix@mh-hannover.de

**Received** February 25, 2017; **Accepted** March 17, 2017; **Published** March 22, 2017

**Citation:** Fleissner F, Mashaqi B, Merz C, Haverich A, Ismail I (2017) Minimally Invasive Treatment of a Left-Ventricular Aneurysm Via a Left-Thoracic Thoracotomy as Re-Do. J Clin Case Rep 7: 939. doi: 10.4172/2165-7920.1000939

**Copyright:** © 2017 Fleissner F, et al. This is an open-access article distributed under the terms of the Creative Commons Attribution License, which permits unrestricted use, distribution, and reproduction in any medium, provided the original author and source are credited.



**Figure 2:** a) the opened large left ventricular pseudoaneurysm (\*) b) the Dacron patch in place of the aneurysm using single pledgeted sutures and a 4-0 prolene circumferential suture. C) After hemostasis was secured, the excluded myocardial edge was re-approximated directly above the patch using another 4-0 prolene suture.

## References

1. Komeda M, David TE (1993) Surgical treatment of post-infarction false aneurysm of the left ventricle. *J Thorac Cardiovasc Surg* 106: 1189-1191.
2. Sakai K, Nakamura K, Ishizuka N, Nakagawa M, Hosoda S (1992) Echocardiographic findings and clinical features of left ventricular pseudoaneurysm after mitral valve replacement *Am Heart J* 124: 975-982.
3. Yeo T, Malouf JF, Oh JK, Seward JB (1998) Clinical profile and outcome in 52 patients with cardiac pseudoaneurysm *Ann Intern Med*, 128: 299-305.
4. Frances C, Romero A, Grady D (1998) Left ventricular pseudoaneurysm, *J Am Coll Cardiol* 32: 557-561.
5. Prêtre R, Linka A, Jenni R, Turina MI (2000) Surgical treatment of acquired left ventricular pseudoaneurysms. *Ann Thorac Surg* 70: 553-557.