

# Minimally Invasive Surgery for Small Bowel Obstruction: The Experience of a Tertiary Hospital in the Anglo-Caribbean

Nigel Bascombe\*, Kelly-Ann Bobb and Dilip Dan

University of the West Indies, St. Augustine, Trinidad, West Indies

## Abstract

**Objectives:** The aim of this study was to assess the feasibility and benefit of minimally invasive surgery for Small Bowel Obstruction in a tertiary hospital in Trinidad and Tobago.

**Design and Methods:** All patients with clinical and radiologically diagnosed small bowel obstruction, who had nil resolution with conservative management at 48 hours, or who had nil passage of oral contrast into the colon at 12 hours, were included in this case series. Exclusion criteria included: anesthesiological contraindication for laparoscopy. The primary endpoints were resolution of obstruction (time to first bowel movement, time to commencement of oral feeds) and length of hospital stay. Secondary endpoints included overall morbidity and operative complications (bleeding, subphrenic or pelvic intraabdominal abscesses, wound infections, respiratory complications), during and after hospitalisation.

**Results:** There were five (5) patients who meet the inclusion criteria for this case series from January 2014 to March 2015. 40% (2/5) of the patients were female. The mean age was 38.4 yrs. Conversion rate was 0%. The enterotomy rate was 20% (1/5). The median duration of postoperative ileus was 5 days. The median duration of postoperative hospital stay was 5.6 days, mean time to enteral feeds was 1.8 days. Rate of post-operative complications was 20% (1/5).

**Conclusion:** With appropriate patient selection, minimally invasive surgery is a safe alternative to open surgery for SBO, with acceptable morbidity and mortality.

**Keywords:** Laparoscopy; Small bowel obstruction

## Introduction

Small bowel obstruction (SBO) is a common surgical emergency [1]. Open adhesiolysis has been established as the standard of care for those patients who do not resolve with conservative management. However, it has been associated with further formation of intra-abdominal adhesions with approximately 10% to 30% of patients requiring another laparotomy for recurrent bowel obstruction [2].

As laparoscopic emergency surgery continues to gain acceptance with the surgical fraternity, we continue to see new pathologies utilizing this form of surgical management [3]. Laparoscopic adhesiolysis has proven to have a series of benefits: decrease post-operative pain, faster return of intestinal function, shorter hospital stay, decreased wound complications, and decreased postoperative adhesion formation [4,5].

Laparoscopic adhesiolysis is still a very new option for the management of SBO. There are numerous studies demonstrating the feasibility of laparoscopy in the management of acute adhesive small-bowel obstruction. However, there are minimal randomized control trials on Laparoscopic versus open adhesiolysis. The aim of this study was to assess the feasibility and benefit of laparoscopic adhesiolysis in our setting.

## Patients and Methods

From January 2014 through March 2015, 5 consecutive patients with clinical and radiological signs of acute SBO were admitted to one of the surgical units at The Eric Williams Medical Science Complex, Trinidad and Tobago. The diagnosis was confirmed on review of plain supine and erect abdominal x-rays; illustrating dilated small bowel loops with greater than three (3) air fluid levels. Baseline blood investigations included serum electrolytes and a complete blood count.

Once there were no signs of peritonitis, all patients had

commencement of conservative management with placement of a nasogastric tube (NGT) on free drainage, appropriate intravenous fluids and nil by mouth status [6-8]. All patients were given water soluble contrast (Ultravist) via the NGT, followed by serial abdominal radiographs at 4, 6 and 8 hours [6,7]. Failure of conservative management was defined as nil advancement of contrast into the colon at 8 hours with no clinical signs of resolution of obstruction (Figure 1) [9,10]. Surgical intervention was then deemed necessary for these patients, who then went on to have laparoscopic adhesiolysis after appropriate consent was obtained. All data was collected prospectively.

## Laparoscopic technique

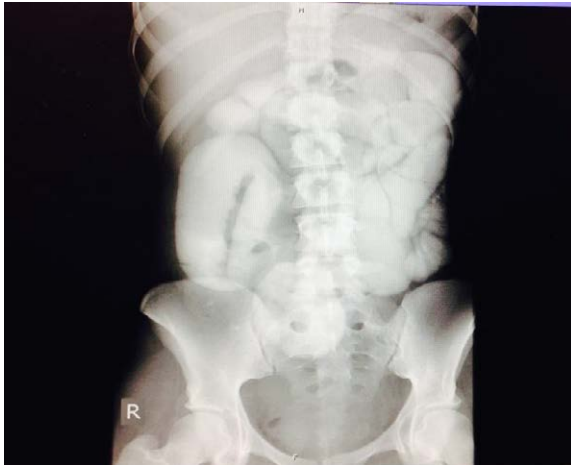The first port was inserted at an alternate site, away from the previous incisions, for all 4 of the patients with previous laparotomies. Palmer's point was the main site used and entry into the peritoneal cavity was obtained using an optical trocar. Subsequent ports were inserted under direct vision. The locations and number of ports were determined at the time of surgery after inspection of the abdominal cavity. The collapsed distal bowel was identified from the ileocecal region and followed until the transition point was identified (Figure 2). Obstructing adhesions were divided with laparoscopic scissors, and the

\*Corresponding author: Nigel Bascombe, 10 Dahlia Walk, Dorrington Gardens, Diego Martin, Trinidad, West Indies, Tel: 1(868) 683-7858; Fax: 1(868) 632-9168; E-mail: [nigelantonio@hotmail.com](mailto:nigelantonio@hotmail.com)

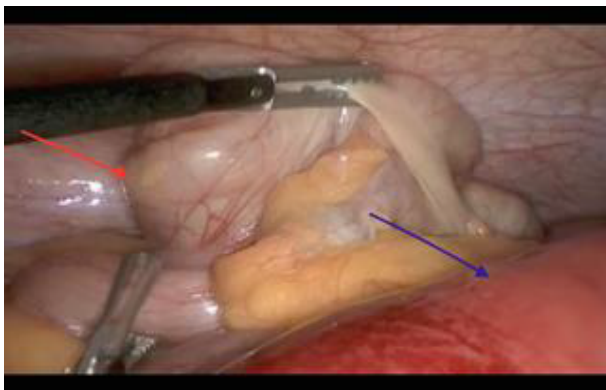
Received June 09, 2015; Accepted August 24, 2015; Published August 29, 2015

**Citation:** Bascombe N, Bobb KA, Dan D. Minimally Invasive Surgery for Small Bowel Obstruction: The Experience of a Tertiary Hospital in the Anglo-Caribbean. Journal of Surgery [Jurnalul de chirurgie]. 2015; 11(3): 107-109 DOI: [10.7438/1584-9341-11-3-4](https://doi.org/10.7438/1584-9341-11-3-4)

**Copyright:** © 2015 Bascombe N, et al. This is an open-access article distributed under the terms of the Creative Commons Attribution License, which permits unrestricted use, distribution, and reproduction in any medium, provided the original author and source are credited.



**Figure 1:** Supine abdominal X-ray with oral contrast. This X-ray illustrates, failure of progression of water-soluble contrast into the colon.



**Figure 2:** Intra-operative photograph. Photograph showing collapsed ileocecal region (red arrow) from where the bowel will be followed towards the proximal site of obstruction (the transition zone). The purple arrow shows the dilated proximal intestine.

bowel was inspected for viability. All adhesiolysis was done by sharp dissection. Ports were removed under direct vision the fascial defects of port sites greater than 5 mm were closed with 0 vicryl.

**Results**

Five patients who presented with acute small bowel obstruction and failed conservative management underwent laparoscopic adhesiolysis. There were 3 males and 2 females of a mean age of 38.4 years (Range 17-71 yrs.). All of these patients completed laparoscopic treatment. Thus the conversion rate was 0%.

Table 1 summarizes the patient’s characteristics and intra operative findings. Four (80%) of these patients had previous abdominal surgery. There was one (20%) patient with a virgin abdomen.

The aetiology of small bowel obstruction in this series included single bands and multiple adhesions. Two (40%) of the patients had a single obstructing band, whereas the others had multiple adhesions.

There was a single case of bowel injury. This occurred with the patient who had two previous surgeries. The patient originally had an operation for a perforated appendix, and was taken back to the theatre for development of a pelvic abscess, which was not amenable to radiological aspiration. Thus the patient had extensive dense adhesions. During sharp dissection of a thick adhesive band between the small bowel and anterior abdominal wall, an enterotomy occurred with

minimal spillage, and it was repaired laparoscopically with 2-0 mersilk. The above patient tolerated oral feeds by day two (2) post operatively and was discharged on day three (3) post operatively.

The mean operative time was 90 minutes (Range 64-120). The eldest patient from this case series developed pneumonia seven days after being discharged from hospital. There were no mortalities and no other morbidity. Complications are summarized in Table 2.

**Discussion**

There have been a number of guidelines established to assist in evidence-based management of acute SBO. The Bologna Guidelines which was updated in 2013 by the world society of emergency surgery working group on adhesive SBO; sought to give indications for laparoscopy in the management of acute SBO. The Bologna guidelines concluded that laparoscopic adhesiolysis is a safe and feasible alternative to the open approach in experienced hands and selected patients [10]. This conclusion has been echoed by similar guidelines such as Vettoretto et al. consensus conference guidelines [9] and Eastern Association for the Surgery of Trauma practice management guideline for small bowel obstruction [11]. These guidelines are based on a preponderance of Class III evidence. Therefore, to definitively access the benefits and complications of laparoscopic adhesiolysis, prospective randomized studies are required.

As the indications for laparoscopic surgery in the emergency setting continues to expand, it is expected to encompass the surgical management of acute SBO also.

There are several retrospective studies and meta-analysis comparing open and laparoscopic approaches, which have revealed less complications and shorter hospital-stay with the laparoscopic

**Table I:** Patient characteristics and operative information.

Sex: Age (yr)	Laparoscopic Findings	Procedure
Previous laparotomy [4]		
M: 26	Post appendectomy adhesions: Multiple adhesions to anterior abdominal wall, two restricting bands at distal ileum	Laparoscopic adhesiolysis
F: 17	Post appendectomy + Cecectomy adhesiolysis: Extensive adhesions, single adhesive band	Laparoscopic adhesiolysis Suture closure of enterotomy
F: 48	Post myomectomy adhesions: Adhesions between uterus and SB at sites of myomectomy	Laparoscopic adhesiolysis
M: 30	Post laparotomy adhesions: Multiple adhesions at proximal small bowel	Laparoscopic adhesiolysis
Virgin abdomen [1]		
M: 71	Omental band obstructing jejunum	Laparoscopic adhesiolysis

**Table II:** Perioperative complications.

	Total
<b>Duration of ileus</b>	
Median (days)	5
Range	2-4
<b>Length of Hospital stay</b>	
Median (days)	5.6
Range	2-7
<b>Access Injury</b>	0
<b>Enterotomy</b>	1
<b>Bleeding</b>	0
<b>Wound Complications</b>	0
<b>Pulmonary Complications</b>	1
<b>Death (30 day mortality)</b>	0

approach [12-15]. It is on this background that we sought to define our experience and outcomes with laparoscopic adhesiolysis in our patient population.

The issue of safety in the laparoscopic management of acute SBO must always be considered. Peritoneal access by using the 'alternative site technique' has been suggested by many authors [2]. In our setting, the use of an optic scope has been proven to be a safe method to gain entry into the peritoneal cavity. Finding the site of obstruction can be difficult if the bowel is severely dilated, or if there are extensive dense adhesions.

Suter et al. defined distended loops of bowel (4 cm) as an absolute contraindication to laparoscopic adhesiolysis [16]. However, we have noted from our experience, that minimal, careful manipulation of the distended bowel while directing our attention to the collapsed bowel, which is much easier to manipulate, and careful sharp dissection of adhesions; allows for safe and efficient adhesiolysis.

Earlier series had a very low threshold for conversion to laparotomy in patients with distended bowel loops and extensive adhesions [13]. This would explain the longer operative time experienced in our series, as these patients had complete definitive treatment laparoscopically.

The surgeon's expertise allowed the conversion rate to be 0%, as the only case of an enterotomy was closed by suturing laparoscopically. Enterotomy is one of the common reasons for conversion in earlier series.

There is presently a prospective, randomized control trial enrolling patients to compare open surgery to laparoscopic adhesiolysis in patients with computed tomography diagnosed adhesive SBO [17]. This trial will provide level 1b evidence for the use of laparoscopy in the management of adhesive SBO, and we look forward to its conclusion.

## Conclusion

This series shows that minimally invasive surgery is feasible in patients with acute SBO. Definitive laparoscopic management was possible in all patients with minimal peri-operative morbidity. These findings support laparoscopic surgery as the primary surgical intervention in SBO, once performed by an experienced surgeon.

## Conflict of interests

The authors declared no potential conflicts of interest with respect to the research, authorship, and publication of this article.

## References

1. Barmparas G, Branco BC, Schnuriger B, Lam L, Inaba K, et al. (2010) The incidence and risk factors of postlaparotomy adhesive small bowel obstruction. *J Gastrointest Surg* 14: 1619-1628.
2. Landercasper J, Cogbill TH, Merry WH, Stolee RT, Strutt PJ (1993) Long-term outcome after hospitalization for small-bowel obstruction. *Arch Surg* 128: 765-770
3. Dilip Dan, Nigel Bascombe, Dave Harnanan, Shariful Islam, Vijay Naraynsingh (2014) Minimally Invasive Surgery in the Management of adhesive small bowel obstruction: A rare case. *J Gastroint Dig Syst* 4: 4
4. Nagle A, Ujiki M, Denham W, Murayama K (2004) Laparoscopic adhesiolysis for small bowel obstruction. *Am J Surg* 187: 464-470.
5. Szomstein S, Lo Menzo E, Simpfendorfer C, Zundel N, Rosenthal RJ, et al. (2006) Laparoscopic lysis of adhesions. *World J Surg* 30: 535-540.
6. Biondo S, Pare's D, Mora L, Marti' Rague' J, Kreisler E, et al. (2003) Randomized clinical study of Gastrografin administration in patients with adhesive small bowel obstruction. *Br J Surg* 90: 542-546.
7. Fevang BT, Jensen D, Fevang J, Sondenaa K, Ovrebø K, et al. (2000) Upper gastrointestinal contrast study in the management of small bowel obstruction - a prospective randomised study. *Eur J Surg* 166: 39-43.
8. Di Saverio S, Catena F, Ansaloni L, Gavioli M, Valentino M, et al. (2008) Water-soluble contrast medium (Gastrografin) value in adhesive small intestine obstruction (ASIO): a prospective, randomized, controlled, clinical trial. *World J Surg* 32: 2293-2304.
9. Vettoretto N1, Carrara A, Corradi A, De Vivo G, Lazzaro L, et al. (2012) Laparoscopic adhesiolysis: consensus conference guidelines. *Colorectal Dis* 14: e208-e2015.
10. Di Saverio S1, Coccolini F, Galati M, Smerieri N, Biffi WL, et al. (2013) Bologna guidelines for diagnosis and management of adhesive small bowel obstruction (ASBO): 2013 update of the evidence-based guidelines from the world society of emergency surgery ASBO working group. *World J Emerg Surg* 8: 42.
11. Maung AA, Johnson DC, Piper GL, Barbosa RR, Rowell SE, et al. (2012) Evaluation and management of small-bowel obstruction: An Eastern Association for the Surgery of Trauma practice management guideline. *J Trauma*. 73: S362-S369.
12. Ghosheh B, Salameh JR (2007) Laparoscopic approach to acute small bowel obstruction: Review of 1061 cases. *Surg Endosc* 21: 1945-1949.
13. Al-Mulhim AA (2000) Laparoscopic management of acute small bowel obstruction. Experience from a Saudi teaching hospital. *Surg Endosc* 14: 157-160.
14. Li MZ, Lian L, Xiao LB, Wu WH, He YL, et al. (2012) Laparoscopic versus open adhesiolysis in patients with adhesive small bowel obstruction: a systematic review and meta-analysis. *Am J Surg* 204: 779-786.
15. Levard H, Boudet MJ, Msika S, Molhou JM, Hay JM, et al. (2001) Laparoscopic treatment of acute small bowel obstruction: A multicentre retrospective study. *Aust N Z J Surg* 71: 641-646.
16. Suter M, Zermatten P, Halkic N, Martinet O, Bettschart V (2000) Laparoscopic management of mechanical small bowel obstruction: are there predictors of success or failure? *Surg Endosc* 14: 478-483.
17. Sallinen V, Wikström H, Victorzon M, Salminen P, Koivukangas V, et al. (2014) Laparoscopic versus open adhesiolysis for small bowel obstruction - a multicenter, prospective, randomized, controlled trial. *BMC Surgery* 14: 77.