

## Minimally Invasive Spine Osteosynthesis (MISO) Technique for Fractures Spine: A Case Series 14 Cases

Bahaa Ali kornah<sup>1\*</sup>, Hesham Mohamed safwat<sup>1</sup> and Mohamed A Abdel-aal<sup>2</sup>

<sup>1</sup>Orthopedic Surgery, Al-Hussain University Hospital Orthopedic Department 4th Floor Al Azhar University, Cairo, Egypt

<sup>2</sup>Consultant Orthopedic Surgery, El-Bakry General Hospital, Ministry of Health, Cairo, Egypt

\*Corresponding author: Bahaa Ali Kornah, Professor Orthopedic surgery, Al-Hussain University Hospital Orthopedic Department 4th Floor Al Azhar University, Cairo, Egypt, Tel: +00201117687777; Fax: 0020233459906; E-mail: bkornah@yahoo.co.uk

Rec date: Aug 02, 2016; Acc date: Oct 06, 2016; Pub date: Oct 08, 2016

Copyright: © 2016 kornah BA, et al. This is an open-access article distributed under the terms of the Creative Commons Attribution License, which permits unrestricted use, distribution, and reproduction in any medium, provided the original author and source are credited.

### Abstract

**Background:** The choice of treatment of dorso-lumbar spinal fractures in the absence of neurological deficit depends on the classification and severity of injury. In the conventional open approach with posterior pedicle screw fixation, detachment of the Para spinal muscles may be required. In addition, this open approach may be disadvantaged by prolonged operative time, increased intraoperative bleeding and delayed functional rehabilitation. All these problems appear to encourage orthopedic surgeons to limit secondary iatrogenic insult in these patients by mini open surgery. The goal of this study is to evaluate the effectiveness of minimally invasive treatment of dorso-lumbar fractures by mini open surgical pedicle screw fixation and to discuss the potential benefits and drawbacks of this procedure.

**Patients and methods:** This is a prospective study involves 14 Patients (10 males) treated and followed between Feb. 2010 to Feb 2014. All had acute traumatic single level dorso-lumbar spine fractures, age range 17-47 years (mean  $30.1 \pm 7.9$  yrs). Patients with pathological fractures, neurological injury, anatomical variations of the cord or vertebrae, mental illness, significant surgical contraindications, osteoporosis, refusing to sign informed consent and those with (TLICS) score  $\leq 4$  or load sharing score  $\geq 7$  were excluded from the study. All the cases had been treated by minimal invasive posterior approach. Total of 56 screws and 28 rods were applied utilizing the conventional posterior instrumentation.

**Results:** Mean post-operative hospital stay 3.8 days. No major complications as spinal cord, nerve root or blood vessel injuries occurred. No screws were broken and just two screws were malpositioned. All patients improved clinically, and the outcome (according to modified MacNab criteria) was considered excellent in six patients, good in seven, and poor in one patient.

**Conclusion:** Mini open surgery for posterior pedicle screws fixation has attracting increasing attention as it brings a multitude of advantages including: less bleeding, lower incidence of postoperative intractable low back pain and reduced hospitalization stay. However; some shortcomings as limited indications, unsuitability for long segment fusion and high load-sharing score patients restricts its worldwide prevalence.

**Keywords:** Spine fixation; Minimal spine fixation; Pedicular screw fixation

The purpose of this study is describing and evaluating minimal invasive posterior fixation technique of thoracolumbar spine using ordinary pedicular screws and instrumentations.

### Introduction

Spine fractures are serious injuries and thoracolumbar spine is one of the most common areas for spinal fractures [1]. Regardless of selected protocol of treatment, the target continues to be restoration of spinal stability, decompression of spinal canal and earlier mobilization of the patient [2]. Short-segment pedicle fixation (SS) had been developed for operative stabilization of thoracolumbar and lumbar fractures. It has become increasingly popular worldwide as they engage all three columns of the spine and can resist motion in all planes [3,4].

Pedicular screws can be inserted either by Standard open techniques which involve open exposures and extensive muscle dissection or through percutaneous approach which needs specialized equipments and long learning curve before implementation [5,6].

### Patients and Methods

This prospective case series study involved 14 patients (10 males and 4 females) with acute traumatic single level dorsal or lumbar spine fractures without neurological insult. They underwent minimally invasive spine fixation between 2010 and 2014. Causative injuries were fall from height (9 patients), road traffic accidents (4 patients) and in one case drop of heavy box over the back while working. Age range 17 to 47 years (mean  $30.1 \pm 7.9$  yrs). Six patients (L1) fracture 2 patients (L2) fractures, 2 patients (L3) fractures and 4 patients (D 12) fractures.

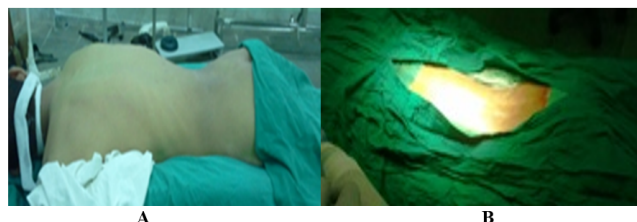
Inclusion criteria involved: single segment vertebral fractures without neurological deficits, patient not in need for decompression of the neural elements, mechanically unstable burst fractures and displaced bony fragments which could be reduced by ligamentotaxis

within 48 to 72 hours after injury. Exclusion criteria involved: pathological fractures, neurological injury, anatomical variations of the cord or vertebrae, mental illness, significant surgical contraindications, osteoporosis, patients refusing to sign informed consent and those with (TLICS)score <4 or load sharing score  $\geq 7$ .

In all our cases (TLICS) score was  $\geq 4$  and load sharing score was 6 or less who were suitable for short-segment posterior spinal instrumentation and not in need for decompression or supplementary anterior stabilization. All procedures had been approved by the board of ethical committee of the hospital and a written consent had been obtained from all patients [7,8].

### Surgical technique

Patient positioning and anesthesia performed as similar as the conventional posterior open approach (Figure 1A and 1B). The target segment determined by C-arm. One level above and below the fractured vertebra incised and the length of the incision was about 2 cm (Figure 2).



**Figure 1:** Pictures showing prone position on a special frame (A), proper disinfection and draping (B).

Thoracolumbar fascia incised lateral to the supraspinous ligament, and the paraspinal muscles were stripped subperiosteally along the sides of the spinous processes and vertebral laminae till the outer edge of facet joints with a Cobb elevator and a gauze swab in both sides from the same incision. Dissection continued down the lateral side of the facet and onto the transverse process with proper homeostasis of the area. Care should be taken not to injure the facet joint capsule if no fusion technique was planned.

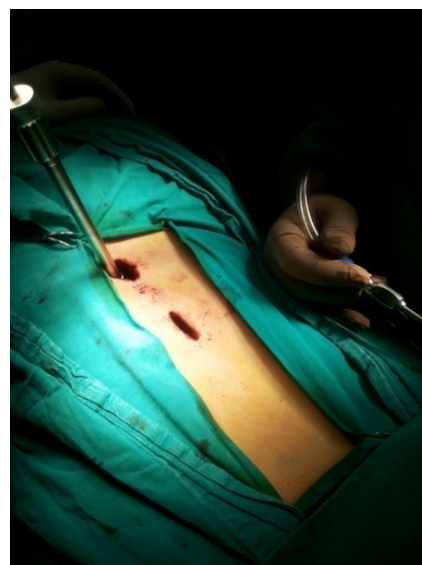The entry point was determined through anatomical landmarks used in the conventional open technique, rechecked by C-arm imaging. Pedicle screw entry site and screw side trajectory were properly identified under direct vision and the screw was inserted using the free hand technique with C-arm control (Figure 3). After application of 4 screws, a contoured rod passed in sub-muscular plan with minimal manipulation, essentially no muscle dissection and without the need for direct visual feedback.

The reduction and screws position were checked by the image intensifier (Figure 4). Application of distraction by distractor until correction of vertebral height (if possible) was achieved and the correction was maintained by tightening screw head nuts (Figure 5). The wounds were closed in layers and in most of cases no need for drain required.

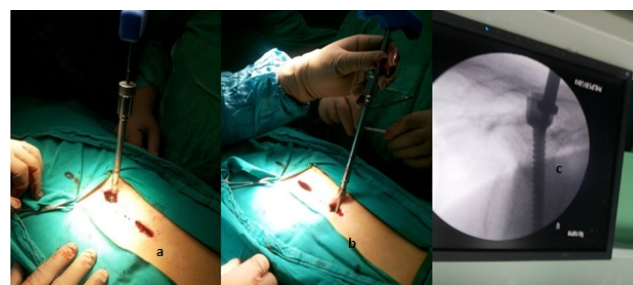
### Postoperative care

Patient was neurologically tested before leaving the operating room and kept flat for a period of 24 hours after surgery with close

observation to vital signs. Post-operative antibiotics were continued for 5 days. All our patients were mobile 48 hours after surgery and were discharged on postoperative day 2 (7 cases), day 3 (5 cases) and 2 patients were discharged on postoperative day 5 and 7 days due to associated injuries.



**Figure 2:** 2 cm incision.



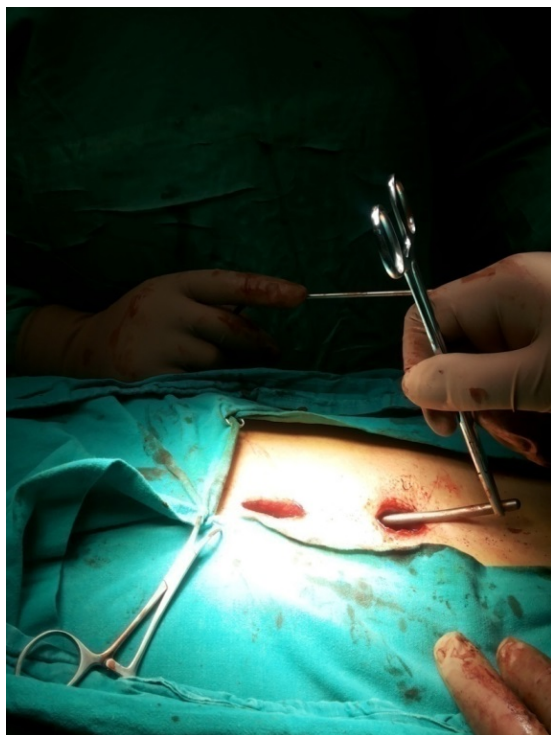
**Figure 3(a-c):** Screw side trajectory were properly identified under direct vision and the screw was inserted using the free hand technique with C-arm control.

The mean hospital stay was 3.8 days. Routine clinical and radiological checks up were done monthly for first three months (Figure 6), then every three months afterwards. Multi slice CT scans were performed and repeated every 6 months till assurance of bone healing.

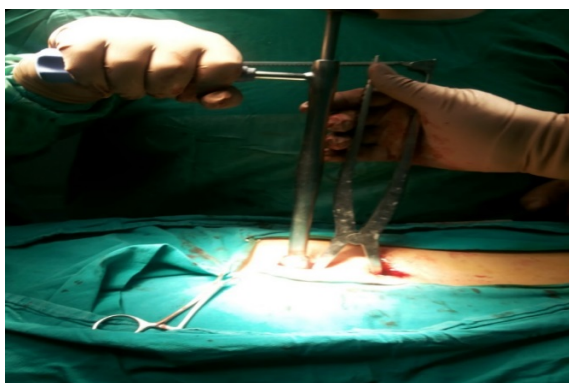### Results

The follow-up period ranged 8 to 14 months (mean 6.8 months). We used the following parameters which had been utilized by many authors [9,10]. They included: operative time, blood loss, radiation exposure time, kyphotic angle correction, vertebral height index, diameter of medullary canal in immediate and post-operative CT scans, accuracy rate of screws position, hospital stays and visual analog

scale (VAS). Clinical outcome classified according to modified MacNab criteria (Table 1) [11].

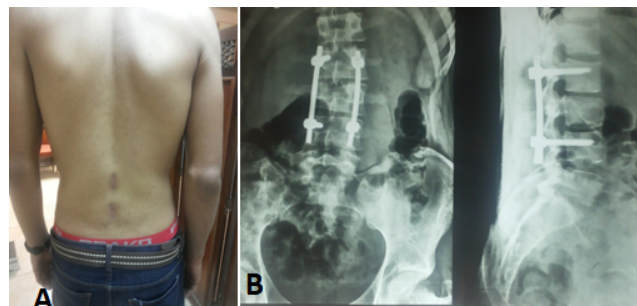


**Figure 4:** A contoured rod passed in sub muscular plan with minimal manipulation.



**Figure 5:** Shows how can used the distractor.

Operative time ranged 50 to 105 minutes (mean 73.8 minutes) with the longer times occurring in early cases. Mean blood loss was not exceeding 40 ml. Mean radiation exposure time 11.3 seconds (8.3 to 13.6 seconds). Kyphotic angle was measured on lateral radiographs as the angle of the vertical line to the upper endplate of the upper adjacent vertebral body and lower endplate of the lower adjacent vertebral body.



**Figure 6(A and B):** Shows the healing scar of surgery with patient post operative X-ray.

The angle improved by mean of  $25.3^\circ$  ( $21.4^\circ$  to  $29.3^\circ$ ). Vertebral height index (VHI) value was determined by the following formula:

The mean height of fractured vertebral body/the mean height of upper and lower vertebral bodies  $\times 100\%$ .

Improvements in vertebral height index and medullary canal diameter post operatively and during follow-up shown in Tables 2 and 3 respectively. Accuracy of pedicle screws positions were assessed by examining postoperative CT scans. Total number of 56 screws and 28 rods were applied of which 2 screws in two patients were malpositioned (3.1%). Intraoperative correction was done in one case and open conversion surgery was done in the second case due to difficulty in rod positioning. The accuracy rate of screw placement was 96.9%.

<b>Excellent</b>	Complete resolution of all symptoms and free of pain; no restriction of mobility; able to return to normal work and activities
<b>Good</b>	Marked reduction of pain with the patient generally satisfied, returning to work or usual daytime activities, and taking analgesics seldom or not at all
<b>Fair</b>	Some improved functional capacity; still handicapped and/or unemployed
<b>Poor</b>	Continued objective symptoms of root involvement; additional operative intervention needed at index level, irrespective of repeated operations or length of postop. FU
<b>Worse</b>	Clinical symptoms considered worse than before receiving procedure

**Table 1:** Modified McNab criteria used to grade overall clinical outcome after spinal surgery [9].

Level Number	Pre-op	Post-op	Follow-up
D 12 4 p	58	86	84
L1 6 p	66	89	85
L2 2 p	62	87	85



L3 2 p	75	91	88
--------	----	----	----

**Table 2:** Mean vertebral height index (VHI).

Pain was evaluated via visual analogue scale (VAS) preoperatively, three days and one week postoperatively. Preoperative pain was high in all patients with mean (VAS) 7.9/10 (range 6-10) decreased to 4.2 at time of discharge (range 0-7) and to 0.7 at last follow-up (range 0-2) (Table 2 and 3).

All patients improved clinically, and the outcome (according to modified MacNab criteria) was considered excellent in six patients, good in seven, and poor in one patient (Figure 7).

Level Number	Pre-op	Post-op	Last Follow up
D12 4 p	182.34	211.33	207.51
L1 6 p	177.42	207.94	205.30
L2 2 p	168.20	181.73	
L3 2 p	189.3	204.22	

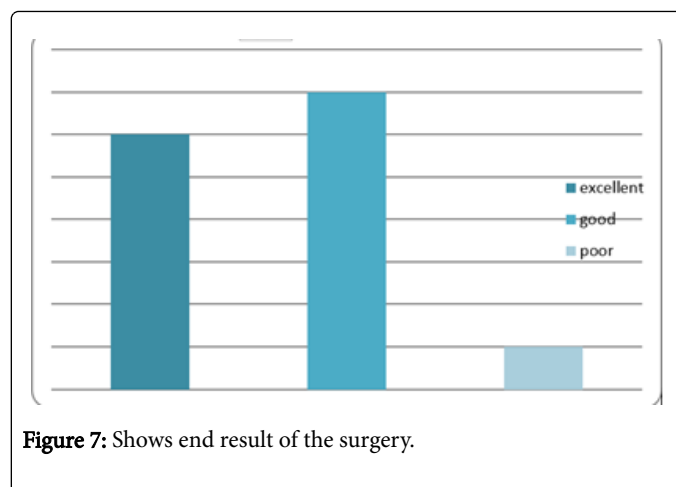
**Table 3:** Mean canal area in mm<sup>2</sup>.

## Discussion

It is known that traditional open approaches to spine surgery lead to increased paraspinal muscle injury secondary to prolonged retraction. In addition, there is an electrical-burn damage from electric knife [12]. Minimally invasive spine surgery has its roots in mid-twentieth century, but it has now developed into a large field of progressive spinal surgery [13]. As the technique became more mainstream over the past ten years, we try through this study to utilize the technique in spinal osteosynthesis of selected cases of thoraco-lumbar and lumbar fractures without neurological insults.

Interpretations of results of our study show that the technique is not in need for specialized instrumentations or screws and the pedicles are addressed via usual steps. Commonly partial spontaneous reduction is achieved when the patient turned to the prone position that restored the normal dorsal kyphotic and lumbar lordotic curves. Further indirect reduction and decompression are achieved by correction of Kyphosis and recreation of normal lordosis through application of contoured rod.

Less number of incisions, scars (2 small scars of approximately 2 centimeters) and minimal soft tissue damage are encountered. Radiation exposure for patient and surgeon had always been the focus of attention. It is about  $11.3 \pm 2.2$  seconds in our study which does not differ markedly from open conventional and less than percutaneous approach [14,15]. The need of blood transfusion decreased and none of our patients required it as the mean blood loss not exceeding 40 ml. In addition; we achieved restoration of vertebral body height, improvement of Cobb's angle and high accuracy rate of screw placement with results near to the open approach [16].



**Figure 7:** Shows end result of the surgery.

Also we have some loss of vertebral height in long-term follow-up similar to the open approach [17]. The operative time ranged between 50 to 105 minutes (mean 73.8 minutes) with the longer operative times occurring in early cases. A steep learning curve could be gained easily to build the necessary skills and experience as most of spinal surgeons are familiar with pedicle targeting. The approach had rapid recovery and patient activity was permitted two weeks after surgery and all patients were satisfied from cosmetic appearance of the scar.

Our approach is more advantageous than percutaneous technique which requires specialized equipment's and long learning curve before implementation. In addition, there is high incidence of screw malposition and large doses of radiation exposure [18].

The great protests directed to our approach is the narrow scale for indication as it is unsuitable for long segment posterior laminectomy and posterolateral fusion, limitations to cases with single segment thoracolumbar or lumbar vertebral fractures and cases with load-sharing score 6 or maximally 7 points because these figures ascertain efficacy of only posterior stabilization [19].

According to modified McNab criteria we have:

6 cases - Excellent (42.9%)

7 cases - Good (50%)

One case - Poor (7.1%)

## Conclusion

Minimally invasive screw osteosynthesis (MISO) technique is a safe and worthwhile method of managing spine fractures in cases not in need for decompression. Although this study is limited by its small sample size but the results demonstrate that it is advantageous regarding, minimal soft tissue dissection and lack of need for special instrumentations consequently it is cost effective with short hospital stay and faster return to work and daily activities. Mastering the technique not only require practice but also familiarity with pedicular screw insertion. By experience; the technique enables surgeons to achieve the same surgical objectives as with a traditional open procedure.

## Conflict of interest

The authors certify that they have NO affiliations with or involvement in any organization or entity with any financial interest or non-financial interest in the subject matter or materials discussed in this manuscript.

## References

1. Magerl F, Aebi M, Gertzbein SD, Harms J, Nazarian S (1994) A comprehensive classification of thoracic and lumbar injuries. *Eur Spine J* 3: 184-201.
2. Gaines RW (2000) The use of pedicle-screw internal fixation for the operative treatment of spinal disorders. *J Bone Joint Surg Am* 82: 1458-1476.
3. Roy-Camille R, Saillant G, Mazel C (1986) Plating of thoracic, thoracolumbar and lumbar injuries with pedicle screw plates. *Orthop Clin North Am* 17: 147-159.
4. Yuan HA, Garfin SR, Dickman CA, Mardjetko SM (1994) A historical cohort study of pedicle screw fixation in thoracic, lumbar and sacral spine fusions. *Spine* 19: 2279-2296.
5. Dick W, Kluger P, Magerl F, Woersdorfer O, Zach G (1985) A new device for internal fixation of thoracolumbar and lumbar spine fractures: The 'fixateur interne'. *Paraplegia* 23: 225-232.
6. Lowery GL, Kulkarni SS (2000) Posterior percutaneous spine instrumentation. *Eur Spine J* 9: 126-130.
7. Lee JY, Vaccaro AR, Lim MR (2005) Thoracolumbar injury classification and severity score: a new paradigm for the treatment of thoracolumbar spine trauma. *J Orthop Sci* 10: 671-675.
8. McCormack T, Karaikovic E, Gaines RW (1994) The load sharing classification of spine fractures. *Spine* 19: 1741-1744.
9. Rampersaud YR, Annand N, Dekutoski MB (2006) Use of minimally invasive surgical techniques in the management of thoracolumbar trauma: Current concepts. *Spine* 31: 96-102.
10. Palmisani M, Gasbarrini A, Brodano GB (2009) Minimally invasive percutaneous fixation in the treatment of thoracic and lumbar spine fractures. *Eur Spine J* 18: 71-74.
11. Macnab I (1971) Negative disc exploration: an analysis of the cause of nerve root involvement in sixty-eight patients." *J Bone Joint Surg Am* 53: 891-903.
12. Kawaguchi Y, Matsui H, Tsuji H (1996) Back muscle injury after posterior lumbar spine surgery. A histologic and enzymatic analysis. *Spine* 21: 941-944.
13. Corniola MV, Stienen MN, Tessitore E, Schaller K, Gautschi OP (2015) Minimally invasive spine surgery: past and present. *Rev Med Suisse* 18: 2186-2189.
14. Perisinakis K, Theocharopoulos N, Damilakis J, Katonis P, Papadokostakis G, et al. (2004) Estimation of patient dose and associated radiogenic risks from fluoroscopically guided pedicle screw insertion. *Spine* 29: 1555-1560.
15. El Tecle NE, El Ahmadih TY, Patel BM, Lall RR, Bendok BR, et al. (2014) Minimizing radiation exposure in minimally invasive spine surgery: lessons learned from neuroendovascular surgery. *Neurosurg Clin N Am* 25: 247-260.
16. Phan K, Rao PJ, Mobbs RJ (2015) Percutaneous versus open pedicle screw fixation for treatment of thoracolumbar fractures: Systematic review and meta-analysis of comparative studies. *Clin Neurol Neurosurg* 135: 85-92.
17. Vanek P, Bradac O, Konopkova R, de Lacy P, Lacman J (2014) Treatment of thoracolumbar trauma by short-segment percutaneous transpedicular screw instrumentation: prospective comparative study with a minimum 2-year follow-up. *J Neurosurg Spine* 20: 150-156.
18. Schizas C, Michel J, Kosmopoulos V (2007) Computer tomography assessment of pedicle screw insertion in percutaneous posterior transpedicular stabilization. *Eur Spine J* 16: 613-617.
19. Lee JK, Jang JW, Kim TW, Kim TS, Kim SH, et al. (2013) Percutaneous short-segment pedicle screw placement without fusion in the treatment of thoracolumbar burst fractures: is it effective?: Comparative study with open short-segment pedicle screw fixation with posterolateral fusion. *Acta Neurochir* 155: 2305-2312.