

Minimally Invasive Multilevel Percutaneous Pedicle Screw Fixation for Lumbar Spinal Disease

Sang Gu Lee*, Seong Son, Chan Woo Park and Woo Kyung Kim

Department of Neurosurgery, Gachon University, Gil Hospital, Incheon, South Korea

Abstract

Objective: There are rare reports on the result of multilevel (≥ 3 levels) percutaneous pedicle screw fixation (PPF). The purpose of this study was to report the clinical experiences for multilevel PPF of the lumbar spine.

Methods: A total of 17 patients of lumbar spinal disease (7 degenerative diseases, 6 infectious diseases, and 4 traumatic instabilities) underwent neural decompression and multilevel PPF. There were 8 men and 9 women with a mean age of 61.4 years (range: 25-84) and a mean follow-up period of 23.2 months (range: 13-48). The average PPF level was 3.7. A retrospective review of clinical, radiological, surgical data was conducted.

Results: "Excellent" or "good" clinical results were obtained in 15 patients (88.2%). The average improvement of visual analogue scale was 5.2 points (from 9.3 to 4.1), and the average improvement of Oswestry Disability Index was 36.2 (from 71.2 to 35.0) at the last visit ($p < 0.05$).

The fusion rate was 88.2%, but, screw loosening was occurred in 2 patients, and adjacent segmental degeneration was occurred in 2 patients. There was no statistical significance in the change of total lumbar lordotic angle. The average operation time was 5.9 hours, with an EBL of 550 ml and bed rest duration of 2 days.

Conclusions: Although the current study examined a small sample with relatively short term follow up periods, our study results demonstrate that multilevel PPF is feasible and safe for selective lumbar spinal disease.

Keywords: Spinal fusion; Lumbar vertebrae; Bone screws

Introduction

Minimally invasive spine surgery may allow for surgery of the lumbar spine with considerably less blood loss and soft tissue damage. Recently, to reduce the adverse effect of the open technique of pedicle screw, the percutaneous pedicle screw fixation (PPF) is becoming more widespread in spinal surgery. Many studies about PPF have been reported, but still, there are rare reports about the result of multilevel (≥ 3 levels) PPF [1-4]. This study analyzed the clinical, radiological, and surgical results of the multilevel PPF in various lumbar spinal diseases.

Materials and Methods

Patient population

From March 2008 to April 2011, a total of 17 patients of lumbar spinal disease underwent neural decompression, interbody fusion and multilevel PPF by one neurosurgeon. There were 8 men and 9 women with a mean age of 61.4 years (range: 25-84) and a mean follow-up period of 23.2 months (range: 18-43).

Below is a group list of our indications for such a procedure.

1. Multilevel degenerative diseases such as spinal stenosis, spondylolisthesis (Grade I), or instability, with symptoms refractory to conservative treatment.
2. Severe bone destruction with a spinal cord compression or a nerve root compression due to infectious diseases such as tuberculous spondylitis or pyogenic spondylitis.
3. Spinal instability with a spinal cord compression or a nerve root compression due to trauma.

Out of 17 patients, 7 patients were degenerative diseases, 6 patients were infectious diseases, and 4 patients were traumatic instabilities (Table 1). The patients, with excessive spondylolisthesis or severe spinal deformity such as scoliosis, kyphosis, and rotational deformity, were excluded from PPF procedure.

Procedures and instruments

We performed neural decompression and interbody fusion first. The Transforaminal Lumbar Interbody Fusion (TLIF) was performed in 9 patients, the posterior lumbar curettage and interbody fusion in 5 patients, and the anterior lumbar corpectomy and interbody fusion in 3 patients. Allograft iliac bone, mesh cage containing allograft bone chips, or polyether ether ketone (PEEK) cage containing allograft bone chips were used in interbody fusion.

And then, multilevel PPF was performed in prone position. The screws were placed percutaneously using fluoroscopic guidance. The cannulated screws, which were inserted over a guide wire, had extenders attached to them, which had a slot to receive the rod. Since the entry point of screw insertion in the middle pedicle is most important for alignment of spine, the insertion of screw in the middle pedicle was carried out lastly (Figure 1).

The slot was large enough in the unreduced position to accept a rod that was passed again percutaneous. The rod is contoured according to the sagittal contour desired and then passed free hand through the slots under direct fluoroscopic control. Once the rod is appropriately positioned through all the screw extender slots, the extender is reduced to seat the rod into the tulip of the screw head. Once reduced, the

***Corresponding author:** Sang Gu Lee, M.D., Ph.D., Department of Neurosurgery, Gachon University, Gil Hospital, 1198 block, Guweol-Dong, Namdong-Gu, Incheon, South Korea, 405-220, Tel: +82-32-460-3304; Fax: +82-32-460-3899; E-mail: samddal@gilhospital.com

Received November 11, 2012; **Accepted** December 19, 2012; **Published** December 21, 2012

Citation: Lee SG, Son S, Park CW, Kim WK (2013) Minimally Invasive Multilevel Percutaneous Pedicle Screw Fixation for Lumbar Spinal Disease. J Spine 2:128. doi:10.4172/2165-7939.1000128

Copyright: © 2013 Lee SG, et al. This is an open-access article distributed under the terms of the Creative Commons Attribution License, which permits unrestricted use, distribution, and reproduction in any medium, provided the original author and source are credited.

Diagnosis	Case	Sex	Age	Decompression (levels)	Levels of PPF
Degenerative disease	1	F	70	LN (1), TLIF (2)	3
	2	M	61	LN (1), TLIF (1)	3
	3	F	61	LN (2), TLIF (1)	4
	4	M	53	LN (1), TLIF (2)	3
	5	F	69	LN (1), TLIF 2	3
	6	F	55	TLIF (3)	3
	7	M	84	TLIF (3)	5
Infectious disease	8	M	70	LN (1), TLIF (2)	4
	9	M	71	Ant Co (3)	5
	10	M	25	Ant Co (2)	3
	11	F	76	Post Cu (3)	6
	12	M	69	Post Cu (2)	3
	13	M	49	TLIF (1)	3
Traumatic instability	14	F	67	LN (2), Post Cu (2)	5
	15	F	57	Ant Co (2)	4
	16	F	60	LN (1), Post Cu (1)	3
	17	F	47	LN (1), Post Cu (1)	3
Mean			61.4		3.7

Ant Co=Anterior corpectomy and interbody fusion, LN=laminectomy and foraminotomy, Post Co=Posterior curettage and interbody fusion

Table 1: Patients' data.

top locking nut is inserted to fix the rod to the screw starting from the caudal screw and working proximally in sequential fashion. Once all the nuts are in place, the extender is unseated and detached from the screw. Compression or distraction can be applied to the extenders as desired, to gain further correction. The average PPF level was 3.7 (range: 3-6).

Outcome parameters

A retrospective review of clinical, radiological, and surgical data was conducted.

The severity of leg or back pain were graded using the visual analog scale (VAS, score range 0–10, with 0 reflecting no pain), and functional outcomes were measured using the Oswestry Disability Index (ODI) scores. Patient's satisfactions were recorded using Odom's criteria during follow-up period.

For radiological evaluation, we examined the dynamic X-rays, Magnetic Resonance Imaging (MRI), and Computed Tomography (CT) prior to surgery, and also, the dynamic X-rays and CT consecutively during follow-up period.

The accuracy of screw position was analyzed by immediate postoperative CT. In CT scan, screw perforation of any aspects of cortex was checked, and when all parts that constitute the screw were located in pedicle and vertebral cortex, it was considered as screw accurately inserted.

To evaluate sagittal alignment, total lumbar lordotic angle (TLA) was measured on lateral radiograph in neutral position, and adjacent segmental angle (ASA) was measured on flexion-extension view (Figure 2). We defined adjacent segmental degeneration (ASD) on the standing lateral film as sagittal translation of the adjacent vertebral body above fused level greater than 3 mm and/or ASA greater than 10° [5]. TLA and ASA were checked at the preoperative period, 1 month after operation, 6 months after operation, and the last follow-up.

The bony fusion rate of interbody fusion and screw failure such as fracture or loosening were evaluated by dynamic X-rays and CT during follow-up period. The degree of bone fusion was based on the classification of Brantigan and Steffee [6] (Table 2), and we regarded

Grade 4 or 5 as a state of bone fusion. The screw loosening was confirmed when we observed more than 1 mm thick radiolucent zone (halo sign) around screw on plain radiographs. Also, we have identified the development of the late postoperative complications such as instability and instrument failure.

Surgical outcomes were evaluated by checking operation time, Estimated Blood Loss (EBL), duration of postoperative bed rest and length of hospital stay. The occurrence of perioperative morbidities such as neurologic deterioration, Cerebrospinal Fluid (CSF) leakage, wound infection, pneumonia, heart problem, urinary difficulty, epidural hematoma, and deep vein thrombosis were checked. Also, we tracked the frequency of reoperation.

Statistical methods

For statistical analysis, paired samples t test was conducted using SPSS software (version 17.0, SPSS Inc, Chicago, IL, USA). A probability value of less than 0.05 was considered significant.

Results


Clinical outcomes

The VAS score at the 1 month after surgery 6.7 (range: 5-9) was significantly lower than the preoperative score, 9.3 (range: 9-10). The mean VAS score decreased at each follow-up evaluation and was significantly lower at the last follow-up (4.1 (range: 2-5)) compared with the preoperative score (Figure 3).

The mean ODI score also improved from 71.2 (range: 67-81) preoperatively to 38.0 (range: 29-61) at the last follow-up (Figure 4). Both VAS and ODI score improved after the surgery and the improvement maintained during the follow-up period with statistical significance ($p < 0.05$).

According to Odom's criteria, the results were excellent in 6 patients (35.3%), good in 7 patients (41.2%), and fair in 4 patients (23.5%) at the 6-month follow-up, and excellent in 7 patients (41.2%), good in 8 patients (47.0%), and fair in 2 patients (11.8%) at the last follow-up. Therefore, the clinical success rate according to Odom's criteria was 88.2% (Figure 5).

Upper



Lower

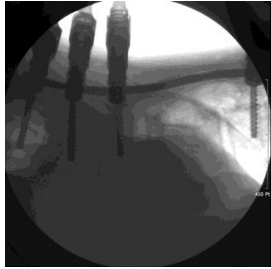

Figure 1: Photograph of Percutaneous Pedicle Screw Fixation (PPF) surgery. Intraoperative photograph of PPF with extenders in place (upper) and intraoperative lateral fluoroscopic image of multilevel PPF with rod being passed through system (lower)

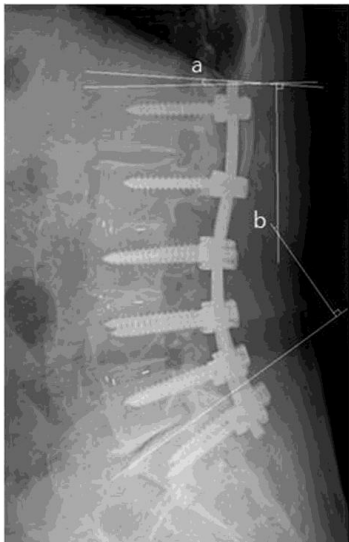


Figure 2: The sagittal angle measurement by Cobb's angle method on plain X-ray. The Adjacent Segmental Angle (ASA) was measured as total sum of intervertebral angles between flexion and extension lateral radiographs (a). To measure it, line along the end plate of adjacent vertebra body and line along the end plate of the most superior or inferior fused vertebra body were drawn. The Total Lumbar Lordotic Angle (TLA) was defined as the angle subtended by the superior end plate line of L1 and the superior end plate line of S1 (b)

Radiological outcomes

In all the patients, by CT scan immediately after surgery, the cases of screw malposition were 6 (4.1%) out of 146 screws. However, there was no occurrence of neurological deficit or vascular complications, and also no need of screw correction.

The mean TLA increased from 34.7° before surgery to 38.0° at the 1 month after surgery, however, decreased to 35.9° at the last follow-up. The mean ASA was 5.7° at pre-operation and 7.0° at the last follow-up. The mean ASA of the caudal adjacent segment was 5.6° at pre-operation and 5.3° at the last follow-up. There was no statistical significance in the changes of the TLA and ASA. Only 2 patients (11.8%) showed cranial ASD, and all of them were asymptomatic.

During follow-up period, there were bony fusions in 15 patients out of 17 patients who underwent interbody fusion, and thus fusion

rate was 88.2%. On the other hand, there were screw loosening in 2 patients, but there was no pull-out or fracture of screw. Among 2 patients of screw loosening, 1 patient showed progressive lumbar kyphotic change without aggravation of symptom, and 1 patient showed instrument related infection and underwent removal of screw at 1 year after surgery.

Surgical outcomes

The mean operation time was 5.9 hours (range: 5.0-9.5), EBL was 550 ml (range: 300-1500) with need of average 1.2 packs (range: 0-4) of transfusion, and duration of bed rest was 2.0 days (range: 1-4). The mean length of hospital stay was 26.4 days (range: 8-59), which was longer period than expected, maybe due to long-term antibiotic therapy for infectious patients. Except for 6 infectious patients, mean length of hospital stay was 13.6 days (range: 8-22).

Grade 1	Obvious radiographic pseudarthrosis
Grade 2	Probable radiographic pseudarthrosis
Grade 3	Radiographic status uncertain
Grade 4	Probable radiographic fusion
Grade 5	Radiographic fusion

Table 2: Description of fusion result by Brantigan and Steffee [6].

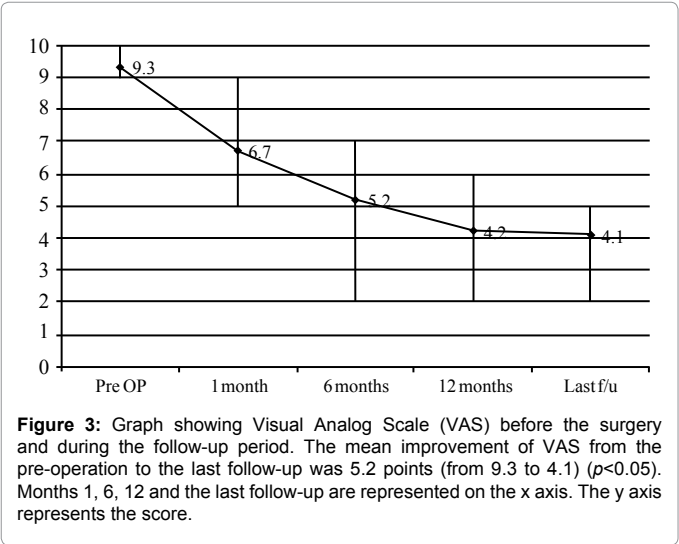


Figure 3: Graph showing Visual Analog Scale (VAS) before the surgery and during the follow-up period. The mean improvement of VAS from the pre-operation to the last follow-up was 5.2 points (from 9.3 to 4.1) ($p<0.05$). Months 1, 6, 12 and the last follow-up are represented on the x axis. The y axis represents the score.

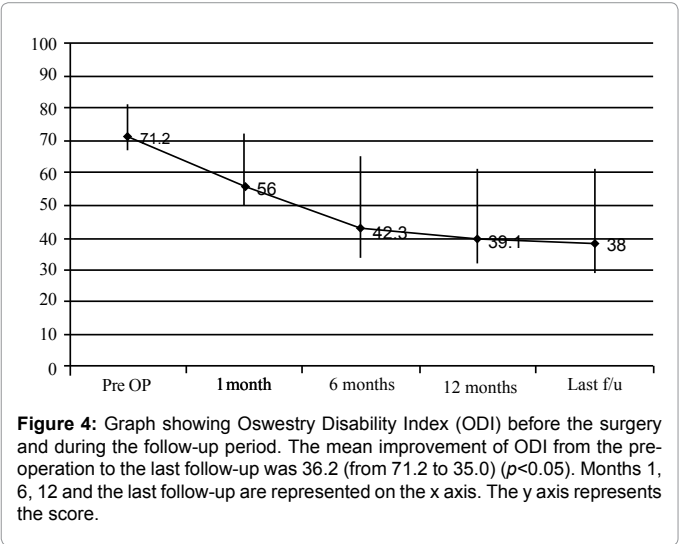


Figure 4: Graph showing Oswestry Disability Index (ODI) before the surgery and during the follow-up period. The mean improvement of ODI from the pre-operation to the last follow-up was 36.2 (from 71.2 to 35.0) ($p<0.05$). Months 1, 6, 12 and the last follow-up are represented on the x axis. The y axis represents the score.

Fortunately, there was no major perioperative morbidity except for a single case of reoperation for resolving hemoperitoneum in patient who underwent anterior corpectomy and fusion.

Case illustration

The following case descriptions provide representative examples.

A 76-year-old woman presented with low back pain and paraparesis since 3 months ago. Preoperative lumbar enhanced MRI demonstrated tuberculous spondylitis at T12, L1 with severe cord compression and bone destruction. Therefore, posterior curettage and interbody fusion at T12-L1 and PPF at T10, 11, L2, 3, 4 were done. Postoperative lumbar CT showed adequate position of inserted screws. Lateral radiograph, at the last follow-up, showed fused segments with stability of spinal curvature (Figure 6).

A 84-year-old man presented with low back pain and neurogenic intermittent claudication since several years ago. Preoperative lumbar MRI demonstrated multilevel spinal stenosis and spondylolisthesis with instability. Therefore, the TLIF at L2-3, L3-4, L4-5, foraminotomy at L5-S1, and PPF at L1, 2, 3, 4, 5, S1 were done. Postoperative lumbar

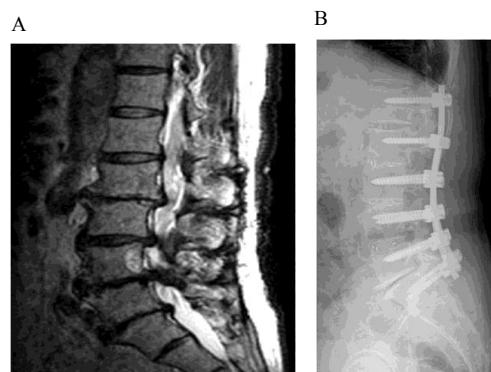


Figure 7: Degenerative multilevel spinal stenosis with instability.

A: Preoperative lumbar magnetic resonance imaging (MRI)
B: Lateral radiograph at the last follow-up

CT showed adequate position of inserted screws. Lateral radiograph, at the last follow-up, showed fused segments with stability of lumbar spinal curvature (Figure 7).

Discussion

The pedicle screw fixation has been used as a universal spinal fusion surgery method for many spinal disorders. Standard open technique for pedicle screw fixation, however, has been associated with several disadvantages. During the open technique, extensive tissue dissection and longtime retraction are inevitable to expose entry points of screw and to provide orientation of lateral to medial for optimal screw trajectory. The excessive retraction of muscle can cause ischemic damage and permanent pathological changes of the muscle [2,7-9]. Already, some authors reported that the degree of damage of muscles and back pain after surgery were proportionate to the size and time of retraction during surgery [10,11]. In addition, extensive dissection of paraspinal muscle can cause excessive blood loss and necrosis of tissue, which can be said to increase the need for transfusion and the chance of postoperative infection [12]. Such problems cause longer bed rest duration, lengthy hospital stay, and significant cost [13]. Moreover, some authors have suggested that the open technique can cause ASD due to extensive dissection of paraspinal muscle or iatrogenic injury of facet joint [5,14].

As these problems become important matter, recently, minimally invasive PPF was introduced and developed. PPF uses small muscle splitting approach to allow placement of hardware under fluoroscopic guidance. This technique permits accurate hardware placement while avoiding adverse effects of open technique. Based on this concept, many authors have reported about advantages of single- or two-level PPF such as shorter operative time, less paraspinal muscle damage, less need for postoperative oral analgesics, and lower blood loss than open technique [15,16]. For multilevel PPF, the longer the length of rod is more difficult to insert, and adjusting alignment of pedicle is difficult. However, recently, with introduction of new instruments, multilevel PPF method that can do a wide range of spinal fusion was developed. Multilevel PPF has usually been carried out for degenerative scoliosis patients [17], but it is still not widely carried out yet, and so the clinical result of the operation method are not known well.

The results of the author's present study demonstrated favorable clinical and radiological outcomes. In the current study, with regard to patient's symptom and satisfaction, improvement of clinical outcomes

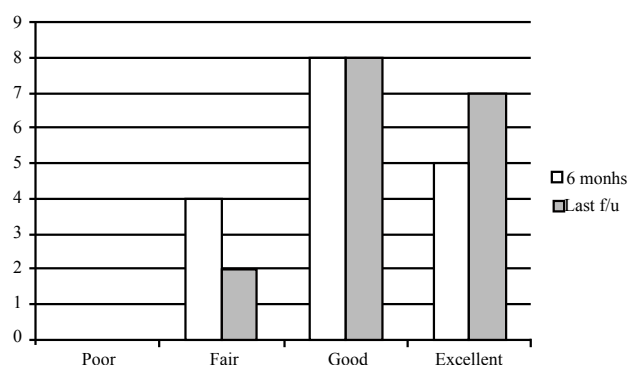


Figure 5: The number of patients according to Odom's criteria at the 6 months after surgery and at the last follow-up. The y axis represents the number of patients.

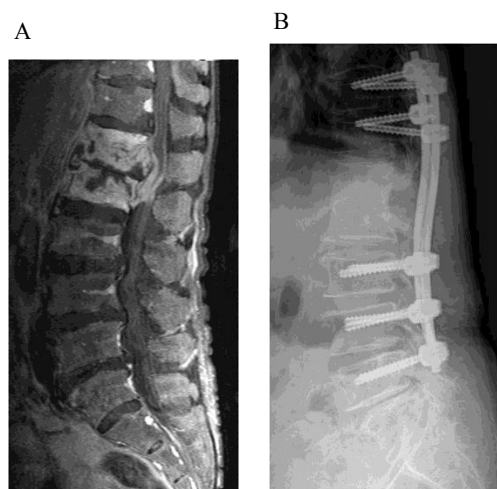


Figure 6: Tuberculous spondylitis.

A: Preoperative lumbar enhanced magnetic resonance imaging (MRI)
B: Lateral radiograph at the last follow-up

such as VAS and ODI were significant. Also, radiological outcomes including rate of screw malposition (4.1%), fusion rate (88.2%), occurrence of ASD (11.8%), and occurrence of screw loosening (11.8%), were satisfactory. Although it is difficult to compare our results with the other studies because there are many factors affecting outcomes, such as the patient's medical condition, surgeon's experience, surgical indication, surgical method, and outcome assessment criteria, the outcomes in the present study are comparable to other reports [18,19].

Multilevel lumbar fusion surgery is needed for multilevel decompression and spinal stability. However, in some special cases, the choice of multilevel fusion is cautious. For example, elderly patients may be at increased risk of surgical morbidities such as pneumonia, cardiovascular event, or wound infection. Also, the patients with medical comorbidities such as cardiovascular disease, renal disease, and diabetes may represent a significant challenge for surgery. The open technique for multilevel fusion, which has the disadvantage of increased operative time and blood loss, may not be tolerated in these elderly patients with poor preoperative general conditions. However, multilevel PPF can be tolerable in even these patients. Compared to the literature [20,21], based on surgical outcomes of current study, we can demonstrate multilevel PPF to be technically feasible, to be accomplished within tolerable operative times, to be associated with less blood loss than the open technique, and to be associated with short hospital stays. Moreover, there was no surgical complication except for a single case of reoperation due to hemoperitoneum.

Despite all the above, limitations of multilevel PPF have been described, including steep learning curves and theoretically increased radiation exposure [22]. Also, in rare cases, the inserted instrument comes to be positioned close to skin, which can cause serious skin stimulating symptom, and so instrument removal is needed [23].

With development of various instruments of multilevel PPF, it is possible to insert contoured long rod as required for the spinal curvature, and to correct malalignment by compression or distraction. However, the indication is more limited than open technique. In cases of the significant malalignment of pedicle before surgery due to severe spondylolisthesis (Grade II or more), severe scoliosis, or rotational deformity, it is difficult to carry out reduction of spinal curvature with percutaneous method. Also, since this surgery is carried out under C-arm fluoroscope, the pedicle should be within the range of anatomical structure that can be predicted under fluoroscope by the performing physician. For example, in cases of excessive degeneration and formation of osteophyte, it is hard to find pedicle under fluoroscope, and so accurate test is necessary and attention should be paid before surgery. Moreover, as the shape of rod which is inserted percutaneously is limited in lordotic or mild kyphotic curved form, it is difficult to apply for severe kyphotic deformity. So, as mentioned above, patients with excessive spondylolisthesis or severe spinal deformity were excluded from this multilevel PPF.

There are some limitations to the present study that should be dealt with. This study was retrospective and had a small patient group with too short follow-up period. Furthermore, the study population is heterogeneous with varying indications for spinal fixation, and there is no comparison with open techniques. Additional study is required to compare the multilevel PPF to the open technique in cases of identical operative indications.

Conclusions

Using newer posterior percutaneous instruments, it is possible to achieve multilevel PPF for various lumbar spinal diseases, with

favorable clinical, radiological, and surgical outcomes compared with the open technique. It remains to be seen whether long-term outcomes are also favorable. Also, the preoperative pedicle alignment is an important factor in multilevel PPF.

References

1. Foley KT, Gupta SK (2002) Percutaneous pedicle screw fixation of the lumbar spine: preliminary clinical results. *J Neurosurg* 97: 7-12.
2. Kim JS, Choi WG, Lee SH (2010) Minimally invasive anterior lumbar interbody fusion followed by percutaneous pedicle screw fixation for isthmic spondylolisthesis: minimum 5-year follow-up. *Spine J* 10: 404-409.
3. Lee JH, Lee SG, Park CW, Kim WK (2010) Clinical outcome of two-level percutaneous pedicle screw fixation in lumbar degenerative disease: A preliminary report. *Kor J Spine* 7: 137-142.
4. Ringel F, Stoffel M, Stürer C, Meyer B (2006) Minimally invasive transmuscular pedicle screw fixation of the thoracic and lumbar spine. *Neurosurgery* 59: ONS361-366.
5. Schlegel JD, Smith JA, Schleusener RL (1996) Lumbar motion segment pathology adjacent to thoracolumbar, lumbar, and lumbosacral fusions. *Spine (Phila Pa 1976)* 21: 970-981.
6. Brantigan JW, Steffee AD (1993) A carbon fiber implant to aid interbody lumbar fusion: Two-year clinical results in the first 26 patients. *Spine* 18: 2106-2107.
7. Kang JS, Lee YK, Cho J, Moon CT, Chang SK (2004) Changes of muscle related enzymes after posterior approaches to the lumbar spine. *J Korean Neurosurg Soc* 35: 23-28.
8. Kawaguchi Y, Matsui H, Tsuji H (1994) Back muscle injury after posterior lumbar spine surgery. Part 2: Histologic and histochemical analyses in humans. *Spine (Phila Pa 1976)* 19: 2598-2602.
9. Styf JR, Willén J (1998) The effects of external compression by three different retractors on pressure in the erector spine muscles during and after posterior lumbar spine surgery in humans. *Spine (Phila Pa 1976)* 23: 354-358.
10. Gejo R, Matsui H, Kawaguchi Y, Ishihara H, Tsuji H (1999) Serial changes in trunk muscle performance after posterior lumbar surgery. *Spine (Phila Pa 1976)* 24: 1023-1028.
11. Rantanen J, Hurme M, Falck B, Alaranta H, Nykivist F, et al. (1993) The lumbar multifidus muscle five years after surgery for a lumbar intervertebral disc herniation. *Spine (Phila Pa 1976)* 18: 568-574.
12. Sihvonen T, Hernö A, Paljärvi L, Airaksinen O, Partanen J, et al. (1993) Local denervation atrophy of paraspinal muscles in postoperative failed back syndrome. *Spine (Phila Pa 1976)* 18: 575-581.
13. Thomsen K, Christensen FB, Eiskjaer SP, Hansen ES, Fruensgaard S, et al. (1997) 1997 Volvo Award winner in clinical studies. The effect of pedicle screw instrumentation on functional outcome and fusion rates in posterolateral lumbar spinal fusion: a prospective, randomized clinical study. *Spine (Phila Pa 1976)* 22: 2813-2822.
14. Lim TK, Lee SG, Park CW, Kim WK (2010) Comparative analysis of clinical outcomes and adjacent level angle change on single-level lumbar 4-5 fusion using percutaneous screw fixation and open screw fixation. *Korean J Spine* 7: 228-233.
15. Kim DY, Lee SH, Chung SK, Lee HY (2005) Comparison of multifidus muscle atrophy and trunk extension muscle strength: percutaneous versus open pedicle screw fixation. *Spine (Phila Pa 1976)* 30: 123-129.
16. Lee SH, Choi WG, Lim SR, Kang HY, Shin SW (2004) Minimally invasive anterior lumbar interbody fusion followed by percutaneous pedicle screw fixation for isthmic spondylolisthesis. *Spine J* 4: 644-649.
17. Anand N, Baron EM, Thaiyananthan G, Khalsa K, Goldstein TB (2008) Minimally invasive multilevel percutaneous correction and fusion for adult lumbar degenerative scoliosis: a technique and feasibility study. *J Spinal Disord Tech* 21: 459-467.
18. Kim NH, Lee JW (1999) Anterior interbody fusion versus posterolateral fusion with transpedicular fixation for isthmic spondylolisthesis in adults. A comparison of clinical results. *Spine (Phila Pa 1976)* 24: 812-816.
19. Zhao J, Hou T, Wang X, Ma S (2003) Posterior lumbar interbody fusion using one diagonal fusion cage with transpedicular screw/rod fixation. *Eur Spine J* 12: 173-177.

-
20. Hu SS (2004) Blood loss in adult spinal surgery. Eur Spine J 13: S3-S5.
 21. Möller H, Hedlund R (2000) Instrumented and noninstrumented posterolateral fusion in adult spondylolisthesis--a prospective randomized study: part 2. Spine (Phila Pa 1976) 25: 1716-1721.
 22. Eck JC, Hodges S, Humphreys SC (2007) Minimally invasive lumbar spinal fusion. J Am Acad Orthop Surg 15: 321-329.
 23. Lowery GL, Kulkarni SS (2000) Posterior percutaneous spine instrumentation. Eur Spine J 9: S126-S130.