

Migrating Intraventricular Gunshot Pellet: A Case Report

Ignatius N Esene^{1,2*}, Ahmed M Ashour¹, Omar Youssef¹, Mohamed Wael Samir Mahmoud¹ and Alaa Fahkr¹

¹Department of Neurosurgery, Ain Shams University, Cairo, Egypt

²Gamma Knife Center, Nasser Institute, Cairo, Egypt

Abstract

Intraventricular migration of a pellet is an unusual complication of a gunshot missile injury to the brain. Herein, we report the case of a 58 year-old man with a gunshot pellet that migrated by its mere tiny size, weight and cerebrospinal fluid pulsation from the lateral ventricle through the third ventricle, aqueduct of Sylvius to the fourth ventricle without accompanying clinical nor radiological manifestations.

The pellet was thus managed expectantly. The patient was closely followed-up for short term complications such as hydrocephalus, infection and in the long run will be monitored for syrinx. He remained symptom-free and serial CT brain till 6 months after injury revealed the pellet still lodged in the fourth ventricle.

Instances of similar phenomena reported in the literature are also reviewed and discussed.

Keywords: Brain trauma; Gunshot; Head injury; Intraventricular; Missile injury; Migrating; Pellet

Introduction

Since 1916 when the phenomenon of missile migration was first described [1], sporadic cases of spontaneous migration of intracranial extraventricular missiles have been reported [2-6]. However, only very few rare cases of intraventricular migration have been reported [7-12]. Herein, we present a rare case of an intraventricular pellet (size: less than 10 ± 5 mm) that migrated through an intact ventricular drainage system of the brain essentially an anterograde embolization of a pellet from the anterior horn of the lateral ventricle to the fourth ventricle without accompanying clinical manifestations.

Case Presentation

Fifty-eight year-old right-handed male patient with no rewarding past medical or surgical history was brought to our emergency room 12 hours after a cranial gunshot injury. The circumstances of the incident were unclear and nature of weapon/ammunition used unknown but most probably a home-made gun in a context of civilian injury. On examination, the patient had a Glasgow coma score of 15 and oriented in time, place and person. Multiple left fronto-temporo-parietal cutaneous entry wounds of variable sizes were identified with facial oedema but no exit wounds. There wasn't any neurologic deficit. An initial CT Scan of the head revealed a left frontal horn intraventricular gunshot pellet. There weren't any associated intracerebral nor intraventricular lesions. The patient was managed expectantly with close clinical and radiological follow-up and remained symptom-free. The patient was discharged after 10 days and CT brain on discharge revealed a sudden relocation of the pellet into the fourth ventricle, but no hydrocephalus nor other clinical symptoms. One, three and six months CT brains showed the pellet in same location (4th ventricle) and the patient didn't develop any new clinical manifestations (Figure 1).

Discussion

Foreign body migration in the cranial axis is a rare but established clinical entity. Retained intracranial metallic fragments may alter their position over a period of time. These fragments may be intraventricular, intraparenchymal or subarachnoid in position [13]. Post-injury hematomas, infections, seizures, and Cerebro Spinal Fluid Fistulas (CSFFs) are counted among the early complications, whereas foreign bodies migrating intracranially, seizures, infections, and

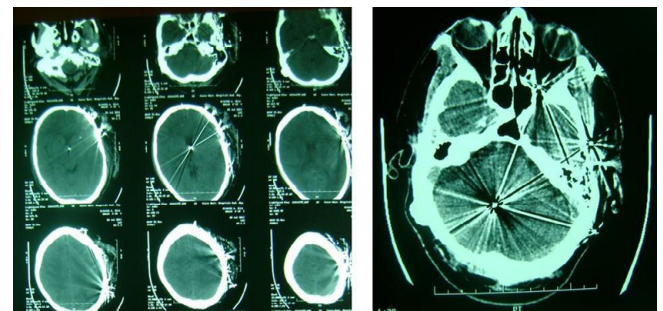


Figure 1: Intraventricular pellet migration from lateral to fourth ventricle.

posttraumatic hydrocephalus represent late complications [13]. Since 1916 when Wilvandre and Norgan first described the phenomenon of missile migration [1], a number of cases of the extraventricular moving bullet syndrome in the cerebrum have been reported in the literature [2,4-6,14]. Nonetheless, only very few rare cases of migration involving the cerebrospinal fluid system have been reported [7-12].

In 1942, Campbell et al., reported the movement of an intraventricular bullet within the left lateral ventricle of a 29-year-old woman [10]. In 1967, Lang reported a patient in whom an intraventricular bullet had migrated to the level of the aqueduct of Sylvius (length 15-18 mm and diameter 1-2 mm), producing acute hydrocephalus [9]. Young Jr, et al. [8] in 1983 described the spontaneous migration of an intracranial bullet into the cervical canal over a course of approximately 4 years with the patient remaining asymptomatic [8]. Castillo-Rangel et al. in 2010 presented a case of

*Corresponding author: Ignatius Esene, Department of Neurosurgery, Ain Shams University, Cairo, Egypt, Tel: +201099755210; E-mail: ignatiusesene@yahoo.co.uk

Received June 27, 2015; Accepted July 16, 2015; Published July 23, 2015

Citation: Esene IN, Ashour AM, Youssef O, Mahmoud MWS, Fahkr A, et al. (2015) Migrating Intraventricular Gunshot Pellet: A Case Report. J Clin Case Rep S3: 003. doi:10.4172/2165-7920.S3-003

Copyright: © 2015 Esene IN, et al. This is an open-access article distributed under the terms of the Creative Commons Attribution License, which permits unrestricted use, distribution, and reproduction in any medium, provided the original author and source are credited.

Author, Year	Missile type	Initial Location	Final Location	Complications	Treatment	Duration to Migration	Outcome
Castillo-Rangel et al. [7]	Bullet	Cranial (Interhemispheric fissure)*	thoracic canal at T4 level*	Myelopathy	posterior laminectomy and dorsal midline myelotomy	27 years	Total Recovery after 30 days post-operation
Lang [9]	Bullet	Lateral ventricle	aqueduct of Sylvius	Acute hydrocephalus	Surgery for hydrocephalus	Within 24 Hours	Good outcome
Campbell [10]	Bullet	Lateral ventricle	Loose bullet in the lateral ventricle	None	Conservative	12 days	Good
Sternbergh, Jr et al. [11]	Bullet	Cerebellar hemisphere then 4th ventricle	Cisterna magna	Slight ventricular dilation	Surgical removal via suboccipital craniectomy	5 weeks	Progressive recovery in neurological status 8 weeks after surgery
Lough et al. [12]	Pellet	Cranial (right lateral Ventricle)	central spinal canal (T6)	Patient comatosed	Non-operable	48 Hours	Died within 48 h

*Trajectory of bullet: In this case the bullet followed the cerebrospinal fluid circulation, through the ventricles, then apparently the bullet continues parallel to the four ventricle, sylvian aqueduct and ependimal canal.

Table 1: Summary of reported cases on intraventricular migrating bullet/pellet.

bullet migration from the intracranial compartment to the thoracic canal over period of 27 years [7] and Erik Lough et al. recently (in 2012) reported a case of ballistic fragment migration through the intact ventricular drainage system from the right ventricle through the cerebrospinal fluid to the midthoracic intraspinal canal [12] (Table 1).

Other authors have described the migration of bullets from the brain parenchyma into the ventricular system viz.: Sternbergh et al. [11] reported the bullet migration from the parietal region into the fourth ventricles, while Buwembo described four cases of transventricular migration removed surgically [14].

Our case migrated from the lateral to the fourth ventricle within 10 days, a duration intermediary to the aforementioned case reports. Intraventricular fragments may shift their position because of the space around them, by gravity, brain pulsations and the sink effect of the ventricles of the brain and have an implication in the pathogenesis of hydrocephalus, ventriculitis, and hypothalamic dysfunction amongst others. A free fragment lying in the lateral ventricle can be manoeuvred into the occipital horn from where it can be removed under direct vision [13]. Subarachnoid migration can occur occur via the CSF subarachnoid pathways [13].

Migration is less often seen in intraparenchymal fragments since they are surrounded by tissue or gliosis [13]. However the phenomenon of spontaneous migration through brain tissue has been ascribed to three factors: the action of gravity, because of the disparity between the specific gravities of metal and brain (heavier bullets tend to shift their position); local softening of brain tissue surrounding the fragment and abscess formation in the surrounding structure and the pulsations of the brain [15]. Delayed migration indicates softening of the surrounding brain while arrest of migration can occur due to oedema, gliosis or due to fragment getting embedded in a developing brain abscess [13].

A migrating missile can result in worsening of the neurological deficit due to passage of the bullet via eloquent brain areas, obstructive hydrocephalus and ventriculitis for intraventricular bullets. Our case migrated via the supratentorial ventricular system atraumatically and asymptotically into the fourth ventricle. In cases of bullets or symptomatic missile fragments, removal might be warranted and can be effected by X-ray or CT guidance [14]. Our patient was managed conservatively since he was asymptomatic. He received parenteral triple antibiotics (Ampicillin/sulbactam + second generation cephalosporins + metronidazole) during first week, Paracetamol as analgesia, anticonvulsant (phenytoin) and ranitidine. He is on regular follow up and is symptom free as of date.

Conclusion

Intraventricular migration of a gunshot missile is rare especially with pellets migrating atraumatically and asymptotically from the lateral to fourth ventricles. With such cases, management could be expectant and the patient monitored for complications such as hydrocephalus, infection and in the long run syringx.

References

- Wilvandre G, Morgan JD (1916) Movements of the foreign bodies in the brain. Arch Radiol Electrother 21: 22-27.
- Rengachary SS, Carey M, Templer J (1992) The sinking bullet. Neurosurgery 30: 291-294.
- Furlow LT, Bender MB, Teuber HL(1947) Movable foreign body within the cerebral ventricle; a case report. J Neurosurg 4: 380-386.
- Rammo RA, DeFazio MV, Bullock MR (2012) Management of migrating intracranial bullets: lessons learned from surviving an AK-47 bullet through the lateral brainstem. World Neurosurg 77: 591, e19-24.
- Rapp LG, Arce CA, McKenzie R, Darmody WR, Guyot DR (1999) Incidence of intracranial bullet fragment migration. Neurol Res 21: 475-480.
- Zafonte RD, Watanabe T, Mann NR (1998) Moving bullet syndrome: a complication of penetrating head injury. Arch Phys Med Rehabil 79: 1469-1472.
- Castillo-Rangel C, Reyes-Soto G, Mendizabal-Guerra R (2010) Cranio-thoracic bullet migration over a period of 27 years: case report. Neurocirugia (Astur) 21: 326-329.
- Young WF Jr., Katz MR, Rosenwasser RH (1993) Spontaneous migration of an intracranial bullet into the cervical canal. South Med J 86: 557-559.
- Lang EK (1969) Acute hydrocephalus secondary to occlusion of the aqueduct by a bullet. J La State Med Soc 121: 167-168.
- Campbell E, Howard WP, Weary WB (1942) Gunshot Wounds Of The Brain. report Of Two Unusual Complications; Bifrontal Pneumocephalus And Loose Bullet In The Lateral Ventricle. Arch Surg 44: 789-798.
- Sternbergh WC, Jr., Watts C, Clark K (1971) Bullet within the fourth ventricle. Case report. J Neurosurg 34: 805-807.
- Lough EG, Glover B, Brown AL (2013) An unusual case of air rifle pellet migration from the brain to the thoracic spine. Am Surg 79: E33-E34.
- Bhatoe HS (2005) Craniocerebral Missile Injuries: Operative Management. In: Ravi Ramamurthi, K Sridhar, MC Vasudevan, editors. Textbooks of Operative Neurosurgery. BI Publications Pvt Ltd; pp. 247-255 New Delhi.
- Buwembo JD, De Villiers Jacques C (1995) Migrating Retained Intracranial Missiles. AJNS14.
- Liebeskind AL, Anderson RD, Schechter MM (1973) Spontaneous movement of an intracranial missile. Neuroradiology 5: 129-132.