

Maxillary Ameloblastoma-Diagnostic Challenge for the Surgeons: A Case Report

Handa JK*, Ashwin DP and Handa A

Department of Oral and Maxillofacial surgery, Vokkaligara Sangha Dental College and Hospital, KR Road, VV Puram, Bangalore, India

Abstract

Ameloblastoma previously known as adamantinoma is a histologically benign, locally invasive odontogenic neoplasm of epithelial origin which is derived from the odontogenic ectoderm. It was first described by Cusack in 1827. However, the first detailed description of this lesion was given by Falkson in 1879. The term 'ameloblastoma' was coined by Churchill in 1933. Ameloblastoma is an odontogenic tumor representing 1% of all tumors of the jaw, with 80% to 85% occurring in the mandible and 15% to 20% in the maxilla. In the maxilla, 47% of ameloblastomas have been reported in the molar region, 15% in the maxillary antrum and floor of the nose, 9% in the premolar region, 9% in the canine and incisor region and 2% in the palate. Maxillary ameloblastoma is most commonly associated with painless swelling, loosening of teeth, nasal airway obstruction, malocclusion, periodontal diseases and ulceration. The proximity of maxilla to the orbit, skull base and intracranial contents contributes to the high morbidity and mortality rate associated with them.

Keywords: Ameloblastoma; Odontogenic; Radiographs; Proximity

Introduction

Treatment of ameloblastoma is primarily surgical. Management of maxillary ameloblastoma often is an enigma to the maxillofacial surgeons who carefully must choose between two widely available treatment strategies: conservative and radical. Conservative management involves curettage and enucleation whereas radical involves marginal, segmental and composite resections [1-5]. Recurrence rate as high as 15% to 25% after radical treatment and 75% to 90% after conservative treatment has been reported [6-9]. Nevertheless, lower recurrence rate of 10% to 25% has been reported in unicystic ameloblastoma cases treated with enucleation followed by use of Carnoy's solution [10].

Case Presentation

A 22-year-old male reported to the Department of Oral and Maxillofacial Surgery, Vokkaligara Sangha Dental College and Hospital, Bangalore with a chief complaint of painless swelling of the right premaxilla of 3 months duration.

Extraoral examination revealed mild swelling over the right maxillary region with obliteration of the corresponding nasolabial fold. Intraorally, a diffuse, firm, nontender swelling was noted extending from the central incisor to the distal aspect of the first premolar involving both the labial and palatal cortical plate. (Figure 1) The mucosa over the swelling appeared normal with no secondary changes. Mobility of both the right central incisor and lateral incisor was noted.

A set of plain radiographs including intraoral periapical radiograph (IOPAR), occlusal radiograph and orthopantomography (OPG) were taken. Cone beam computerized tomography (CBCT) was further

advised to study the lesion. The radiographs revealed a large, well circumscribed, unilocular radiolucency involving the right maxillary central incisor, lateral incisor, canine and first premolar. The radiolucency was triangular with the base towards the apices of diverging roots of right central incisor and lateral incisor (Figure 2).

Aspiration using 18-gauge needle was performed from the palatal aspect of lesion in right canine and first premolar. It yielded 0.3 ml of blood tinged fluid which was sent for the histopathological analysis. An incisional biopsy was carried out under local anesthesia from the palatal aspect of the lesion after the basic blood investigations revealed normal value.

Differential diagnosis

The clinical and radiographic radiolucency prompted a presumptive diagnosis of an odontogenic cyst or neoplasm. Adenomatoid odontogenic tumor (AOT) is the most common benign odontogenic tumor of the anterior maxilla, presenting in the second decade of life. It is usually located between the apices of the lateral incisor and premolar, intimately associated with an impacted canine. The occurrence of this lesion in a young male adult further supported this diagnosis.

Unicystic ameloblastoma merits inclusion in the differential diagnosis, since this lesion typically presents as a circumscribed radiolucency surrounding the crown of an unerupted tooth. It is often seen in younger patients, with about 50% of such tumors diagnosed during the second decade of life. However, it is more commonly seen in the posterior mandible.

Desmoplastic ameloblastoma has a predilection for occurrence in the maxilla. This leads to its inclusion in the diagnosis. It usually

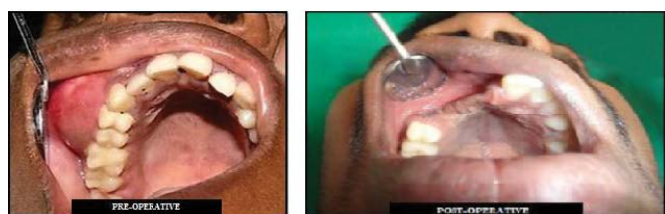

Figure 1: Intraoral presentation pre-op and post-op.

*Corresponding author: Handa JK, Department of Oral and Maxillofacial surgery, Vokkaligara Sangha Dental College and Hospital, KR Road, VV Puram, Bangalore, India, Tel: +91-9916960702; E-mail: dr.jasleen.88@gmail.com

Received May 21, 2018; Accepted May 23, 2018; Published May 28, 2018

Citation: Handa JK, Ashwin DP, Handa A (2018) Maxillary Ameloblastoma-Diagnostic Challenge for the Surgeons: A Case Report. J Clin Case Rep 8: 1118. doi: 10.4172/2165-7920.10001118

Copyright: © 2018 Handa JK, et al. This is an open-access article distributed under the terms of the Creative Commons Attribution License, which permits unrestricted use, distribution, and reproduction in any medium, provided the original author and source are credited.

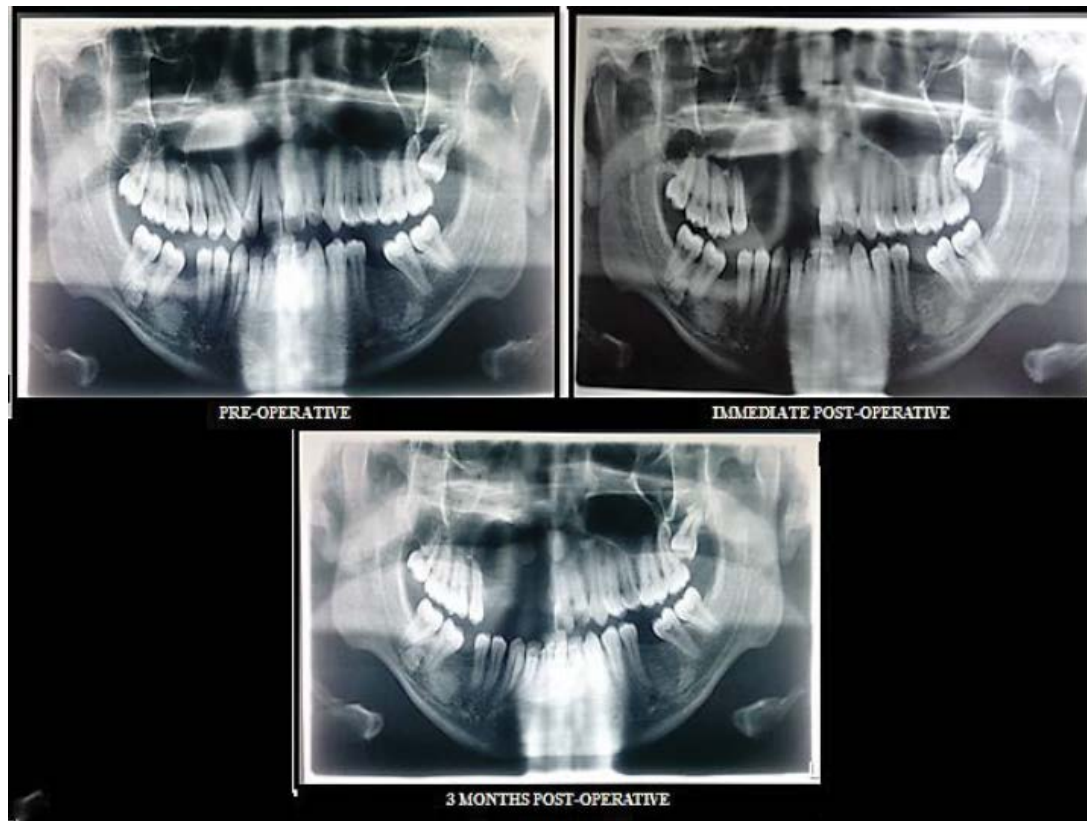


Figure 2: Radiographic presentation.

appears as a radiolucent lesion on the radiograph with nearly half of the desmoplastic variants showing a mixture of radiopacity/radiolucency on radiographs. Conventional ameloblastoma was also considered, since this is the most common odontogenic tumor occurring in relation to an impacted tooth. However, it is more commonly noted in the posterior mandible and is typically seen in an older age group. However, this usually presents with a mixed radiolucent-radiopaque pattern resembling a fibro-osseous lesion.

Central giant cell granuloma also merits inclusion in the differential diagnosis. It occurs most frequently in the anterior mandible in female patients under 30 years of age. However, maxillary lesions often arise anterior to the cuspids, and smaller lesions can present as a solitary cyst like unilocular radiolucency. The somewhat unlikely possibilities of calcifying odontogenic cyst and calcifying epithelial odontogenic tumor were also considered. The absence of any radiographic evidence of internal calcification argued somewhat against this diagnosis.

Finally, passing mention can be given to a central vascular process. However, a nonproductive aspiration virtually eliminates this entity. The possibility of this lesion representing a malignant tumor was considered highly unlikely because of the painless, slow-growing expansible nature of the lesion, the presence of well-circumscribed radiographic margins, and an absence of cortical destruction.

Diagnosis

Histopathological examination under eosin and hematoxylin stained section showed a cystic lining consisting of flat to cuboidal cells with hyperchromatic nucleus resembling ameloblasts. Fibrous wall was

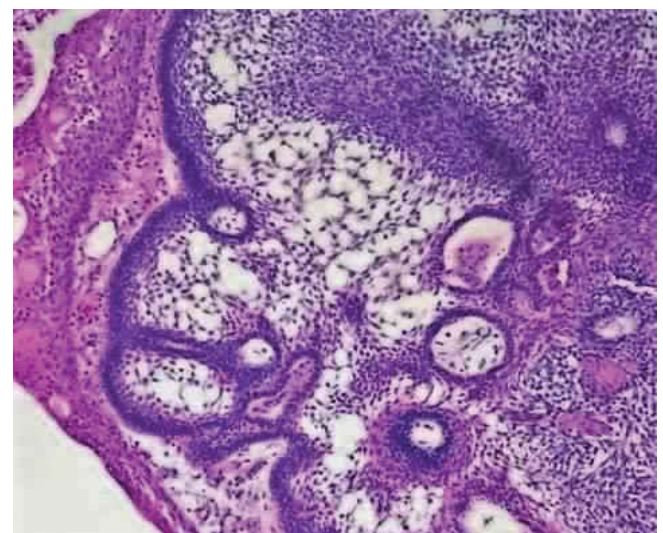


Figure 3: Histologic presentation.

dense with scattered odontogenic follicles consisting of tall columnar cells with hyperchromatic nucleus and reverse polarity. Loosely arranged stellate reticulum like cells were confined to the central part. After correlation of clinical, radiographic and cytopathological features, a definitive diagnosis of Type III (mural) uni-cystic ameloblastoma was given (Figure 3).

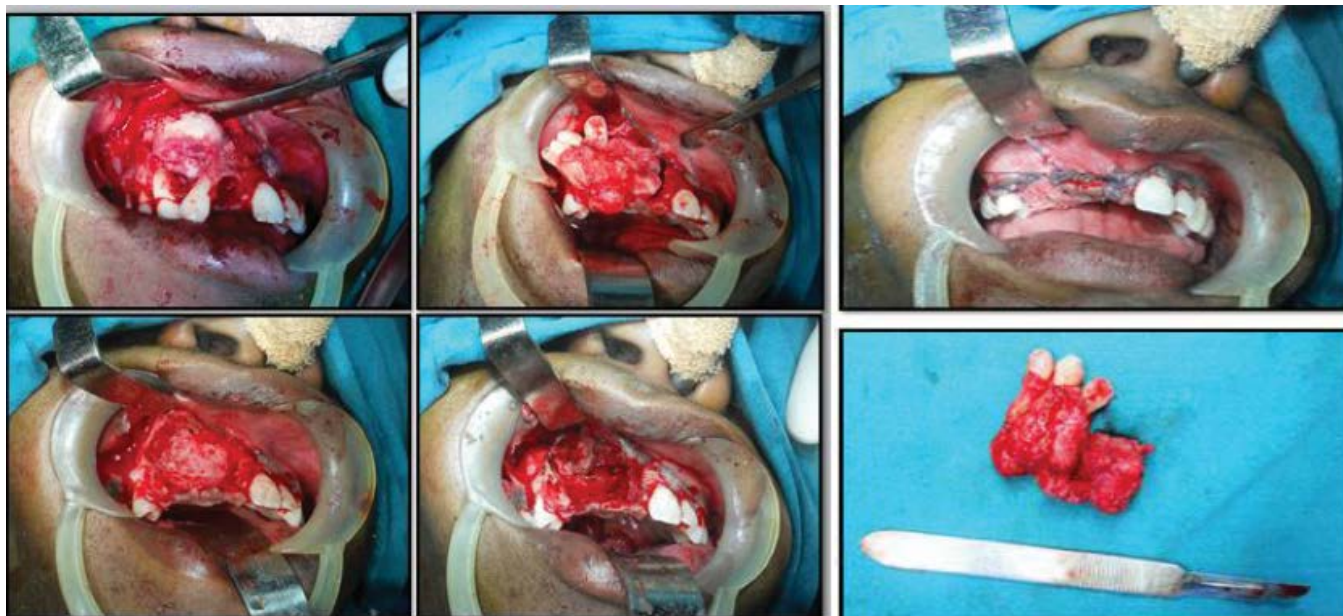


Figure 4: Intraoperative presentation.

Management

Following the diagnosis of unicystic ameloblastoma, surgical treatment plan of enucleation and chemical cauterization was formulated. Under general anesthesia, an intraoral crevicular incision was placed from distal surface of right second premolar extending till the distal surface of left central incisor. The full thickness mucoperiosteal flap was reflected to expose the entire dimension of the lesion. Enucleation of the lesion was done in toto along with the right lateral incisor, canine and first premolar. Carnoy's solution was used as a chemical cauterizing agent for 3 minutes following which the surgical area was debrided thoroughly with saline and betadine. The surgical area was then packed with Bismuth Iodoform Paraffin Paste (BIPPS) gauze dressing. Primary closure was done using 3-0 vicryl suture material (Figure 4).

The gross specimen consisted of a thick white soft tissue. The histopathological examination confirmed the diagnosis. The gauze dressing was removed 48 hours after the procedure and reapproximating of the mucoperiosteal flap done under local anesthesia.

A regular follow up is being carried out at 3 months duration. The patient is presently undergoing fixed orthodontic treatment for the alignment of the dentition, following which fixed prosthodontic therapy has been planned for the restoration of form, function and esthetics of the postsurgical defect.

Discussion and Conclusion

Ameloblastoma is an aggressive benign tumor of epithelial origin that may arise from the enamel organ, remnants of dental lamina, the lining of an odontogenic cyst, or perhaps from the basal epithelial cells of the oral mucosa [11]. The clinicopathological features are benign with a slow growing pattern, but locally invasive. The clinical behavior may be regarded as lying somewhere between benign and malignant, and its high recurrence is a problem for clinicians [12].

Ameloblastoma is classified clinically into 3 main types: unicystic, solid or multicystic and peripheral or extraosseous type. Solid or multicystic variants of ameloblastoma are locally aggressive and recur if inadequately excised. However, unicystic ameloblastoma is identified as a prognostically distinct entity with less aggressive behavior [13]. Histopathological analysis catalogs it into six subtypes: follicular, acanthomatous, granular cell, basal cell, desmoplastic, and plexiform types. The classification system has a direct bearing on the pathologic behavior of these variants and aids the surgeon in formulating a treatment plan. Hong et al., demonstrated that the histopathology of an ameloblastoma is significantly associated with a recurrence. Follicular, granular cell and acanthomatous types have a relatively high likelihood of recurrence in contrast to the desmoplastic, plexiform and unicystic types which have a low potential for recurrence [14].

Robinson and Martinez described unicystic ameloblastoma as a distinct clinicopathological entity with unicystic radiographic appearance and histologic findings, associated with an unerupted tooth with preponderance in the mandible of younger patients associated with lower recurrence rate. Ackermann et al., in 1988 reclassified it into three types with prognostic and therapeutic implications (Table 1).

Maxillary ameloblastoma is most frequently associated with slow, painless swelling and consequent alveolar expansion of the involved part of the jaw. This is attributed to the lack of a thick cortical plate, the plentiful cancellous bone and the proximity of the maxilla to the nasal cavity, nasopharynx, paranasal sinuses, orbits and skull base. Nasal obstruction localized facial enlargement and swelling of the cheek, gingiva or hard palate are other clinical features associated with maxillary ameloblastoma. These typical features were observed in our case.

Radiographically, it appears as an osteolytic lesion and does not produce mineralized components except in rare cases. When the maxillary sinus and surrounding structures are involved, opacification of the sinus and expansion of its walls with or without bone destruction

Type	Features
Type I	Unilocular cystic lesions lined by epithelium exhibiting features of ameloblastoma
Type II	Epithelial nodules comprised of follicular or plexiform epithelium arise from the cystic lining and project into the cyst lumen
Type III	Presence of invasive islands of ameloblastomatous epithelium in the connective tissue wall of the cyst which may or may not be connected to the cyst lining

Table 1: Uni-cystic ameloblastoma classification according to Ackermann.

makes it impossible to distinguish ameloblastoma from other malignant and invasive tumors like craniopharyngiomas [15,16].

There are broadly two types of treatment strategies mentioned: conservative and radical procedures. Conservative surgical procedures consist of marsupialization, enucleation, and curettage combined with adjunctive procedures like cryotherapy, chemical cauterization using Carnoy's solution and electrocautery. These procedures are widely in the management of unicystic ameloblastomas, especially in children and young patients.

Recurrence rate after conservative treatment of conventional ameloblastoma ranges from 50% to 90%. However, a lower recurrence rate has been reported in unicystic ameloblastoma between 10% and 25% [17,18]. Carnoy's solution was initially used as a sclerosing agent for treatment of cysts and fistulae and is currently used as a fixative. Its use in relation to unicystic ameloblastoma was initially suggested by Stoellity & Bronkhorst in 1987 [19]. Rosenstein et al., and Lee et al., reported success rates with recurrence rates of 10% by using it as an adjunct to enucleation and curettage [10-18]. Enucleation with chemical cauterization using Carnoy's solution was the method of choice in our case as an aggressive primary surgery would eliminate the risk of recurrence, nevertheless is associated with invertible morbidity. Follow up is crucial in these cases owing to micro invasive nature of the lesion penetrating the vital structures in the vicinity. A strict follow up of 3 months is being carried out for the case to prevent any untoward complication. However, long term follows up and prospective study with a larger population will determine the success rate of the treatment plan.

References

1. Scaccia FJ, Strauss M, Arnold J, Agarwal A (1991) Maxillary ameloblastoma: Case report. *Am J Otolaryngol* 12: 20-25.
2. Bjorklund A, Elnor A, Snorraddottir M (1979) Clinical records, ameloblastoma of the maxilla, report of three cases. *J Laryngol Otol* 93: 1105-1113.
3. Tanaka T, Ohkubo T, Fujitsuka H, Tatematsu N, Oka N, et al. (1991) Malignant

mixed tumor (malignant ameloblastoma and fibrosarcoma) of the maxilla. *Arch Pathol Lab Med* 115: 84-87.

4. Regezi JA, Scicibber JJ (1989) *Oral pathology, clinical-pathological considerations*. Philadelphia: WB Saunders Co 116: 337-348.
5. Sehdev MK, Huvos AG, Strong EW (1974) Ameloblastoma of maxilla and mandible. *Cancer* 33: 324.
6. Shatkin S, Hoffmeister FS (1965) Ameloblastoma: A rational approach to therapy. *Oral Surg Oral Med Oral Pathol* 20: 421-435.
7. Mehlich DR, Dahlin DC, Masson JK (1972) Ameloblastoma: A clinicopathologic report. *J Oral Surg* 30: 9-22.
8. Tsaknis PJ, Nelson JF (1980) The maxillary ameloblastoma: An analysis of 24 cases. *J Oral Surg* 38: 336-342.
9. Vedtofte P, Hjorting-Hansen E, Jensen BN, Roed-Peterson B (1978) Conservative surgical treatment of mandibular ameloblastomas. *Int J Oral Surg* 7: 156-161.
10. Rosenstein T, Pogrel MA, Smith RA, Regezi JA (2001) Cystic ameloblastoma-behaviour and treatment of 21 cases. *J Oral Maxillofac Surg* 59: 131-116.
11. Ghandhi D, Ayoub AF, Anthony M, MacDonald G, Brocklebank LM, et al. (2006) Ameloblastoma: A surgeon's dilemma. *J Oral Maxillofac Surg* 64: 1010-1014.
12. Hong J, Yun PY, Chung IH, Myoung H, Suh JD, et al. (2007) Long term follow up on recurrence of 305 ameloblastoma cases. *Int J Oral Maxillofac Surg* 36: 283-288.
13. Robinson L, Martinez MG (1977) Unicystic ameloblastoma: A prognostically distinct entity. *Cancer* 40: 2278-2285.
14. Hong J, Yun PY, Chung IH, Myoung H, Suh JD, et al. (2007) Long term follow up on recurrence of 305 ameloblastoma cases. *Int J Oral Maxillofac Surg* 36: 283-288.
15. Waldron CA, El-Mofty SK (1987) A histopathologic study of 116 ameloblastomas with special reference to the desmoplastic variant. *Oral Surg Oral Med Oral Pathol* 63: 441-451.
16. Siar CH, Ng KH (1991) View from beneath: Pathology in focus. Calcifying and keratinizing ameloblastoma of the maxilla. *Laryngol Otol* 105: 971-972.
17. Robinson L, Martinez MG (1977) Unicystic ameloblastoma: A prognostic distinct entity. *Cancer* 40: 2278-2285.
18. Lee PK, Samman N, Ng IO (2004) Unicystic ameloblastoma- use of Carnoy's solution after enucleation. *Int J Oral Maxillofac Surg* 33: 263-267.
19. Stoeltinga PJW, Bronkhorst FB (1988) The incidence, multiple presentation and recurrence of aggressive cysts of the jaws. *J Craniomaxillofac Surg* 16: 184-195.