

## Massive Pulmonary Embolism Revealing a Giant Adrenocortical Carcinoma

Cécile Caze<sup>1</sup>, Julien Puchoux<sup>2</sup>, Isabelle Orain<sup>3</sup> and Denis Angoulvant<sup>1\*</sup>

<sup>1</sup>Department of Cardiology, Tours University Hospital and François Rabelais University, Tours, F37000, France

<sup>2</sup>Department of Radiology, Tours University Hospital, Tours, France

<sup>3</sup>Department of Pathology, Tours University Hospital, Tours, France

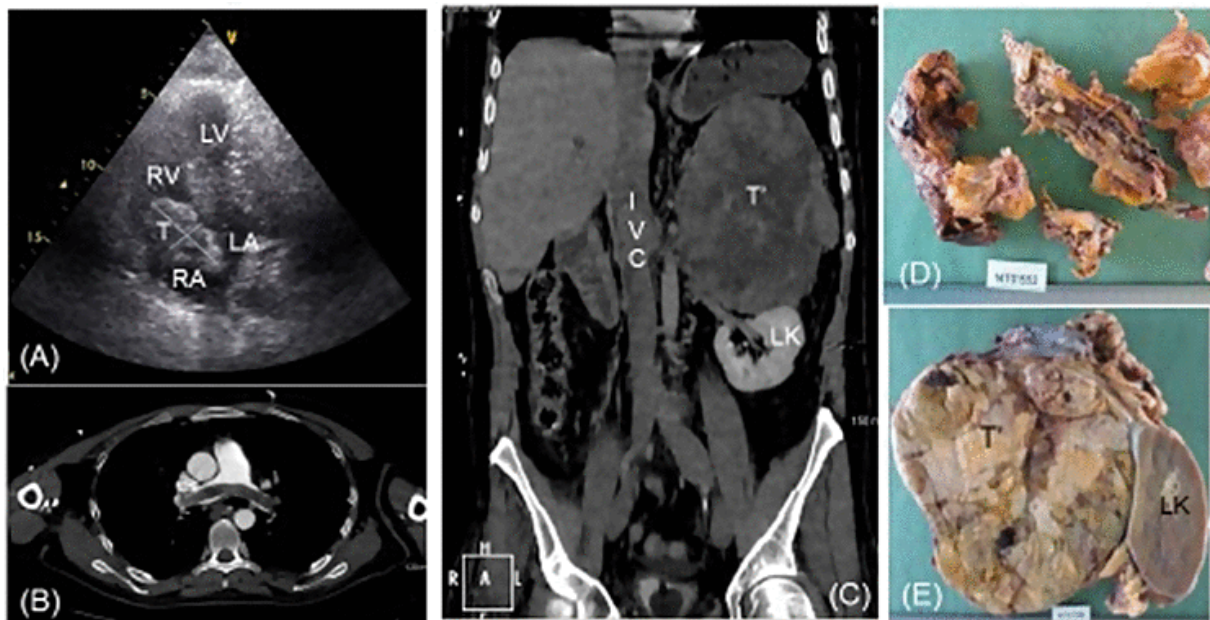
\*Corresponding author: Denis Angoulvant M.D., Ph.D., Department of Cardiology, Tours University Hospital and François Rabelais University, Tours, F37000, France, Tel: +33-2-47-47-46-52; E-mail: [d.angoulvant@chu-tours.fr](mailto:d.angoulvant@chu-tours.fr)

Received date: Jun 04, 2014, Accepted date: Jun 06, 2014, Published date: Jun 10, 2014

Copyright: © 2014 Angoulvant D, et al. This is an open-access article distributed under the terms of the Creative Commons Attribution License, which permits unrestricted use, distribution, and reproduction in any medium, provided the original author and source are credited.

Citation: Caze C, Puchoux J, Orain I, Angoulvant D (2014) Massive Pulmonary Embolism Revealing a Giant Adrenocortical Carcinoma. J Pulm Respir Med 4: i001. doi: 10.4172/2161-105X.1000i001

### Clinical Image



Massive Pulmonary Embolism Revealing a Giant Adrenocortical Carcinoma

A 39 year old male with no previous medical history or treatment, was admitted to the emergency room for acute dyspnea, abdominal pain, and right heart failure without clinical sign of deep venous thrombosis. ECG displayed sinus tachycardia. Blood tests showed acute renal failure (serum creatinine = 247  $\mu\text{mol/L}$ ), hepatic cytolysis and uncompensated non-respiratory acidosis ( $\text{pH}=7.18$ ,  $\text{PO}_2=113$  mmHg,  $\text{PCO}_2=14$  mmHg,  $\text{HCO}_3^-=4.9$  mmol/L).

Transthoracic Echocardiography (TTE) showed a right atrial tumor (5.5X3.5 cm) prolapsing through the tricuspid in the right ventricle during diastole (Panel A: TTE with cardiac Tumor (T) in the Right Atrium (RA) and Right Ventricle (RV)). Contrast-enhanced thoracic Computed Tomographic scan (CT) revealed a bilateral tumoral pulmonary embolism (Panel B: CT bilateral pulmonary thrombus). Abdominal CT showed a voluminous suprarenal tumor with left kidney compression and thrombus extension in the Inferior Vena Cava (IVC) (24X4 cm) (Panel C: CT Adrenocortical carcinoma (T), compressing the left kidney (LK) with thrombus extension in the IVC). Emergency surgery was performed (embolectomy, left adrenalectomy and left nephrectomy) and the pathologist diagnosed tumoral thrombus complicating a left adrenocortical carcinoma (1.8 Kg weight, 17X14X11 cm) (Panel D, E: pathological samples (D) thrombus and (E) adrenocortical carcinoma (T) next to left kidney (LK)).