

## Malignant Peripheral Nerve Sheath Tumor in Parotid Gland-A Rare and Challenging Case

Priyadarshini Biswa, Asaranti Kar\*, Lity Mohanty, Kaumudee Pattnaik and Manjushree Nayak

Department of Pathology, S.C.B. Medical College, Cuttack, Odisha, India

### Abstract

Malignant peripheral nerve sheath tumor accounts for about <10% of all sarcomas. Its incidence in the parotid gland is even rarer. A 49 year old male presented to the ENT department with a history of parotid swelling of 1 year duration. The mass was rapidly increasing in size. We received the gross specimen comprising of irregular, grayish white tissue in pieces, as the tumor was infiltrating into the deeper structures and couldn't be removed *in toto*. Histomorphological features showed a spindle cell neoplasm with features of malignant peripheral nerve sheath tumour. Neural origin of the tumor was confirmed by immunohistochemistry. The patient is now receiving radiotherapy and doing well. We report this case due to its rarity and also to aware the surgical pathologists to keep this as a differential diagnosis in the evaluation of all spindle cell parotid tumours.

**Keywords:** Malignant Peripheral Nerve Sheath Tumor (MPNST); Parotid glands

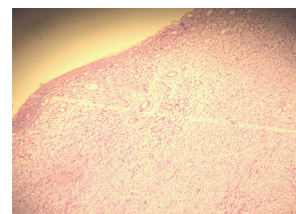
### Introduction

Mesenchymal tumors comprise about 2% to 5% of all salivary gland tumors with over 95% involving the major salivary gland. Malignant tumours are outnumbered by benign mesenchymal tumours. Ratio of benign to malignant lesions is 2.4:1 to 18:1 [1,2]. Occurrence of Malignant Peripheral Nerve Sheath Tumor (MPNST) in parotid gland is very rare, about 0.01%, with about 142 cases being reported within the last 13 years since 1990 [3]. MPNSTs are recognized due to its characteristic histomorphological features like alternate hypo and hypercellular areas with "marble pattern" of asymmetrical spindle cells, and presence of wavy or buckled nuclei. On immunohistochemistry, S-100 protein was found to be focally positive. The tumor cells were negative for Calponin, Cytokeratin, p63, and epithelial membrane antigen which helped us to rule out other spindle cell tumors of parotid like myoepithelial carcinoma, spindle cell carcinoma, malignant melanoma and fibrosarcoma. Though MPNST is a rare tumor in the parotid gland, awareness of their unique histomorphological features and immune histochemistry is important for diagnosing it and differentiating it from other spindle cell tumors. MPNST has a very aggressive course and a very bad prognosis with a survival rate of 5 to 7 years.

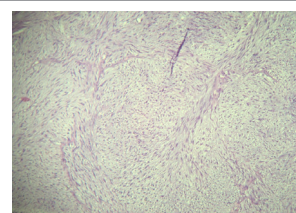
### Case History

A 49 years old male presented to the Ear, Nose and Throat Department with a history of parotid gland swelling of 1 year duration which was rapidly increasing in size. The swelling was painless. On examination, a mass of 4 cm in diameter was found partially adherent to deeper structures. There was no facial paralysis. Chest X-ray and examination of other parts of body did not reveal any abnormality. Neither the patient nor anyone in his family had history of neurofibromatosis. The patient was planned for parotidectomy. During the operation the mass was seen to be infiltrating into the deeper structures. The mass couldn't be removed in total with the capsule. Palliative surgery was done and the tumor was removed in pieces. Gross specimen received was multiple bits of irregular grayish white nodular tissue together measuring 4×4×3 cm. Cut section was solid and grayish white. Multiple sections were given from different areas. Haematoxylin and Eosin stained sections showed presence of few parotid ducts and acinar structures pushed to one side. The entire tumor tissue consisted of spindle shaped cells with large nuclei and scant eosinophilic cytoplasm (Figure 1). The tumor cells were arranged

in long sweeping fascicles containing hyperchromatic and pleomorphic nuclei. Few foci showed alternate hypo and hypercellular areas with a marble like pattern (Figure 2). Few foci showed nuclear buckling and coma shaped nuclei. High mitotic activity (2-3/10 HPF) was observed. So a provisional diagnosis of spindle cell sarcoma of parotid gland was made with a possibility of malignant peripheral nerve sheath tumour. However we took the help of immunohistochemistry to rule out other spindle cell tumors like spindle cell variant of myoepithelial carcinoma, spindle cell carcinoma, malignant melanoma (amelanotic and spindle



**Figure 1:** H and E sections showing spindle cells with parotid ducts pushed to one side. 10x magnification.



**Figure 2:** H and E sections showing 'marble-like pattern' of spindle cells. 10x magnification.

**\*Corresponding author:** Dr. Asaranti Kar, Associate Professor, Department of Pathology, SCB Medical College, Qrs. No-JO-1, S.C.B. Medical College Camous, Cuttack -753007, Odisha, India, Tel: 09437170442; E-mail: [asarantikar@yahoo.co.in](mailto:asarantikar@yahoo.co.in)

**Received** September 28, 2012; **Accepted** January 11, 2013; **Published** January 14, 2013

**Citation:** Biswa P, Kar A, Mohanty L, Pattnaik K, Nayak M (2013) Malignant Peripheral Nerve Sheath Tumor in Parotid Gland-A Rare and Challenging Case. J Clin Case Rep 3:243. doi:10.4172/2165-7920.1000243

**Copyright:** © 2012 Biswa P, et al. This is an open-access article distributed under the terms of the Creative Commons Attribution License, which permits unrestricted use, distribution, and reproduction in any medium, provided the original author and source are credited.

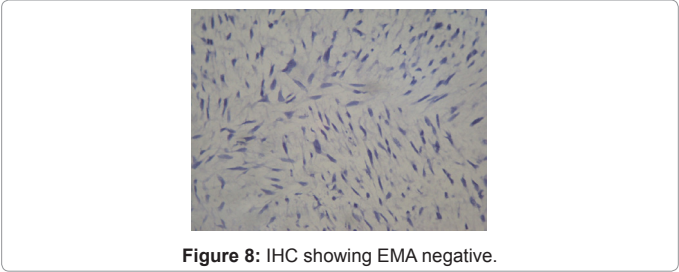
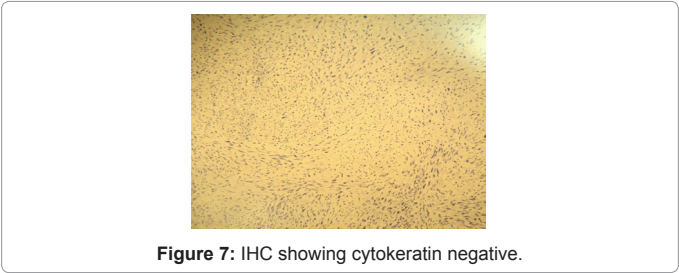
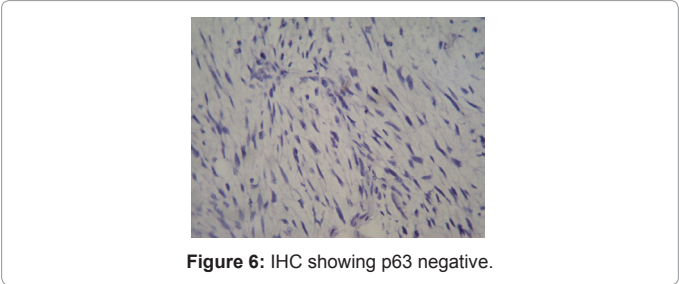
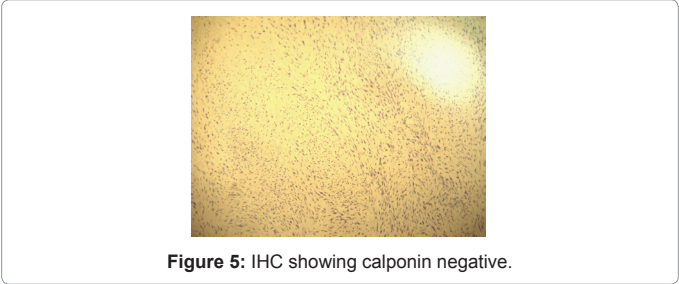
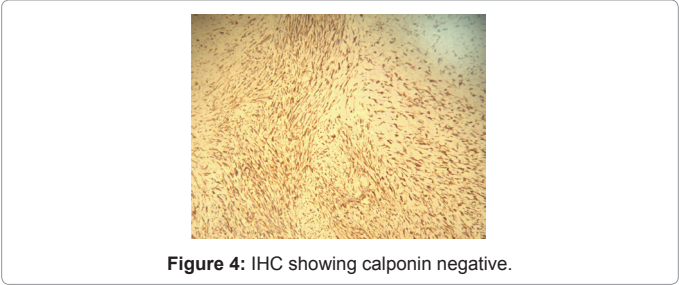
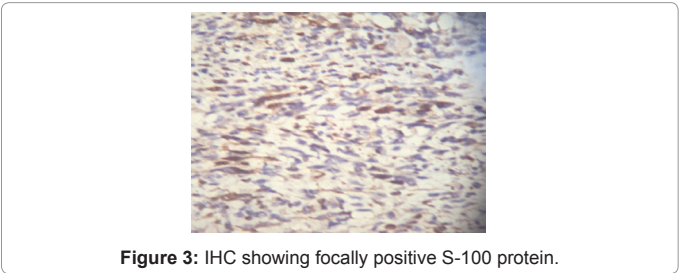
cell type) and fibrosarcoma. Immunohistochemistry is showed in table 1. So, based upon immunohistochemical findings, we excluded spindle cell variant of myoepithelial carcinoma and a diagnosis of malignant peripheral nerve sheath tumor (low grade) of parotid gland was done

**Discussion**

Malignant peripheral nerve sheath tumour accounts for approximately 5% to 10% of all soft tissue sarcomas; about one-fourth to one-half occurring in the setting of neurofibromatosis. MPNST arises from peripheral nerve cells or shows differentiation towards nerve cells. Malignant peripheral nerve sheath tumour is typically a disease of adult life as most tumors occur in 20-50 years of age. They arise primarily in the extremities or trunk [4]. Ours was a 47 years old male presenting with a parotid mass. The lesion presents as an rapidly enlarging mass, usually noted several months before diagnosis and may present with pain. A sarcoma is assumed to be malignant peripheral nerve sheath tumour if one of the 3 criteria are met with (1) tumor arises from a peripheral nerve (2) tumor arises from a pre-existing benign nerve sheath tumor, neurofibroma (3) tumor displaying constellation of histological features of Schwann cell differentiation [5]. In our case the third criteria was met with i.e. the histomorphological features showing alternate hypo and hypercellular areas and buckling of nuclei along with pleomorphism and mitosis. This histomorphology was seen throughout the tumour tissue. Areas of necrosis were also noted. The classical histomorphology of MPNST provided us the clue to rule put other spindle cell neoplasms. However, diagnosis was less straightforward without the help of immunohistochemistry. Immunohistochemistry is mandatory to rule out the possibility that some of these spindle cell or pleomorphic malignant neoplasms are not spindle cell carcinomas, myoepithelial carcinomas or malignant melanomas [6]. Here, immunohistochemistry profile helped us to rule out different spindle cell lesions. The focal positivity of S-100 protein and diffuse positivity for vimentin which occurs in 50% to 90% of helped us in diagnosing our case as malignant peripheral nerve sheath tumour (Figures 3 and 4). The diagnosis of myoepithelial carcinoma was not done due to negativity for calponin (Figure 5). The tumour cells were also negative for P63 (Figure 6). Negativity for EMA and cytokeratin ruled out the possibility of sarcomatoid or spindle cell carcinoma (Figures 7 and 8). MPNST may be found in a setting of neurofibromatosis. Especially patients with type 1 neurofibromatosis have a great tendency to develop malignant peripheral nerve sheath tumors [7]. The present case had a short history of parotid mass and no other mass throughout his body. Moreover his family members didn't

S-100 protein	Focally positive	Figure-3
Vimentin	Diffusely positive	Figure-4
Calponin	Negative	Figure-5
P63	Negative	Figure-6
Cytokeratin	Negative	Figure-7
EMA	Negative	Figure-8

**Table 1:** Immunohistochemistry findings.



have any history of neurofibromatosis. This indicates that this case of MPNST in parotid had arisen de novo. Malignant peripheral nerve sheath tumour in parotid gland has an aggressive course with local recurrence in 54% of cases and distant metastasis to lungs and bone in 65% cases and 5 year survival rate of 34% [4]. Surgery is the treatment of choice followed by high dose radiotherapy. Some of the MPNSTs can have epithelioid morphology when these are known as malignant

epithelioid schwannoma. Malignant epithelioid schwannoma is an aggressive variant of malignant peripheral nerve sheath tumour, and unfortunately is related with a high rate of recurrence and poor prognosis [8]. This should be kept in mind and ruled out while examining the histomorphology of any malignant tumour of epithelioid morphology in parotid glands.

#### References

1. Ellis GL, Auclair PL, Gnepp DR (1991) Surgical pathology of the salivary glands. In: LiVolsi Major problems in pathology. Saunders, Philadelphia, PA.
2. Seifert G, Miehke A, Haubrich J (1986) Diseases of the salivary glands. George Thieme, Stuttgart.
3. Imamura S, Suzuki H, Koda E, Usami S, Yoshizawa A (2003) Malignant peripheral nerve sheath tumor of the parotid gland. Ann Otol Rhinol Laryngol 112: 637-643.
4. Canor G, Ozkok G, Guler G, Gul E, Ziya M, et al. (2007) Malignant peripheral nerve sheath tumour presenting as a parotid mass. KBB Forum 6: 76-78.
5. Weis SW, Goldblum JR, Folpe AL (2007) Enzinger and Weiss's Soft Tissue Tumor. (5th edn), Elsevier Health Sciences, Netherland.
6. Brooks JJ (1988) Disorders of soft tissue. In: Sternberg's Diagnostic Surgical Pathology. (5th edn), Stacey E. Mills. Lippincott Williams and Wilkins. 1: 137-222.
7. Başaran B, Orhan KS, Polat B, Mete O, Başerer N (2011) [Malignant peripheral nerve sheath tumor in the parotid gland developed on the basis of neurofibromatosis type 1]. Kulak Burun Bogaz Ihtis Derg 21: 220-224.
8. De Stefano A, Kulamarva G, Citraro L, Borgia L, Croce A (2012) Malignant peripheral nerve sheath tumour (malignant epithelioid Schwannoma) of the parotid gland. Bratisl Lek Listy 113: 628-631.