

## Lymphohemangioma on Hard Palate: Case Report

Laudenice Pereira Lucena<sup>\*</sup>, Paulo Rogério Ferreti Bonan, Antônio de Lisboa Lopes Costa, Laura Priscila Barboza de Carvalho, Victor Yuri Nicolau Ferreira and Tácio Candeia Lyra

Universidade Federal do Rio Grande do Norte, Brazil

<sup>\*</sup>Corresponding author: Laudenice Pereira de Lucena, Universidade Federal do Rio Grande do Norte, Brazil, Tel: 55838882-7842; E-mail: [nicelucena@hotmail.com](mailto:nicelucena@hotmail.com)

Rec date: Apr 19, 2016; Acc date: June 24, 2016; Pub date: June 27, 2016

Copyright: © 2016 Lucena LP, et al. This is an open-access article distributed under the terms of the Creative Commons Attribution License, which permits unrestricted use, distribution, and reproduction in any medium, provided the original author and source are credited.

### Abstract

Lymphangioma is a benign congenital malformation of the lymphatic tissue that occurs predominantly in children and clinically presents as a soft painless swelling, compressible of oral mucosa. Usually affects male individuals and the most common intraoral location is the tongue. Surgical excision is the treatment of choice and the prognosis is good. It is describes a case of lymphangioma in a non-caucasian 82 years old female. Intra-oral examination revealed the presence of reddish papules, with 0.5 cm in diameter, painless, flaccid consistency and smooth surface in the anterior hard palate. Excisional biopsy was performed and the histopathologic diagnosis was lymphangioma. After seven months follow-up, the patient has no recurrence of the lesion.

**Keywords:** Lymphangiomas; Congenital malformations; Hemangiomas; Lymph spaces

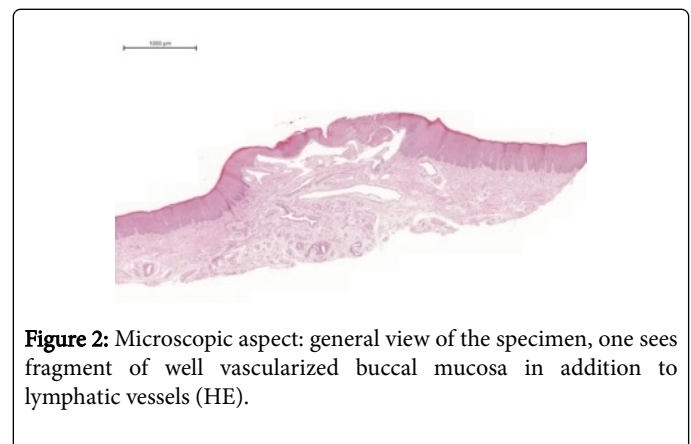
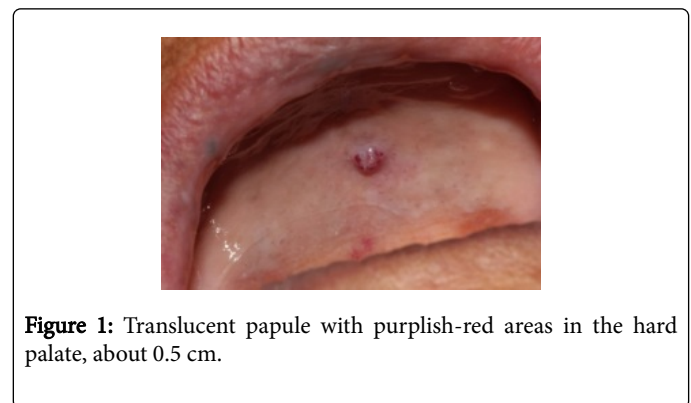
### Introduction

Lymphangiomas are congenital malformations of the lymphatic tissue, 75% located in the head and neck [1-3]. 90% of the cases are found up to 2 years old, being rare in adults [4-6]. They are usually floating soft lesion, and a secondary bleeding into the interior of the lymph spaces may result in a purplish color of these vesicles [7-10]. These lesions could be associated with hemangiomas revealing their hamartomatous condition [3,10]. The prognosis is good [9]. The recurrence has also been reported in some cases [5]. Herein, we presented a unusual case of a lymphohemangioma affecting the hard palate of 82 years old female.

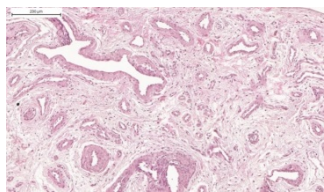
### Case Report

A non caucasian 82 years old female was referred to our Stomatology service by a prosthodontists who noticed a lesion during prosthetic planning consultation. During the anamnesis, she reported diabetes and hypertension and smoking habits since childhood. Extraorally, she did not present any alteration. Intraorally, she presented a reddish painless papule with flabby consistency, smooth and stone-like surface, sizing 0.5 cm of diameter, on hard palate (Figure 1).

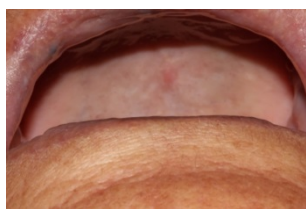
The duration of this lesion was unknown. We raised as differential diagnosis lesions such lymphangioma or lymphohemangioma. Due to small size and absence of malignant characteristics, an excisional biopsy was carried out. During the procedure a light bleeding occurred and we controlled it by compression associated to suture and fibrin sponge. The histopathological examination of the surgical specimen revealed a vascular hamartoma characterized by the presence of large lymphatic vessels mixed with blood vessels on sub-epithelial region. The final diagnosis was lymphohemangioma (Figure 2).



After seven months of the lesion removal, the patient is in good general condition, being evaluated every two months with no complaints and without clinical signs of recurrence of the lesion. Now she is rehabilitated with dentures (Figures 3 and 4).



**Figure 3:** Microscopic aspect: Lymphatic vessels with marked dilatations that often diffusely infiltrate the adjacent soft tissues and demonstrate lymphoid aggregates in their walls (HE)



**Figure 4:** Postoperative clinical aspect: Seven months of the lesion removal, there is no clinical signs of recurrence of the lesion.

## Discussion

Lymphangiomas are usually classified as hamartomas, tumors or congenital lesions of lymphatic origin that have a high predilection for the head and neck. The age group with the highest prevalence is between birth to two years old, being slightly more common in males [7]. In the oral cavity the most common site of involvement is the anterior two thirds of the tongue, followed by the labial mucosa [1]. Unlike what is reported in the literature, our case reports a lesion not common in old female patient in the hard palate.

Despite her status of benign neoplasia, large lesions may cause significant morbidity due to its volume, a critical location or a trend for secondary infections. The lesion in most cases has a good prognosis, since it does not involve important structures for the patient's life [10]. The lymphangioma is a relatively uncommon. In a study by Rocha [8] was evaluated the prevalence of benign oral tumors in the Pathology Department of the Federal University of Rio Grande do Norte for 21 years (1982-2002). From the 336 diagnosed neoplasias, the lymphangiomas represented only 1.5% of the cases.

Clinically, the oral lymphangioma is a painless swelling, soft and with a highly irregular surface, which is described in the literature as "frog eggs" or "tapioca pudding." The injury may have reddish color which can be explained by the presence of bleeding or the association with hemangiomas [5,9]. In the reported case, the clinical features of the lesion have indicated the hypothesis of lymphangioma.

The diagnosis of lymphangioma can be done through clinical examination, due to its peculiar clinical aspect, the histopathological analysis and some imaging methods such as ultrasound and angiography [5]. The differential diagnosis is usually made with lesions such as hemangiomas, lingual thyroid, granular cell tumor and infectious processes [3,6,10].

The histopathological analysis of the oral lymphangioma revealed the presence of dilated vessels coated by a thin layer of endothelial

cells. These elements are diffused by the underlying connective tissue to the epithelium, inside the vessel a protein liquid is observed, and some lymphocytes as well. If there is the presence of red blood cells inside the vessels, it may represent a secondary hemorrhage or an association with a hemangioma [1]. In the reported case, such lesions were observed and have confirmed the clinical hypothesis of lymphohemangioma.

The surgical excision is the chosen treatment for lymphangiomas that affect the oral cavity, in some cases this practice cannot be performed because sometimes the injury can involve vital structures [6]. As an alternative to this treatment, there are some possibilities as the therapy with OK-432, which consists in attenuated and lyophilized *Streptococcus pyogenes* strains. These strains act stimulating the endothelial cells, favoring an obstruction of the lymph vessels and their subsequent fibrosis. Sclerotherapy, radiation therapy, cryotherapy, intralesional injection of corticosteroids and the excision with CO<sub>2</sub> laser have been described by literature [7,10]. In our case, the lesion was not large or had not any vital structures involved, then the excisional biopsy for diagnostic purposes, dismissed further treatment, being considered as resolutive.

## Conclusion

The lymphangioma is a benign lesion, relatively uncommon, which has a great predilection for the head and neck, including the oral cavity. Large lesions may cause significant morbidity due to its volume, critical location or propensity for secondary infections.

The lesion in most cases has a good prognosis, since it does not involve important structures for the life of the patient, and the treatment way must be more conservative for a better life quality of the patient. However, it is important that the Dentist is aware of the injury in order to promote a correct diagnosis, and consequently, a proper treatment for this condition.

## References

1. Catalfamo L, Nava C, Lombardo G, Iudicello V, Siniscalchi EN (2012) Tongue lymphangioma in adult. *J Craniofac Surg* 23(6): 1920-1922.
2. Gupta S, Ahuja P, Rehani U, Singh V (2011) Lymphangioma of cheek region—an unusual presentation. *J Oral Biol Craniofac Res* 1(1): 47-49.
3. Bonet-Coloma C, Minguez-Martínez I, Aloy-Prósper A, Rubio-Serrano M, Peñarrocha-Diago, et al. (2011) Clinical characteristics, treatment, and evolution in 14 cases of pediatric orofacial lymphangioma. *J Oral Maxillofac Surg* 69(6): 96-99.
4. Ganesh C, Sangeetha GS, Narayanan V, Umamaheswari TN (2013) Lymphangioma circumscriptum in an adult: an unusual oral presentation. *J Clin Imag Sci* 3(1): 44.
5. Yoganna SS, Prasad RGR, Sekar B (2014) Oral lymphangioma of the buccal mucosa a rare case report. *J Pharm Bioal Sci* 6(1): S188.
6. Sunil S, Gopakumar D, Sreenivasan BS (2012) Oral lymphangioma – Case reports and review of literature. *Cont Clin Dent* 3(1): 116.
7. Zhou Q, Zheng JW, Mai HM, Luo QF, Fan XD, et al. (2011) Treatment guidelines of lymphatic malformations of the head and neck. *Oral Oncol* 47(12): 1105-1109.
8. Aciole GTDS, Aciole JMDS, Soares LGP, Santos NRS, Santos JND, et al. (2010) Surgical treatment of oral lymphangiomas with CO<sub>2</sub> laser: report of two uncommon cases. *Braz Dent J* 21(4): 365-369.
9. Rocha DAP, Oliveira LMDM, Souza LBD (2006) Neoplasias Benignas da Cavidade oral: estudo epidemiológico de 21 anos (1982 a 2002). *Rev Odontol Univ Cid São Paulo* 18(1): 53-60.

10. Chakravarti A, Bhargava R. ( 2013) Lymphangioma circumsriptum of the tongue in children: Successful treatment using intralesional bleomycin. *Int J Pediatr Otorhinolaryngol* 77(8): 1367-1369.