

# Lyell's Syndrome: Effectiveness of a Diagnostic Management and Early Treatment

Amine Salmi\*

Department of Medical and Surgical Emergencies, University Hospital Center Mustapha, Algiers, Algeria

## Abstract

Lyell's syndrome or toxic epidermal necrolysis is a bullous dermatosis, of etiology, very often medicated. It is an acute necrosis of the epidermis, with a clinical appearance of extensive burns. At this table are associated mucosal damage and, frequently, a multiorgan making poor prognosis. We report in this paper a case of toxic epidermal necrolysis, which illustrates the importance of early treatment in an intensive care unit, whose foundations are based on fluid and electrolyte intake, infection prevention and its treatment with appropriate antibiotics.

**Keywords:** Toxic epidermal necrolysis; Emergency treatment; Prognosis

## Introduction

In 1956 Lyell described the toxic epidermal necrolysis (TEN) about four patients with skin peeling similar to that observed in the burned, evoking epidermal necrolysis toxic origin without assimilating the polymorphe1. Erythema subsequently, it was noted that the same causes could induce both the Stevens-Johnson syndrome (SJS) and TEN and SJS an initial table could grow in TEN. So, SJS and TEN are a very serious illness even variants: toxic epidermal necrolysis (TEN) substantially drug-induced differing only by the extent of cutaneous detachment (<10 per 100 of the total area for SJS. more than 30 p. 100 for TEN. Between 10% to 30% for the transitions the two forms). This is a rare but serious drug eruption, unpredictable occurrence, leads to a destruction of the surface layer of the skin and mucous membranes [1-3].

Many drugs that may be responsible: Allopurinol, sulfonamides, antiepileptic (carbamazepine, phenytoin, phenobarbital), non-steroidal anti-inflammatory derived of the oxicam...) [4-5].

The therapeutic management is essentially symptomatic. It resembles that of severe burned through the stop of the suspect medication, fluid and electrolyte intake of quality and prevention and appropriate treatment of the infection. The objective of this work is to describe the epidemiology, etiology, clinical, therapeutic and evolutionary SL illustrated by the case of a patient hospitalized in intensive care for SL.

The prognosis is severe, evaluated using a specific scale of severity of the disease, the SCORTEN [6]. and nearly 50% of sequelae, particularly eye, in survivors. The aim of our work is to report the clinical manifestations through an observation and, above all, to draw the attention of the clinician to a syndrome where the precocity diagnosis is a very important step allowing the stop of the drug or incriminated drugs (s), associated with symptomatic treatment.

## Case Report

34-year-old woman without surgical or individual medical history admitted in intensive care unit to skin lesions and diffuse erythematous mouth.

The symptoms began 4 days after taking an antibiotic cephalixin like 1000, 3 times 1 tablet per day (beta-lactamines antibiotic of the first-generation cephalosporin), marked by the installation of diffuse erythematous skin lesions, difficulty in breathing and a dry cough.

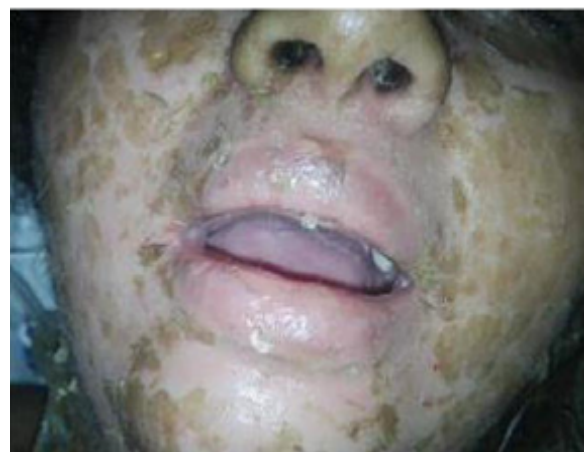
On admission, clinical examination found a conscious patient stable hemodynamically, febrile at 39°C. The skin examination betrayed macular lesions and erythematous maculopapular, of varying sizes,

sitting on the face, back and lower limbs which extended to the soles. The evaluation of the affected skin surface was more than 90%, with a SCORTEN in 2. The examination revealed mucosal erosions of the oral mucosa and ulceration of the tongue. The standard blood test was without defects. A chest radiograph is normal. The treatment, after stopping the offending drug (Cefalexine), contained abundant electrolyte resuscitation to prevent functional renal failure, early parenteral nutrition and enteral, oral care with methylene blue and thromboembolic prophylaxis.

Regarding skin lesions, no specific treatment has been proposed, and was spontaneously favorable evolution after 10 days (Figures 1-5).

## Discussion

Lyell's syndrome is a rare clinical entity. Its impact on the model



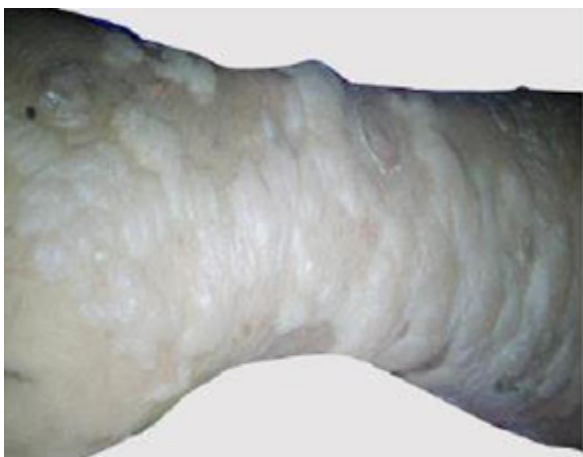**Figure 1:** Erosions of the oral mucosa.

\*Corresponding author: Amine Salmi, Department of Medical and Surgical Emergencies, University Hospital Center Mustapha, Algiers, Tel: 0663503399; E-mail: [salmi\\_amine@yahoo.fr](mailto:salmi_amine@yahoo.fr)

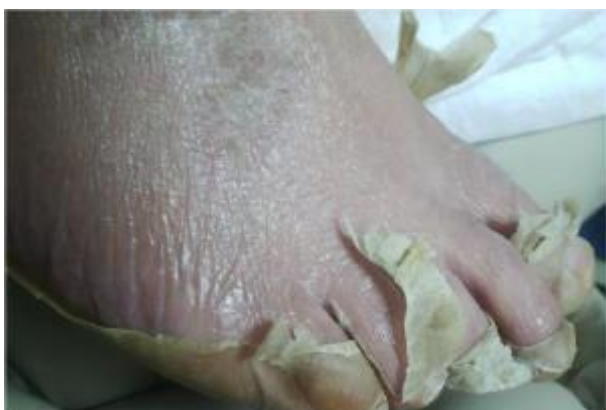**Received** October 27, 2017; **Accepted** February 24, 2017; **Published** February 28, 2017

**Citation:** Salmi A (2017) Lyell's Syndrome: Effectiveness of a Diagnostic Management and Early Treatment. J Clin Case Rep 7: 933. doi: [10.4172/2165-7920.1000933](https://doi.org/10.4172/2165-7920.1000933)

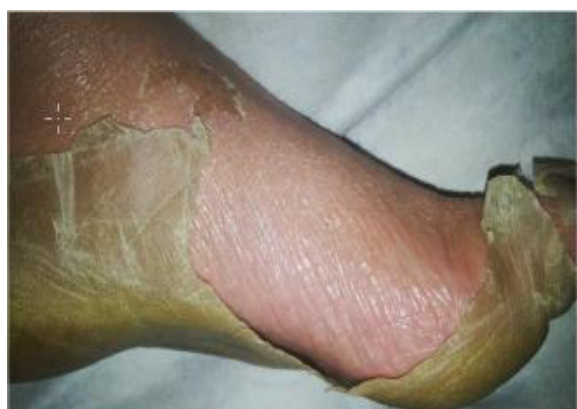**Copyright:** © 2017 Salmi A. This is an open-access article distributed under the terms of the Creative Commons Attribution License, which permits unrestricted use, distribution, and reproduction in any medium, provided the original author and source are credited.



**Figure 2:** Bullous lesions (right forearm).



**Figure 3:** Epithelial regeneration and hyperpigmentation (Left foot).



**Figure 4:** Epithelial regeneration and hyperpigmentation (Right foot).

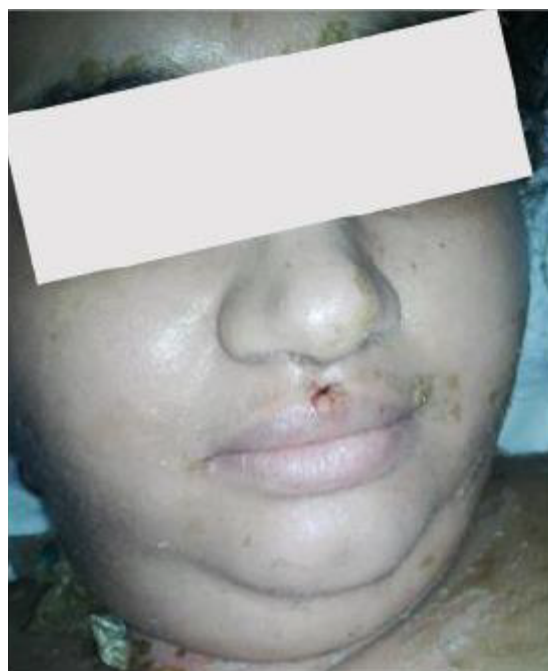series is 1 to 2 cases per million year [7]. This is a serious drug allergy, exceptional and unpredictable. It leads to destruction more or less extensive in the most superficial party of the skin. The mucous membranes of the mouth, eyes and genitalia are also affected. The disease extends for a few days (five on average). The severity depends largely

on the final extent of the lesions of the skin and mucous membranes. The regeneration of the skin is fast, averaging 10 to 15 days. (Figures 3-5). Clinically [7,8] topography skin lesions predominate in the face, neck and trunk, spreading rapidly to all integument; the sudden onset of large epidermal detachment gave way to a red oozing dermis, which was the case in our patient. The evolution of the cutaneous symptoms was spectacular. Skin lesions remained without superinfection clean and complete healing was done after 10 days compared to the beginning of installation.

The responsibility for drugs in the genesis of this syndrome is estimated at 60% to 70% of cases. The onset time is 1 to 4 weeks after the beginning of the drug taken, on average 12-14 days. The accident may begin several days after stopping the drug if its elimination half-life is long. When the treatment is taken for more than 2 months, the risk becomes negligible. Its occurrence is independent of the dose and minor exposure can be enough to trigger the maladie [9,10]. According to data from the literature, almost all antibiotics can be criminalized, with a particular frequency for penicillin's [9,11], quinolones succeed then [12,13] vancomycin [14], macrolides and anti-tuberculous drugs [9,15].

In our patient, the concept of drug intake was found: she received three drugs: A cough suppressant (ZEAL), a nutritional supplement (GESTARELLE G Pregnancy) and betalactamines antibiotic. Cephalexin 1000 (antibiotic of first generation cephalosporin). Of the three drugs used by the patient, they are beta-lactamines antibiotics that are strongly suspected in the onset of this case NET: the patient was already under GESTARELLE G Pregnancy, several weeks ago one hand (over 1 month) and secondly the antitussive was prescribed after the onset of skin lesions, for a dry cough. Treatment of SL is symptomatic that the first step is stopping all suspect drug. At the same time with this decision, the management is based on fluid and electrolyte intake and quality of analgesia in an aseptic environment rigorous.

Parenteral nutrition is often seen indicated the presence of lesions year the oral cavity, making any oral feeding difficult or impossible.



**Figure 5:** Healing lesions of the face.

In this case, power is hyperproteic seen hypercatabolism which characterizes this situation.

Finally, local mucocutaneous care, made in strict aseptic technique is another supportive measure until wound healing. There is currently no specific treatment to be well established. Systemic corticosteroids remains controversial, various immunosuppressive treatments (Cyclophosphamide, cyclosporine) have been tried in some cases without compelling evidence of their effectiveness. The benefits of high doses of intravenous immunoglobulins have not been confirmed. SL prognosis remains reserved, depends on several pejorative factors including age, the surface of the skin peeling, the delay in diagnosis and management, late discontinuation of the drug and especially infectious complications, frequent and formidable as responsible for a high mortality rate. It is evaluated using a specific scale of severity of the disease, the SCORTEN<sup>6</sup>. It consists of seven clinical and laboratory parameters, that must be collected within 24 hours after admission. The most significant effects are scars dyschromic type of hyperpigmentation (Figures 3 and 4), and corneal sequelae (pillowcases, white spots, which may require a corneal transplant).

## Conclusion

Lyell's syndrome is a pathology rare but grave, burdened with high morbidity and mortality. This observation illustrates the importance of early management of patients with NET in an intensive care unit. Finally, it is important to inform the patient about the need for early consultation before any post-medicated dermatological symptoms. These prevention methods will further reduce the incidence of this disease and improve prognosis by early treatment.

## References

1. Lyell A (1956) Toxic epidermal necrolysis: an eruption resembling scalding of the skin. *Br J Dermatol* 68: 355-361.
2. Roujeau JC, Guillaume JC, Fabre JP, Penso D (1990) Toxic epidermal necrolysis (Lyell syndrome) incidence and drug etiology in France, 1981-1985. *Arch dermatol* 126: 39-42.
3. Chan HL (1995) Toxic epidermal necrolysis in Singapore, 1989 through 1993: Incidence and antecedent drug exposure. *Arch Dermatol* 131: 1212-1213.
4. Lissia M, Mulas P, Bulla A, Rubino C (2010) Toxic epidermal necrolysis (Lyell's disease). *Burns* 36: 152-163.
5. Fritsch PO, Sidoroff A (2000) Drug-induced Stevens-Johnson syndrome/toxic epidermal necrolysis. *Am J ClinDermatol* 1: 349-360.
6. Bastuji-Garin S, Fouchard N, Bertocchi M, Roujeau JC (2000) SCORTEN: A severity of illness Score for toxic epidermal necrolysis. *J Invest Dermatol* 115: 149-153.
7. Chosidow O, Roujeau JC, Revuz J (1991) Syndrome de Lyell (Toxic epidermal necrosis) EMC, 12450 A10.
8. Couadau E, Carles M, Ichai C (2001) Skin disorders in intensive care. Updating Conference, 551- 70. French Society Anesthesia Resuscitation, Elsevier Paris.
9. Wolkenstein PE, Roujeau JC, Revuz J (1998) Drug induced toxic epidermal necrolysis. *Clin Dermatol* 16: 399-409.
10. Correia O, Chosidow O, SaiagP, Bastuji-Garin S (1993) Evolving pattern of drug-induced toxic epidermal necrolysis. *Dermatology* 186: 32-37.
11. Surbled M, Lejus C, Milpied B, Pannier M (1996) Lyell syndrome following administration of amoxicillin in a 2-year-old child. *Ann Fr Anesth Reanim* 15: 1095-1098.
12. Melde SL (2001) Ofloxacin: A probable cause of toxic epidermal necrolysis. *Ann Pharmacother* 35: 1388-1390.
13. Mandal B, Steward M, Singh S, Jones H (2004) Ciprofloxacin-induced toxic epidermal necrolysis (TEN) in a nonagreian: A case report. *Age Ageing* 33: 405-406.
14. Prey S, Sparsa A, Boumediene A, Bonnetblanc JM, Weinbreck P, et al. (2007) Drug induced by glycopeptides. *Med mal infect* 37: 270-274.
15. Mame Thierno D, On S, Thierno Ndiaye S (2001) Lyell syndrome in Senegal: responsibility for thiacezone. *Ann Dermatol Venereol* 128: 1305-1307.