

Lumbo-Sciatica as the Initial Presentation of Acute Lymphoblastic Leukemia

Hicham El Maaroufi*, Kamal Doghmi and Mohammed Mikdame

Department of Clinical Hematology, Mohammed V. Military Hospital, University of Mohammed V-SOUISSI, Rabat, Morocco

Abstract

A 39-year-old man presented with lumbo-sciatica. C-Scan shows an aspect of herniated disc at the L5 level. He underwent emergent laminectomy and a tumor was found and biopsy made. The initial histological diagnosis was malignant lymphoma. Magnetic Resonance Imaging (MRI) revealed a lumbar epidural mass at the level of L5 and the sacral vertebrae. The correct diagnosis of epidural lymphoblastic mass and Acute Lymphoblastic Leukemia (ALL) was established based on a study of the bone marrow cells. Treatment by chemotherapy has been established.

Leukemic mass must be considered in the differential diagnosis of spinal epidural mass, even in patients with ALL.

Keywords: Lymphocytic leukemia; Epidural space; Spine; Lumbo-sciatica

Introduction

Spinal epidural tumors are very rare in patients with ALL. We treated a male patient with ALL who presented with a mass in the spinal epidural space.

Case Report

A 39-year-old man presented with a very rare spinal epidural mass manifesting as acute progressive neurological deficits. The patient presented with both lower limbs pain and ambulatory difficulties. C-Scan shows herniated disc L5. He underwent emergent laminectomy, intraoperative inspection revealed a hard tumor in the posterior epidural space. The tumor was biopsied.

Histological examination revealed a cluster of immature lymphocytes and immunohistochemical analysis showed these lymphoid cells were CD20 positive, which were consistent with the diagnosis of malignant lymphoma. MRI of the spine confirmed epidural mass extending over 40 mm in the L5 and the first sacral vertebrae level, the gadolinium injection revealed an intensive enhancement of the tumor, the medullar canal and several vertebrae (Figure 1 and 2). White blood cell count was 25000/ml, hemoglobin level was 11.2 g/dl, and platelet count was 330000 cells/ml. LDH was very high: 2995 UI. The study of bone marrow cells revealed a blasts ratio superior to 95% myeloperoxidase negative. Flow cytometry confirmed B Lymphoid type by positive CD45, CD10, CD79a and TdT markers. Cytogenetic analysis reveals no chromosomal abnormalities. Treatment by chemotherapy has been established and neurological symptoms improve in the first week of follow-up.

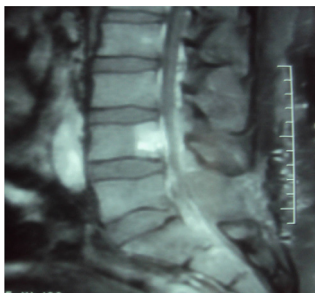


Figure 1: Sagittal T2-weighted Magnetic Resonance Image (MRI) showing a solid epidural mass at the L5-S1 levels with homogeneous enhancement.

Discussion

Extramedullary tumors consisting of lymphoid or myeloid blasts outside the bone marrow occur in 3.1–9.1% of patients with leukemia [1,2].

The mechanism of mass formation has not been clarified; the origin of the mass is thought to be the bone marrow. Small amount of leukemic cells can migrate to the spinal epidural space directly through haversian canals of the vertebral bone or hematogenously via epidural venous plexus, followed by forming the mass even before systemic leukemia.

Such extramedullary tumors are rarely reported in patients with acute lymphocytic leukemia (ALL). Sixteen cases of spinal epidural tumors in patients with ALL have been reported since 1975 only one was an adult [3,4]. Our observation is original in two aspects: the age of the patient and the revealing character of the spinal mass.

Extramedullary tumors are usually followed by evidence of leukemia in the peripheral blood or bone marrow.

Leukemic mass is usually sensitive to chemotherapy and radiation,

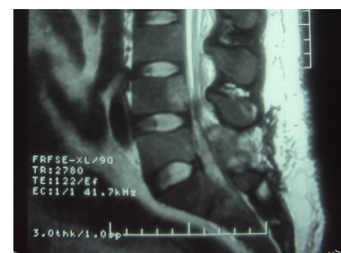


Figure 2: Sagittal T1-weighted Magnetic Resonance Image (MRI) of the lumbosacral spine showing tumor at the L5 and sacral vertebral.

***Corresponding author:** Hicham El Maaroufi, Appartement 2, Immeuble 2, Résidence les Acacias, Oueled Mtaa, 12000 Témara, Morocco, E-mail: hichamelmaaroufi@hotmail.com

Received February 27, 2012; Accepted April 06, 2012; Published April 10, 2012

Citation: Maaroufi HE, Doghmi K, Mikdame M (2012) Lumbo-Sciatica as the Initial Presentation of Acute Lymphoblastic Leukemia. J Spine 1:114. doi:10.4172/2165-7939.1000114

Copyright: © 2012 Maaroufi HE, et al. This is an open-access article distributed under the terms of the Creative Commons Attribution License, which permits unrestricted use, distribution, and reproduction in any medium, provided the original author and source are credited.

so surgical decompression is only recommended for patients with acute spinal compression causing rapidly progressive neurological deficits [1,5].

Conclusion

Physicians should consider epidural leukemic mass in the differential diagnosis of spinal symptoms, especially in leukemic patients, because early diagnosis and treatment may exclude the need for surgery and obtain a greater chance of remission and long survival.

References

1. Buyukavci M, Karacan M, Olgun H, Tan H (2003) Significance of bone marrow examination in the diagnostic process of paraspinal mass in children: a case report. *J Pediatr Hematol Oncol* 25: 822-823.
2. Oz O, Akgun H, Battal B, Yucel M, Ozturk K, et al. (2011) Acute lymphoblastic leukemia presenting with oculomotor nerve palsy. *Acta Neurol Belg* 111: 362-364.
3. Frohna BJ, Quint DJ (1993) Granulocytic sarcoma (chloroma) causing spinal cord compression. *Neuroradiology* 35: 509-511.
4. Higashida T, Kawasaki T, Sakata K, Tanabe Y, Kanno H, et al. (2007) Acute lymphocytic leukemia recurring in the spinal epidural space. *Neurol Med Chir (Tokyo)* 47: 375-378.
5. Mantadakis E, Katragkou A, Papadaki E, Papadimitriou S, Paterakis G, et al. (2008) Spinal cord compression in an adolescent with relapsed B-precursor acute lymphoblastic leukemia and mental neuropathy. *Int J Hematol* 88: 294-298.