

Lumbar Disk Fragments Mimicking Spinal Tumor: A Report of One Illustrative Case and its Review of the Literature

Xiaohui Yang¹, Qin Zhang^{1*}, Liping Wang², Hongli Yu¹ and Guohui Jie¹

¹Yuncheng Central Hospital, Shanxi, P.R. China

²Second Hospital of Lanzhou University, Gansu, P.R. China

Abstract

Background: Lumbar disc herniation (LDH) is a common disease that induces back pain and radicular pain, with an estimated annual incidence of 5 percent adults, disc fragments in cases that migrated upward or downward or no direct connection between the protruded disc materials and intradural lesions, confusion with spinal tumor, may occur.

Methods: Lumbar disc fragments mimicking tumor-like lesion with non-typical symptoms was observed on magnetic resonance imaging (MRI) and surgery in one cases and 9 cases in literature review. The present and previously reported cases of posterior epidural migrated lumbar disc fragments mimicking spinal tumor were analyzed with respect to imaging features on MRI, the level of the lesion, clinical symptoms, treatment, and outcomes.

Results: Tumor-like lesion was seen on MRI in spine region, lumbar laminectomy was performed with symptom relief in one cases and 9 cases in literature review. The pathologic examination confirmed that the specimen was an intervertebral disk.

Conclusion: MR imaging with contrast medium can differentiate herniated disc from spinal tumors and other epidural lesions. Even in cases of enhancing masses diagnosed preoperatively by MRI, surgeons should consider the possibility of epidural or intradural disc herniation.

Keywords: Disc herniation; Spinal tumour; Magnetic Resonance Imaging (MRI)

Introduction

Lumbar disc herniation (LDH) is a common disease that induces back pain and radicular pain, with an estimated annual incidence of 5 percent adults [1]. Disk fragment migration occurs in most of lumbar disc herniations [2,3]. Migration of sequestered disk fragments is an interesting and can cause non-typical symptoms which can be identified by surgery [4-6]. Though LDH can be diagnosed by magnetic resonance imaging and computed tomography, such these case are rarely reported because of limited experience and its nonspecific characteristics [7,8]. In addition, disc fragments in those cases that migrated upward or downward or no direct connection, confusion with other spinal abnormalities, such as spinal tumor, may occur [9-11]. In this report, we present one case of disc herniation diagnosed during surgery which mimicked spinal tumor lesion. And we review the literature on the migration of the sequestered disk fragments mimicked spinal tumor lesion.

Illustrative Cases Report

A 56-year-old man developed intermittent acute lumbar pain which radiated down to the lateral side of bilateral leg. He often complained of the lower limbs numbness and weakness. Physical examination revealed dorsiflexion strength score of 3/5 on both feet. Knee reflexes were decreased and ankle reflexes were absent with anesthesia on saddle. MRI showed a tumour-like lesion in the lumbar spinal canal was between the L2-L3 disc space levels. The lesion was same signal to the lumbar disk, and there was not continuity of the fragment with the L2-L3 disk space, which presented extensive disk herniation (Figures 1A-1D).

An urgent lumbar laminectomy was performed. The extruded disk fragment was readily visible in the epidural space and had a yellowish appearance after removal of the ligamentum flavum. The L2-L3 interspace was explored on the right side, and an discectomy was

performed. Inspection of the dura showed no dural protrusion. The pathologic examination confirmed the specimen was disk tissue. His lower extremity weakness and numbness gradually recovered over 1 year after operation.

Literature Review

We reviewed all published case reports and a series of cases of lumbar disc herniation similar to vertebral tumors. Patients who follow up with serial MRIs were included in the literature review. The clinical course and imaging examination of lumbar disc disease were discussed based on the characteristics of MRI, immunohistopathology and the treatment plan of previous clinical studies.

Results

We reviewed 9 cases of lumbar disc herniation mimicking the spinal tumor (Table 1). On clinical examination, 88.8% of patients with tumor-like lesion were reported back pain. Similarly, the literature showed that 33.3% of cases had positive straight leg test, 22.2% had sagging, 44.4% had weakness, and 55.6% had sensory impairment. On radiographic studies, the affected spinal levels included L2-L3, L3-L4, L4-L5, and L5-S1 level. In the classification of disc herniation, mostly affected disc were extrusion or sequestration. The average time of diagnosing tumour-like lesions by MRI was 7.52 months (N = 9 cases).

***Corresponding author:** Qin Zhang, Yuncheng Central Hospital, Shanxi, P.R. China, Tel: 863596399223; E-mail: zhangqin19762@126.com

Received November 29, 2018; **Accepted** December 17, 2018; **Published** December 19, 2018

Citation: Yang X, Zhang Q, Wang L, Yu H, Jie G (2018) Lumbar Disk Fragments Mimicking Spinal Tumor: A Report of One Illustrative Case and its Review of the Literature. J Trauma Treat 7: 437. doi: [10.4172/2167-1222.1000437](https://doi.org/10.4172/2167-1222.1000437)

Copyright: © 2018 Yang X, et al. This is an open-access article distributed under the terms of the Creative Commons Attribution License, which permits unrestricted use, distribution, and reproduction in any medium, provided the original author and source are credited.

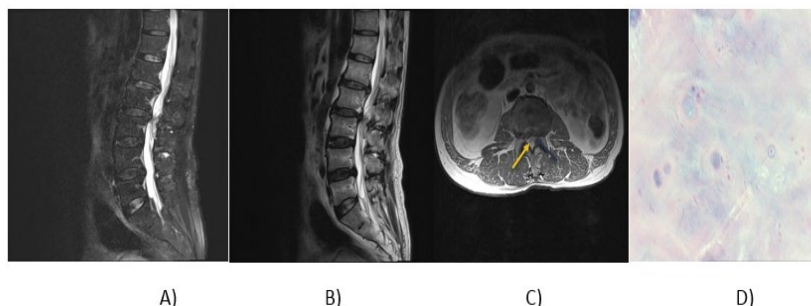


Figure 1: Disk herniation models (A-D).

Author (Year)	Number of cases	Tumor-like lesion	Symptoms (cases)	Clinical symptoms	Average time to MRI (months)
Kim HS et al. [10]	1	L2	Back pain right sciatica	(+) Straight leg test	2
Dimogerontas, G et al. [6]	1	L1-2 to L3-4	Back pain right sciatica	Weakness sensory disturbance	12
Liu CC et al. [9]	1	L4-L5	Back pain	Weakness decreased ankle reflex	6
Eksi MS et al. [8]	1	L3-L4	Back pain	--	4
Hoch B et al. [9]	1	L4-L5	Back pain	(+) Straight leg test weakness sensory disturbance	0.75
Lee JS et al. [11]	1	L5-S1	Back pain	Weakness sensory disturbance (+) straight leg test	4
Aydin MV et al. [15]	1	L5-S1	Back pain	Sensory disturbance decreased ankle reflex	12
Baogan Peng et al. [12]	1	L4-L5	--	Weakness sensory disturbance	3
Young-Seop Park et al. [14]	1	L3	Back pain	--	24

Table 1: Characteristics of 9 cases reporting Lumbar disk fragments mimicking spinal tumor.

Discussion

The literature contains some reports of herniated intervertebral discs mimicking spinal tumors. The most commonly associated symptom is acute exacerbation of back pain and neural deficit in spinal tumor and disc herniation and their numerous and various clinical presentations, preoperative diagnosis of intradural or epidural huge disc herniations is very difficult [12,13]. The most common path of disk debris migration is a posterior and posterolateral direction of the anterior epidural space, which is delimited by the attachment of the posterior longitudinal ligament [3,14]. Therefore, disk fragment migration usually migrate to cranial, caudal, or lateral but seldom posterior to the epidural space. Migration of a sequestered disk fragment in this manner has been reported only rarely.

Disc sequestration can be defined as herniation of the intervertebral disc with perforation of the annulus fibrosus and displacement of the posterior longitudinal ligament to the epidural space. The incidence of sequestered disc debris in the epidural space is very common, but the location of such large disc debris is rare and may cause confusion in diagnosis [15].

The incidence of intervertebral discs is very common. Diagnosis of posterior displaced intervertebral disc segments may be difficult because of their radiological appearance similar to other common epidural lesions. Therefore, infections, tumors, degenerative diseases, trauma and iatrogenic lesions at the same anatomical site should also be considered [16]. The sequestered disc generally causes inflammation and peripheral neovascularization. Magnetic resonance imaging is the preferred method for evaluating cauda equina nerve compression [3,5]. Enhanced contrast around lesions can cause confusion in differential diagnosis [3]. Disc fragments are usually hypointense on T1-weighted

scans and hyperintense on T2-weighted scans in 80% of cases. Most disc fragments show enhanced peripheral contrast, which is attributed to the inflammatory granulation tissue and neovascularization around sequestered tissue [5], as shown in the present report. On the other hand, tumors usually enhance uniformly on gadolinium MR images. Synovial cysts have a characteristic MR imaging signal intensity, and they are associated with the facet joint. Epidural abscess can be manifested as low signal on T1-weighted imaging, high signal on T2-weighted imaging and rim enhancement mass. Although MRI remains the best modality of choice to study spinal pathologies, however, some disc fragments still can be mistaken for other more common benign epidural and intradural tumors [4,17]. If intradural mass lesions are hypointense in T1- and T2-WI sequences, intravenous contrast studies should be combined with investigations to distinguish between disc herniation and tumor lesions [17]. The exact diagnosis of posterior displacement of a sequestered disc fragment can only be made in and after surgery.

Conclusion

We report our experience with an extremely rare case of posterior migration of herniated lumbar disc mimicking spinal tumors. Surgeons should consider the possibility of epidural or intradural disc herniation even in cases enhancing masses diagnosed preoperatively.

Conflict of Interest

All authors certify that they have no affiliations with or involvement in any organization or entity with any financial interest (such as honoraria; educational grants; participation in speakers' bureaus; membership, employment, consultancies, stock ownership, or other equity interest; and expert testimony or patent-licensing arrangements)

or non-financial interest (such as personal or professional relationships, affiliations, knowledge, or beliefs) in the subject matter or materials discussed in this manuscript.

Ethical Approval

This article does not contain any studies with human participants performed by any of the authors. Our institutional ethical board exempted this study, due to the retrospective nature, from the requirement of formal consent.

References

1. Komori H, Shinomiya K, Nakai O, Yamaura I, Takeda S, et al. (1996) The natural history of herniated nucleus pulposus with radiculopathy. *Spine* 21: 225-229.
2. Bonaroti EA, Welch WC (1998) Posterior epidural migration of an extruded lumbar disc fragment causing cauda equina syndrome. Clinical and magnetic resonance imaging evaluation. *Spine* 23: 378-381.
3. Schellinger D, Manz HJ, Vidic B, Patronas JN, Deveikis JP (1990) Disk fragment migration. *Radiol* 175: 831-836.
4. Blikra G (1969) Intradural herniated lumbar disc. *J Neurosurg* 31: 676-679.
5. Carvi Y, Nievas MN, Hoellerhage HG (2009) Unusual sequestered disc fragments simulating spinal tumors and other space-occupying lesions. *Clinical Article. J Neurosurg Spine* 11: 42-48.
6. Dimogerontas G, Paidakakos NA, Konstantinidis E (2012) Voluminous free disk fragment mimicking an extradural tumor. *Neurologia Medico-Chirurgica* 52: 656-658.
7. Sarlieve P, Delabrousse E, Clair P, Hussein HC, Schmitt C, et al. (2004) Intradural disc herniation with cranial migration of an excluded fragment. *Clin Imaging* 28: 170-172.
8. Eksi MS, Yener U, Akakin A, Konya D (2010) Posterior epidural disc herniation at L3-L4 mimicking a spinal tumor: a case report. *Journal of Neurosurgical Sciences* 54: 71-76.
9. Liu CC, Huang CT, Lin CM, Liu KN (2011) Intradural disc herniation at L5 level mimicking an intradural spinal tumor. *Eur Spine J* 20: 326.
10. Song KJ, Kim KB, Lee KB (2012) Sequestered thoracic disc herniation mimicking a tumoral lesion in the spinal canal - A case report. *Clin Imaging* 36: 416-419.
11. Lee JS, Suh KT (2006) Intradural disc herniation at L5-S1 mimicking an intradural extramedullary spinal tumor: A case report. *J Korean Med Sci* 21: 778-780.
12. Peng B, Pang X (2013) Tumour-like lumbar disc herniation. *BMJ Case Reports*.
13. Sengoz A, Kotil K, Tasdemiroglu E (2011) Posterior epidural migration of herniated lumbar disc fragment. *J Neurosurg Spine* 14: 313-317
14. Razek A, Ashmalla GA (2018) Assessment of paraspinal neurogenic tumors with diffusion-weighted MR imaging. *Eur Spine J* 27: 841-846.
15. Aydin MV, Ozel S, Sen O, Yildirim T (2004) Intradural disc mimicking: a spinal tumor lesion. *Spinal cord* 42: 52-54
16. Chen CY, Chuang YL, Yao MS (2006) Posterior epidural migration of a sequestered lumbar disk fragment: MR imaging findings. *AJNR Am J Neuroradiol* 27: 1592-1594.
17. Demirci A, Er U (2011) A lumbar disc herniation mimicking spinal tumor with intra- and extradural components. *The Spine J* 11: 90-91.