

Lues Maligna in a Patient with Human Immunodeficiency Virus: Case Report and Review of the Literature

Zhang S^{1*}, Chang J², Hean S¹ and Spiegel J¹

¹Department of Medicine, Harbor-UCLA Medical Center, Torrance, CA, USA

²Department of Medicine, University of Southern California, Los Angeles, CA, USA

Abstract

Syphilis is a sexually transmitted infection with rising incidence in recent years due to increased rates of high-risk sexual behaviors. Often called “the great imitator,” syphilis can have many different presentations in its various stages: latent, primary, secondary and tertiary. One form of secondary syphilis is ulceronodular syphilis, also known as lues maligna. We report a case of a 48-year-old Filipino man who presented with a diffuse, ulcerating, papular rash and was subsequently diagnosed concurrently with both lues maligna and human immunodeficiency virus.

Keywords: Lues maligna; Syphilis; Ulcers; Human immunodeficiency virus

Introduction

Lues maligna-also known as malignant syphilis-is a rare manifestation of secondary syphilis that is predominantly seen in patients with human immunodeficiency virus (HIV) as well as in other immunocompromised states [1,2]. It is characterized by severe ulcerative lesions which typically present on the trunk and extremities and can be associated with nonspecific symptoms such as fever, weight loss, joint pain, and malaise. While the exact pathogenesis of this condition remains unknown, it is suspected that the loss of helper T cells as seen in HIV and acquired immunodeficiency syndrome (AIDS) likely contributes [3]. Here, we describe the case of a patient with newly diagnosed HIV who developed painful cutaneous lesions consistent with lues maligna.

Case Presentation

A 48-year-old Filipino male presented with two months of painful skin lesions, weight loss, and subjective fevers. The patient reported that these lesions initially appeared as small, erythematous papules on his feet and lower shins, but subsequently became larger and more painful. The lesions then spread to other sites on his body including the arms, hands, trunk and face. Two weeks prior to presentation, he developed a painless ulcer on the shaft of his penis. In addition, the patient reported a 40-pound unintentional weight loss over the past year and intermittent fevers. He also reported negative testing for HIV and other sexually transmitted infections one year prior, yet subsequently had unprotected sexual activity with both men and women approximately five months prior.

Vital signs on presentation were notable for a temperature of 39.3 degrees Celsius but were otherwise within normal limits. Physical exam was notable for multiple papular lesions throughout the bilateral upper and lower extremities, including the palms and soles, chest, back, and face (Figure 1). These lesions ranged in size from 5mm to 3 cm in diameter with associated crusting and eschar. There was also a 3 × 2 cm well-demarcated, painless, flat ulcer with a pink base over his left penile shaft in addition to a 2 × 2 cm flat, pink-based ulcer on his left buttock (Figures 2 and 3). The remainder of his exam was otherwise unremarkable.

Laboratory studies showed a hemoglobin of 8.8 g/dL with mean corpuscular volume (MCV) of 75.9 fL, white blood count of 4.3×10^9 cells/L (neutrophils 2.7×10^9 cells/L, lymphocytes 1.1×10^9 cells/L, monocytes 0.5×10^9 cells/L), and platelets of 413×10^9 cells/L. Chemistry panel and liver function tests were within normal limits.

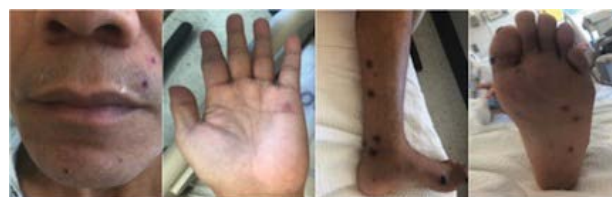

Figure 1: Scattered, papular lesions with central ulceration and overlaying eschar throughout the bilateral upper and lower extremities, face and body.

Blood culture and cerebrospinal fluid studies were unremarkable. Sputum and serologic testing for fungal, mycobacterial, and herpetic infections were all negative, including a swab taken from the penile ulcer. An HIV antibody/antigen screen and confirmatory antibody test both returned positive, with a CD4 count of 264 and 18.8% CD4 cells. Rapid plasma reagin (RPR) titer was 1:64 with a positive fluorescent treponemal antibody absorption (FTA-ABS) test. Biopsy of one of the cutaneous lesions on his forearm showed nonspecific ulceration and fibrosis as well as perivascular lymphocyte and neutrophil infiltration with negative stains for spirochetes, fungi and mycobacteria (Figure 4). The patient’s physical exam, serologic testing, and biopsy results were consistent with lues maligna due to secondary syphilis.

A single intramuscular injection of 2.4 million units of penicillin G benzathine was administered. He was monitored following treatment and did not develop a Jarisch-Herxheimer reaction (JHR). Within a few days following this treatment, he experienced resolution of his fevers and improvement of his skin lesions (Figure 5). The patient was subsequently started on anti-retroviral therapy with emtricitabine-tenofovir and dolutegravir for management of his HIV infection. His evaluation one and a half months after the penicillin injection showed healed skin lesions with some mild overlaying hyperpigmentation as well as complete resolution of his penile ulcer (Figure 6).

***Corresponding author:** Zhang S, Department of Medicine, Harbor-UCLA Medical Center, Torrance, CA, USA, Tel: 909-569-8546; E-mail: szhang3@dhs.lacounty.gov

Received February 15, 2019; **Accepted** February 22, 2019; **Published** February 28, 2019

Citation: Zhang S, Chang J, Hean S, Spiegel J (2019) Lues Maligna in a Patient with Human Immunodeficiency Virus: Case Report and Review of the Literature. J Clin Case Rep 9: 1217. doi: [10.4172/2165-7920.10001217](https://doi.org/10.4172/2165-7920.10001217)

Copyright: © 2019 Zhang S, et al. This is an open-access article distributed under the terms of the Creative Commons Attribution License, which permits unrestricted use, distribution, and reproduction in any medium, provided the original author and source are credited.

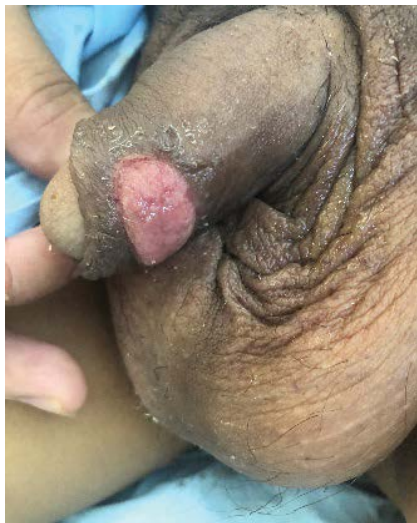

Figure 2: 3 × 2 cm painless, flat ulcer with a pink base over the left penile shaft.



Figure 3: 2 × 2 cm painful, flat, pink-based ulcer on the left buttock.

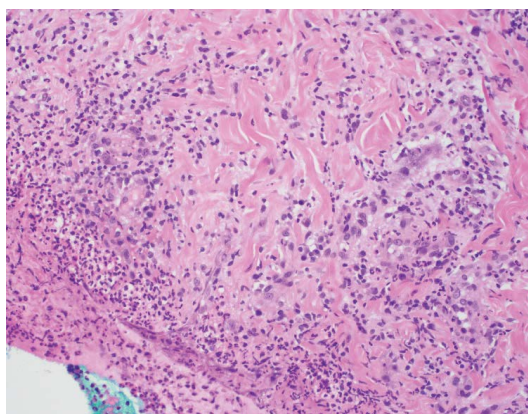


Figure 4: Skin biopsy showing ulceration and fibrosis as well as perivascular lymphocyte and neutrophil infiltration.

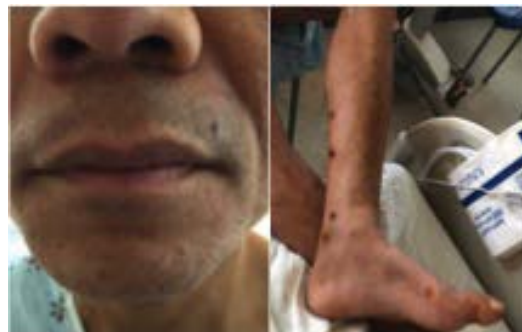

Figure 5: Improvement of skin lesions a week after treatment with penicillin.

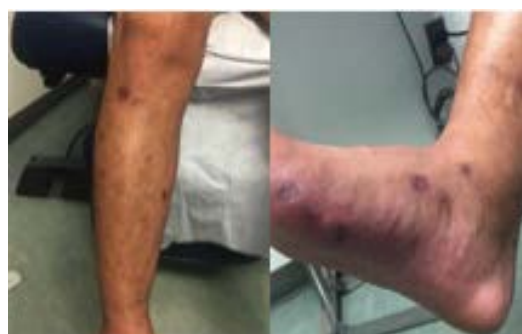

Figure 6: Healed skin lesions one and half months after treatment with penicillin.

Discussion

Lues maligna is a rare manifestation of secondary syphilis that is also referred to as “ulceronodular syphilis” and “malignant syphilis”. Prior to the 1980s, the incidence of lues maligna was estimated to be very low at 0.12-0.36%, with only 14 patients identified worldwide [4]. Following the HIV/AIDS epidemic, however, the number of reported cases has continued to rise with HIV-positive patients deemed 60 times more likely to develop lues maligna than those who are HIV-negative [2]. Furthermore, syphilis is thought to increase the risk of HIV infection due to the anogenital ulcerations that serve as a route for transmission [5]. Although the majority of lues maligna cases were described in individuals with HIV/AIDS or men who have sex with men (MSM), this disease can also be seen in those with other immunocompromising conditions such as chronic alcoholism, poorly controlled diabetes, or tuberculosis [6,7]. Despite these associations and the rise in incidence, lues maligna continues to be a rare diagnosis with less than 40 cases of HIV-associated lues maligna reported in the literature [8].

The classic presentation of lues maligna is multiple, well-demarcated papules or nodules throughout the body that ulcerate and crust, much like those found on our patient. These cutaneous lesions may mimic viral exanthems or disseminated fungal infections, making visual diagnosis challenging. Other features of lues maligna are nonspecific and include fever, generalized lymphadenopathy, malaise, arthralgias, and weight loss. In this case, our patient had both the characteristic rash as well as the nonspecific symptoms of fever and weight loss that preceded it. His painless penile ulcer was suspected to be condyloma lata of secondary syphilis rather than the chancre of primary syphilis, particularly given the time course of his symptoms.

The diagnostic criteria for lues maligna include the following:

- Strongly positive RPR titer.
- A severe JHR.
- Characteristic gross and microscopic morphology.
- Rapid resolution of the lesions with antibiotics [9].

This patient had a positive RPR titer and FTA-ABS, characteristic cutaneous lesions and histopathology, and prompt resolution of his fevers and skin lesions with a single dose of penicillin G benzathine. While no spirochetes were seen on the biopsy of the patient's skin lesion, this finding has a low sensitivity in the diagnosis of lues maligna. In fact, histopathology of lues maligna most often shows perivascular lymphocyte and neutrophil infiltration as was seen in our case [2,3,8]. In addition, though our patient did not develop a JHR, he had also taken a total of 1 gram of acetaminophen for pain in his lower extremity lesions within 24 hours of treatment with penicillin, which may have prevented possible JHR symptoms such as fevers or myalgias. Several other cases of lues maligna without JHR have been noted in previous reports as well [2,3]. There are a variety of treatment regimens with penicillin including a single intramuscular injection, weekly injections, or 14-21 days of intravenous infusions; regardless of the regimen, there is often rapid improvement or complete resolution of the cutaneous lesions [2,3,8].

While the exact pathophysiology of lues maligna remains unclear, it is presumed that deficiencies in cell-mediated immunity are likely to contribute. Remote studies of the immune response in patients with primary and secondary syphilis demonstrated that there is a decreased response of lymphocytes to phytohemagglutinin (PHA), a protein that can be used to stimulate T cell lymphocyte cell division [10,11]. In patients with secondary syphilis, the presence of specific factors in the serum was found to impair the activation of lymphocytes by PHA. In modern times, it is postulated that more virulent strains of *Treponema* may be associated with an increased risk of developing lues maligna, though this has yet to be formally demonstrated [12,13].

Our case describes a patient who had risk factors, clinical findings, and serologic tests all consistent with lues maligna due to secondary syphilis in the setting of new HIV co-infection. Given the worldwide prevalence of HIV/AIDS and syphilis as well as the association between these two conditions, clinicians should always consider the diagnosis of lues maligna when encountering new cutaneous lesions in those with high-risk behavior.

Conclusion

In conclusion, we report a case of lues maligna in a patient with newly diagnosed HIV who was successfully treated with one dose of intramuscular penicillin and subsequently started on antiretroviral therapy. As syphilis can have a myriad of clinical manifestations and mimic other conditions – therefore possibly clouding the diagnosis – clinicians should consider lues maligna as a rare presentation of a common condition when evaluating patients with ulcero-nodular skin lesions in order to provide prompt diagnosis and treatment.

References

1. Schöfer H, Imhof M, Thoma-Greber E, Brockmeyer N, Hartmann M, et al. (1996) Active syphilis in HIV infection: A multicentre retrospective survey in GASG. *Genitourin Med* 72: 176-181.
2. Tucker J, Shah S, Jarell A, Tsai K, Zembowicz A, et al. (2009) Lues maligna in early HIV infection case report and review of the literature. *Sex Transm Dis* 36: 512-514.
3. Kelly J, LeLeux T, Citron D, Musher D, Giordano T (2011) Ulcero-nodular syphilis (lues maligna praecox) in a person newly diagnosed with HIV infection. *BMJ Case Rep* 2: 1.
4. Sands M, Markus A (1995) Lues maligna, or ulcero-nodular syphilis, in a man infected with human immunodeficiency virus: Case report and review. *Clin Infect Dis* 20: 387-390.
5. Jarzebowski W, Caumes E, Dupin N, Farhi D, Lascaux A, et al. (2012) Effect of early syphilis infection on plasma viral load and CD4 cell count in human immunodeficiency virus-infected men: Results from the FHDH-ANRS CO4 cohort. *Arch Intern Med* 172: 1237-1243.
6. Bayramgürler D, Bilen N, Yildiz K, Sikar A, Yavuz M (2005) Lues maligna in a chronic alcoholic patient. *J Dermatol* 32: 217-219.
7. Hofmann U, Hund M, Bröcker E, Hamm H (2005) "Lues maligna" in a female patient with diabetes. *JDDG* 3: 780-782.
8. Mena AL, Braniecki M, Nasir A, Brito M (2017) The great impostor: Lues maligna in an HIV-infected male. *SAGE Open Medical Case Rep* p: 5.
9. Fisher D, Chang L, Tuffanelli D (1969) Lues maligna: Presentation of a case and a review of the literature. *Arch Dermatol* 99: 70-73.
10. Levene G, Turk J, Wright D, Grimble A (1969) Reduced lymphocyte transformation due to a plasma factor in patients with active syphilis. *Lancet* 2: 246-247.
11. Levene G, Wright D, Turk J (1971) Cell-mediated immunity and lymphocyte transformation in syphilis. *P Roy Soc Med* 64: 426-428.
12. Watson K, White J, Salisbury J, Creamer D (2004) Lues maligna. *Clin Exp Dermatol* 29: 625-627.
13. Pföhler C, Koerner R, von Müller L, Vogt T, Müller C (2011) Lues Maligna in a patient with unknown HIV infection. *BMJ Case Rep* 2: 1.