

## Look to the Left: A Rare Case of Recurrent Upper GI Bleeding

Sven Pannach<sup>1\*</sup>, Stefan Brückner<sup>1</sup>, Florian Ehehalt<sup>2</sup> and Jan Beyer Westendorf<sup>3</sup>

<sup>1</sup>Division of Gastroenterology, Dresden University Hospital, Germany

<sup>2</sup>Surgical Department, Dresden University Hospital, Germany

<sup>3</sup>Center for Vascular Diseases and Medical Clinic III, Germany

### Abstract

We present the case of a 63 year old male who developed recurrent massive gastric varicose vein bleeding episodes years after necrotising pancreatitis. Endoscopy revealed extensive gastric but no esophageal varices. Ultrasonographic findings included an enlarged spleen, normal portal vein diameter and flow and a regular liver texture without signs of cirrhosis. CT scan demonstrated massive perigastric and splenic collateral veins due to chronic splenic vein occlusion. Left-sided portal hypertension was diagnosed and the patient treated with splenectomy. In an endoscopic 2-year follow-up, gastric varicose veins have completely regressed and the patient has remained free of recurrent GI bleeding complications.

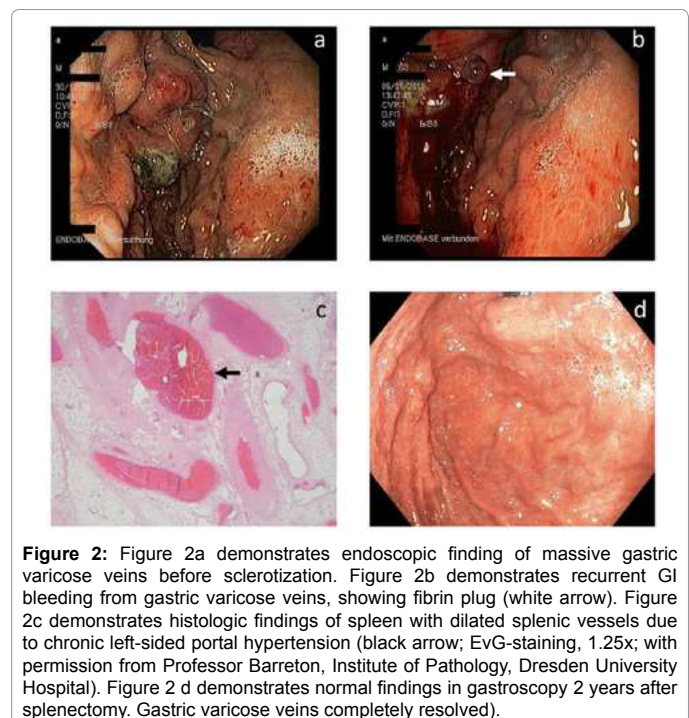
**Keywords:** Gastric variceal bleeding; Left sided portal hypertension; Splenectomy

### Case Report

We report on a rare case of recurrent gastric variceal bleeding in a 63 year old male with a history of necrotising pancreatitis in 2005 who underwent pancreatico-jejunostomy for large pancreatic pseudocysts as well as jejunostomy for gastrointestinal stroma tumor in 2006. In December 2010, the patient presented twice with massive upper gastrointestinal (GI) bleeding due to extensive gastric varices, 14 days apart. Both episodes could be stabilized endoscopically using histoacryl sclerotherapy. Amongst others, paraclinical abnormalities included anaemia (hemoglobin 5.2 mmol/l), thrombocytopenia (58 Gpt/l) and leucopenia (1.87 Gpt/l).

### Clinical course and results of imaging procedures

Endoscopy revealed a portal-hypertensive gastropathy as well as extensive gastric varices at the great gastric curvature but no esophageal varices. Ultrasonography demonstrated a normal portal vein diameter and flow as well as a regular liver texture without signs of cirrhosis. On the other hand, ultrasound revealed an enlarged spleen (160 × 70 mm) and a CT scan demonstrated massive perigastric and splenic collateral veins due to chronic thrombotic splenic vein occlusion. Of note, splenomegaly was not suspected during clinical examination and was only found in imaging. Furthermore, re-evaluation of the CT scan from 2005 demonstrated splenic vein compression by a large pancreatic pseudocyst (Figure 1a-1c). Despite successful histoacryl treatment of both upper GI bleedings the patient remained unstable with recurrent minor bleeding episodes. Within 6 days of the last sclerotherapy, the patient developed a third, massive gastric variceal bleeding (Figure 2a and 2b), which led to hemorrhagic shock and required repeated histoacryl injections, terlipressin infusions

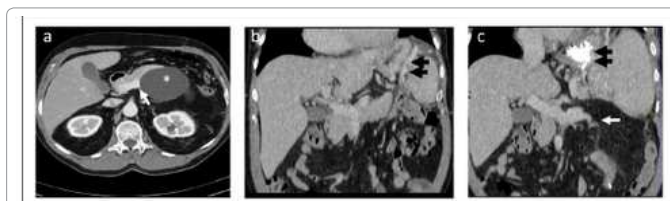


**Figure 2:** Figure 2a demonstrates endoscopic finding of massive gastric varicose veins before sclerotization. Figure 2b demonstrates recurrent GI bleeding from gastric varicose veins, showing fibrin plug (white arrow). Figure 2c demonstrates histologic findings of spleen with dilated splenic vessels due to chronic left-sided portal hypertension (black arrow; EvG-staining, 1.25x; with permission from Professor Barretton, Institute of Pathology, Dresden University Hospital). Figure 2 d demonstrates normal findings in gastroscopy 2 years after splenectomy. Gastric varicose veins completely resolved).

and transfusions of 16 units red blood cell concentrates, 2 units of platelets, 5 units of fresh frozen plasma, 2.000 units of prothrombin complex concentrate and 2500 units of factor XIII concentrate in ICU, following our institutional transfusion protocol.

### Diagnosis

We diagnosed recurrent gastric variceal bleeding and hypersplenism



**Figure 1:** Figure 1a demonstrates CT scan from 2005 with splenic vein compression (arrow) by a large pancreatic pseudocyst (asterix). Figure 1b demonstrates massive paraogastric collateral veins (black arrows). Figure 1c demonstrates extent of gastric variceal sclerotization (black arrows) and splenic vein occlusion (white arrow). All images with permission from Professor Laniado, Institute of Radiology, Dresden University Hospital.

\*Corresponding author: Sven Pannach, Division of Gastroenterology, Dresden University Hospital, Germany, Tel: +493514582627; Fax: +493514585319; E-mail: [sven.pannach@uniklinikum-dresden.de](mailto:sven.pannach@uniklinikum-dresden.de)

Received April 26, 2016; Accepted May 23, 2016; Published May 27, 2016

**Citation:** Pannach S, Brückner S, Ehehalt F, Westendorf JB (2016) Look to the Left: A Rare Case of Recurrent Upper GI Bleeding. J Clin Case Rep 6: 795. doi:10.4172/2165-7920.1000795

**Copyright:** © 2016 Pannach S, et al. This is an open-access article distributed under the terms of the Creative Commons Attribution License, which permits unrestricted use, distribution, and reproduction in any medium, provided the original author and source are credited.

due to left-sided portal hypertension (LSPH), based on the findings of an occluded splenic vein with pronounced collateral veins as well as splenic enlargement with thrombocytopenia (58 Gpt/l) and leukopenia (1.87 Gpt/l) without portal hypertension or liver cirrhosis.

## Treatment

Due to three episodes of massive upper GI bleeding within 3 weeks, interdisciplinary consensus led to a splenectomy after interventional coil occlusion of the splenic artery. During surgery the chronic thrombotic occlusion of V. lienalis was confirmed and histology revealed massive vascular dilatation of intrasplenic vessels (Figure 2c). Following an uncomplicated post-operative period the patient was discharged on day 7, at which time both platelet count and leucocyte count had returned to normal.

## Clinical follow up 2 years later

Recently, the patient presented for an endoscopic 2-year follow-up. After splenectomy, the massive gastric varicose veins have completely regressed (Figure 2d). Hemoglobin (10.4 mmol/l), platelet and leucocyte count (256 and 9.6 Gpt/l, respectively) were still within normal range and since the splenectomy, the patient has remained free of recurrent GI bleeding complications.

## Discussion

Left-sided portal hypertension (LSPH), also referred to as sinistral portal hypertension, is a segmental form of portal hypertension usually due to an isolated splenic vein obstruction [1-3]. Since splenic vein occlusion often develops without specific symptoms, the incidence remains unclear but it is suggested to be present in less than 5% of all patients with portal hypertension [1] and to be mainly related to splenic vein thrombosis in acute or chronic pancreatitis or malignant diseases [4-7].

Compensation of splenic vein occlusion and increased venous pressure consists of splenic vein drainage through short gastric veins with the consequence of varicose vein formation and risk of rupture [8]. Diagnosis is usually made in acute upper GI bleeding situations when massive and often recurrent gastric variceal bleeding manifest [9]. On the other hand, incidences of gastric variceal bleeding in LSPH vary between 4 and 25%, probably due to the low number of patients included in these analyses [3,8-10].

Another diagnostic criterion is the finding of sonographic and paraclinic signs of hypersplenism (spleen enlargement, thrombocytopenia, leukopenia) [8,11] in the absence of portal vein occlusion or liver cirrhosis. Of note, our case did not have clinically apparent splenomegaly, which was only confirmed by imaging. Consequently, the imaging procedures for patients with esophageal or gastric varices should not only focus on liver cirrhosis but should include a screening for splenomegaly ("look to the left"). Acute therapy of gastric variceal bleeding consists of histoacryl sclerotherapy [12], but endoscopic treatment may only be effective in the acute setting and not over long. Recurrent bleeding episodes, as in our case, are frequent with rates higher than 50% [12], due to the persistent increase of venous pressure. Definitive treatment may therefore only be achieved by splenectomy, which can reduce the rates of recurrent bleeding complications below 1% [6,8,11]. In contrast, the benefit of prophylactic splenectomy for incidental finding of gastric varicose veins without bleeding events is unclear [3,5,13].

Several treatment options exist for patients with variceal bleeding. The underlying pathomechanism of portal hypertension often is portal

or splenic vein thrombosis and anticoagulation should be considered in the early phase to achieve recanalization of the affected vein to prevent development of collateral veins [14,15]. In our case, anticoagulation was not provided in the acute phase of splenic vein thrombosis, since the thrombotic occlusion remained undiagnosed. During our treatment, anticoagulation was considered to be ineffective due to chronic vein occlusion and dangerous because of recurrent acute variceal bleeding. Transjugular portosystemic shunt (TIPS) as an option for treating recurrent variceal bleeding [16] was not indicated, since neither cirrhosis nor portal vein hypertension was present [16].

## Conclusion

Patients with isolated gastric varicose veins should be assessed for signs of splenomegaly or hypersplenism and splenic vein obstruction. LSPH should be suspected, if splenomegaly or hypersplenism are present in the absence of portal vein occlusion or liver cirrhosis. Presence of collateral veins in splenic vein occlusion is an indicator of chronic disease and correlates to an increased bleeding risk. As a consequence, anticoagulant treatment will have little benefit but could potentially increase bleeding risk and intensity. If acute gastric variceal bleeding occurs in LSPH patients, splenectomy can drastically reduce the risk of bleeding recurrence and, due to the reduced splenic consumption seen in hypersplenism, normalize concomitant thrombocytopenia.

## References

1. Madsen MS, Petersen TH, Sommer H (1986) Segmental portal hypertension. *Ann Surg* 204: 72-77.
2. Köklü S, Coban S, Yüksel O, Arhan M (2007) Left-sided portal hypertension. *Dig Dis Sci* 52: 1141-1149.
3. Köklü S, Yüksel O, Arhan M, Coban S, Başar O et al. (2005) Report of 24 left-sided portal hypertension cases: a single-center prospective cohort study. *Dig Dis Sci* 50: 976-982.
4. Nadkarni NA, Khanna S, Vege SS (2013) Splanchnic venous thrombosis and pancreatitis. *Pancreas* 42: 924-931.
5. Heider TR, Azeem S, Galanko JA, Behrns KE (2004) The natural history of pancreatitis-induced splenic vein thrombosis. *Ann Surg* 239: 876-880.
6. Evans GR, Yellin AE, Weaver FA, Stain SC (1990) Sinistral (left-sided) portal hypertension. *Am Surg* 56: 758-763.
7. Lankisch PG (1990) The spleen in inflammatory pancreatic disease. *Gastroenterology* 98: 509-516.
8. Sakorafas GH, Sarr MG, Farley DR, Farnell MB (2000) The significance of sinistral portal hypertension complicating chronic pancreatitis. *Am J Surg* 179: 129-133.
9. Ryan BM, Stockbrugger RW, Ryan JM (2004) A pathophysiologic, gastroenterologic, and radiologic approach to the management of gastric varices. *Gastroenterology* 126: 1175-1189.
10. Bradley EL 3rd (1987) The natural history of splenic vein thrombosis due to chronic pancreatitis: indications for surgery. *Int J Pancreatol* 2: 87-92.
11. Wang L, Liu GJ, Chen YX, Dong HP, Wang LX (2012) Sinistral portal hypertension: clinical features and surgical treatment of chronic splenic vein occlusion. *Med Princ Pract* 21: 20-23.
12. Sarin SK (1997) Long-term follow-up of gastric variceal sclerotherapy: an eleven-year experience. *Gastrointest Endosc* 46: 8-14.
13. Makowiec F, Riediger H, Emmrich J, Kröger J, Hopt UT, et al. (2004) Prophylactic splenectomy for splenic vein thrombosis in patients undergoing resection for chronic pancreatitis. *Zentralbl Chir* 129: 191-195.
14. Ageno W, Dentali F, Squizzato A (2014) How I treat splanchnic vein thrombosis. *Blood* 124: 3685-3691.
15. Ageno W, Beyer-Westendorf J, Garcia DA, Lazo-Langner A, McBane RD, et al. (2016) Guidance for the management of venous thrombosis in unusual sites. *J Thromb Thrombolysis* 41: 129-143.
16. de Franchis R (2010) Revising consensus in portal hypertension: report of the Baveno V consensus workshop on methodology of diagnosis and therapy in portal hypertension. *J Hepatol* 53: 762-768.