

Laparoscopic Cholecystectomy in a Patient with Portal Cavernoma

Nilanjan Panda^{1*}, Ruchira Das², Subhoroto Das¹, Samik K Bandopadhyay¹, Dhiraj Barman¹ and Ramakrishna Mondol²

¹Department of Surgery, R.G. Kar Medical College & Hospital, Kolkata, West Bengal, India

²Department of Surgery, Bankura Sammilani Medical College and Hospital, Gobindonagar, Bankura, West Bengal, India

Abstract

Portal cavernoma (network of collateral vessels around the portal vein) is found in one-third of patients with thrombotic portal vein. Management of Cholecystitis in such a patient is problematic. Laparoscopic cholecystectomy is usually contraindicated due to risk of haemorrhage.

A 32 year old female presented with symptomatic calculous cholecystitis and portal cavernoma without portal hypertension. Liver functions were normal (non-cirrhotic, no jaundice). Conservative treatment failed. Imaging assessment was by Ultrasound Doppler, followed by CT and MRCP, MRI and MRA.

We performed laparoscopic cholecystectomy was successfully performed. Operative time 210 minutes, blood loss 50 ml. Extreme caution and painstakingly meticulous dissection around the cavernoma was the key to success. Although open cholecystectomy may assume to be safer in such patients; enhanced magnified vision, access and maneuverability made laparoscopy a preferred option. Standby laparoscopic and open vascular instruments facility is essential.

Keywords: Portal cavernoma; Laparoscopic cholecystectomy; Portal thrombosis

Introduction

The network of collateral vessels around the portal vein, a so-called portal cavernoma, is typical of chronic portal vein thrombosis (PVT) with or without portal hypertension. They surround the Calot's triangle and gallbladder fossa, making management of calculous cholecystitis in such patients controversial [1]. We report successful laparoscopic cholecystectomy in such a case.

Case Report

A 32 year old female presented with history of pain upper abdomen for two years without jaundice or upper GI bleeding. Physical examination showed no feature of acute cholecystitis or hepatosplenomegaly. Blood investigations including liver function tests were normal. Ultrasonography revealed thick walled gall bladder with multiple calculi. Multiple vascular collaterals were seen at porta hepatic. Bile duct was normal. Liver was non cirrhotic and there was no portal hypertension. A portal vein Doppler showed extensive cavernoma with normal hepato-portal flow in collaterals. A Computed Tomography (CT) of abdomen suggested no definite main portal vein (proximal splenic and superior mesenteric vein visualized) with extensive collaterals from the head of the pancreas extending to root of the mesentery below and right and left branch of portal vein above. A MRCP (Magnetic Resonance Cholangio Pancreatography) with MR angiography was done (Figures 1 and 2). It showed partial extrinsic compression on the CBD (common Bile Duct) by collaterals. There was occlusion of the main portal vein from the spleno-portal confluence to portal bifurcation. Cavernous transformation was covering Calot's triangle. Upper Gastrointestinal endoscopy was normal. The cause for cavernoma formation was unknown. The patient was posted for laparoscopic cholecystectomy.

Standard four port technique was used. Falciform ligament was carefully avoided to prevent umbilical vein trauma. Gall bladder was free in the fundus area where traction was applied. There was no adhesion around the gall bladder. As anticipated, the cavernous transformation was mainly covering the neck and Hartmann's pouch. A fundus first approach was used to gently free the gall bladder

from the few cavernous veins coursing along the gall bladder body into GB fossa (Figure 3). Near the Calot's triangle, gentle dissection between the peritoneal folds separated cystic artery and duct from the cavernoma. Duct and artery was clipped and gall bladder dissected out. A prophylactic drain was placed in hepato-renal pouch of Morrison. Operating time was 210 min, blood loss was approximately 50 ml. Postoperative recovery was uneventful. Patient was discharged on first postoperative day.

Discussion

Cavernous transformation of portal vein is the development of a network of tortuous collateral vessels bypassing the obstructive area due to PVT. It is seen in one-third of patients with thrombotic portal vein [1]. The transformation can take place as early as a week although it usually takes months. Localised abdominal inflammations like cholecystitis, pancreatitis, hydatid cyst, duodenal ulcer and iatrogenic injury predisposes to this condition [2]. Laparoscopic cholecystectomy is usually contraindicated in these patients due to multiple collaterals near the gall bladder, which increases the risk of intraperitoneal haemorrhage. On literature review, we found only one such case report [3]. In our patient, favourable factors were normal liver architecture without cirrhosis and no portal hypertension.

Pulsatile collaterals suggesting high intravascular pressure seen intra-operatively was challenging. Extreme caution and painstakingly meticulous dissection around the cavernoma was the key to success.

***Corresponding author:** Nilanjan Panda MS, P 318 b, CIT Road, Scheme 6 M, Kankurgachi, Kolkata, West Bengal, India, Pin – 700054, Tel: +91 97 48 77 49 42; +91 33 23 62 90 07; E-mail: <mailto:npanda05@aol.com>

Received December 12, 2014; **Accepted** December 24, 2014; **Published** December 31, 2014

Citation: Panda N, Das R, Das S, Bandopadhyay SK, Barman D, et al. Laparoscopic Cholecystectomy in a Patient with Portal Cavernoma. Journal of Surgery [Jurnalul de chirurgie] 2015; 10(4): 295-296 DOI: [10.7438/1584-9341-10-4-11](https://doi.org/10.7438/1584-9341-10-4-11)

Copyright: © 2015 Panda N, et al. This is an open-access article distributed under the terms of the Creative Commons Attribution License, which permits unrestricted use, distribution, and reproduction in any medium, provided the original author and source are credited.

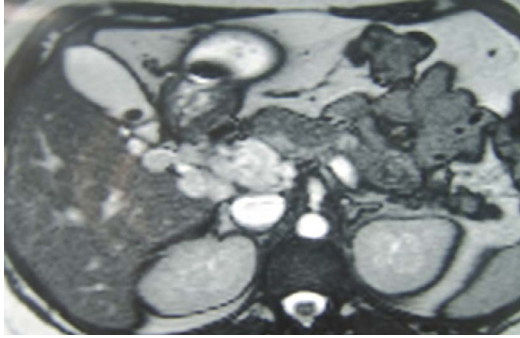


Figure 1: MRI Picture Axial Cut.

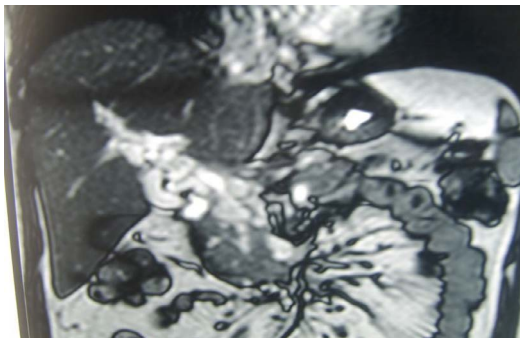


Figure 2: MR Angiography Reconstruction - Coronal Cut.

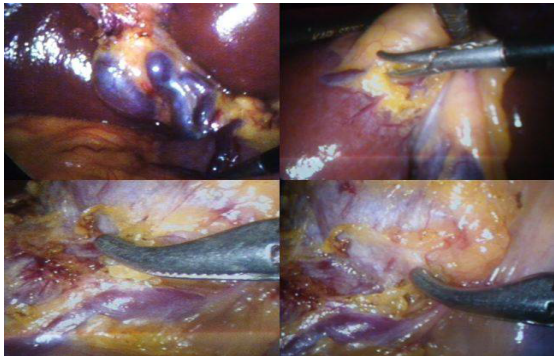

Figure 3: Intra-Operative Picture.

Harmonic energy source and taking very small bites of tissue at a time was helpful. Patient was discharged on first post-operative day. Although open cholecystectomy may assume to be safer in such patients; enhanced magnified vision, access and maneuverability made laparoscopy a preferred option.

For diagnosis ultrasound with Doppler showing absent portal vein with high echo (diamond sign) and multiple serpentine channel is sufficient but for operative planning MRCP and MRI and MRA / venography / dynamic CT is essential [4].

In the absence of cirrhosis and neoplasia, portal cavernoma is usually asymptomatic until the first variceal bleeding and has a better prognosis [5]. Intestinal ischemia or portal biliopathy may rarely develop. No treatment for the cavernoma per-se is warranted.

Conclusion

We conclude that with careful dissection and experience, laparoscopic cholecystectomy is a safe procedure in patients with portal cavernoma and symptomatic cholelithiasis. Standby laparoscopic and open vascular instruments facility is essential.

Conflict of interests

Authors have no conflict of interests to declare

References

1. Rosu A, Searpe C, Popescu M (2012) Portal Vein Thrombosis with Cavernous Transformation in Myeloproliferative Disorders: Review Update. Portal Hypertension - Causes and Complications, Prof. Dmitry Garbuzenko.
2. Webster GJM, Burroughs AK, Riordan SM (2005) Review article: Portal Vein Thrombosis – new insights into aetiology and management. *Aliment Pharmacol Ther* 21: 1-9.
3. Dalvi AN, Deshpande AA, Doctor NH, Madeo A, Bapat RD (2001) Laparoscopic Cholecystectomy in Patient with Portal Cavernoma and Portal Hypertension. *Indian J Gastroenterol* 20: 32-33.
4. Ng LS, Khoo TK (1993) Cavernous Transformation of the Portal Vein-Sonographic Findings. *Singapore Med J* 34: 125-126.
5. Janssen HL, Wijnhoud A, Haagsma EB, van Uum SHM, van Nieuwkerk CMJ, et al. (2001) Extrahepatic portal vein thrombosis: aetiology and determinants of survival. *Gut* 49: 720-724.