

Knee Arthrodesis in Severe Injured Knee Joints

Lukas Zak, Thomas M Tiefenboeck and Gerald E Wozasek*

Medical University of Vienna, Department of Trauma Surgery, Waehringerguertel, Vienna, Austria

Abstract

In this report we present our experiences with knee arthrodesis nails as a secondary salvage procedure after severe knee injuries at a level-one trauma centre. Exemplary two cases of subtotal amputation are discussed. Both cases, of totally destroyed knee joints, were treated with a unilateral external fixator, shortening and secondary bifocal distraction osteogenesis. In one case nailing after lengthening (NAL) was performed and in the second case nailing had to be performed as fracture treatment 20 years after bony consolidation at the docking site.

Keywords: Knee arthrodesis; Osteoarthritis; Motorcycle accidents

Introduction

In literature, Knee arthrodesis (KA) are described as a salvage procedure for various indications. They are reported after failed total knee arthroplasty (TKA), severe post-traumatic osteoarthritis in young patients, reconstruction after tumor resection, chronic sepsis and totally destroyed knee joints after severe trauma [1-3]. Using this technique the intramedullary nail prevents bending, refracture [4-7], subsidence [8], bowing of the regenerate bone and secondary shortening. Furthermore the time in an external frame is shortened and improves patient's comfort and life quality during the healing phase [9].

The aim of this report is to present our experience with posttraumatic knee arthrodesis after lengthening procedures and discuss complications by presenting two exemplary cases.

Material and Methods

Both cases suffered from severe motorcycle accidents leading to severe bone loss and soft tissue damage around the knee joint. Initially, both patients were treated at our emergency department with damage control surgery. They underwent a limb salvage procedure using an external frame. In both cases leg shortening was performed to close the soft tissue defect (Figures 1-5). After this initial treatment both patients underwent bifocal callus distraction and segmental bone transport to regain lengthening. The first case, with 12 cm of bone reconstruction, consolidated in the external frame. However 20 years after the initial injury the patient sustained a grade 1 open fracture above the former docking site, which was treated initially with an external frame at an outside hospital. As the fracture did not heal, he was transferred to our hospital. After eradicating the infection by surgical debridement, stabilization with an arthrodesis nail was performed (Figure 6).

In the second case, of 26 cm bone loss, the technique "nailing after lengthening" (NAL) was successfully used following bone elongation. The patient sustained a periprosthetic fracture at the distal end of the arthrodesis nail in a further motor vehicle accident (MVA) four years after his initial trauma. As the patient was 191 cm tall a custom made arthrodesis nail had to be manufactured, which took six weeks. Nail exchange surgery was successful and in addition bone graft retrieved from the reamer heads were added at the fracture site to improve fracture healing [10]. X-rays at latest follow-up visit showed bony healing in both cases. The patients were very satisfied with their saved limb.

Discussion

These cases demonstrate successful use of knee arthrodesis nails even in severe trauma cases as a limb salvage procedure. However, these

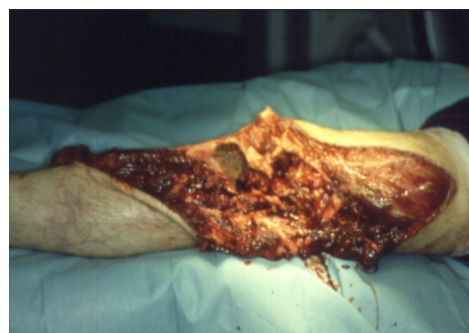

Figure 1: Case 1 - Extensive soft tissue defect on the lower limb with a totally destroyed knee joint after a motorcycle accident.

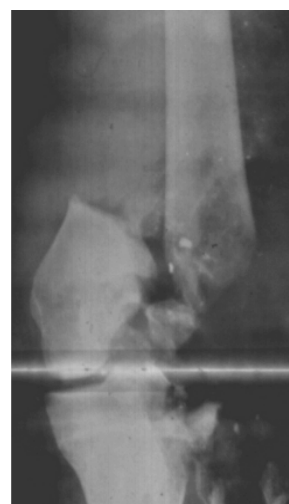


Figure 2: Case 1 - Radiograph of the total destroyed knee joint.

***Corresponding author:** Gerald E. Wozasek, Medical University Vienna, Department of Trauma Surgery, Waehringerguertel 18-20, 1090 Vienna, Austria, Tel: +4314040059020; E-mail: gerald.wozasek@meduniwien.ac.at

Received December 23, 2015; **Accepted** January 18, 2016; **Published** January 21, 2016

Citation: Zak L, Tiefenboeck TM, Wozasek GE (2016) Knee Arthrodesis in Severe Injured Knee Joints. J Trauma Treat 5: 281. doi:[10.4172/2167-1222.1000281](https://doi.org/10.4172/2167-1222.1000281)

Copyright: © 2016 Zak L, et al. This is an open-access article distributed under the terms of the Creative Commons Attribution License, which permits unrestricted use, distribution, and reproduction in any medium, provided the original author and source are credited.

very rare and unique patients require other treatment strategies than in cases of failed knee replacement. Alternative methods to the knee arthrodesis nail are modular nails [11], plating after lengthening [6], external frame fixation or even amputation [6].

In our cases we saw as major complication docking site problems, which were treated successfully by bone grafting. In case 1 docking site problem appeared after secondary fracture and infection. In case 2 there was a delayed consolidation after the NAL procedure. However, comparative studies between open, closed or endoscopic docking procedures did not show any difference in bony healing [12,13]. Biz et al. [14] presented a case series of non unions and re-fractures at the consolidated docking site, treated by intramedullary nailing, achieving union and complete bone healing [14].

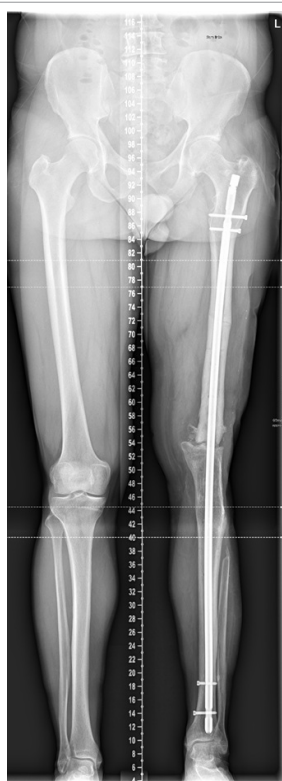

Figure 3: Case 1 – X-ray a.p. views 20 years after initial trauma, knee arthrodesis nail after refracture and infection treatment.

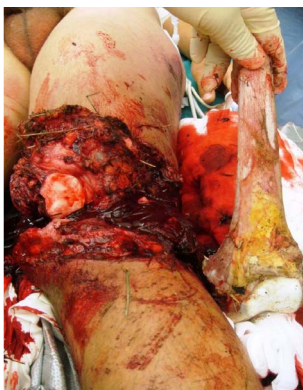

Figure 4: Case 2 – Clinical state at the emergency room with a 26 cm bone defect.

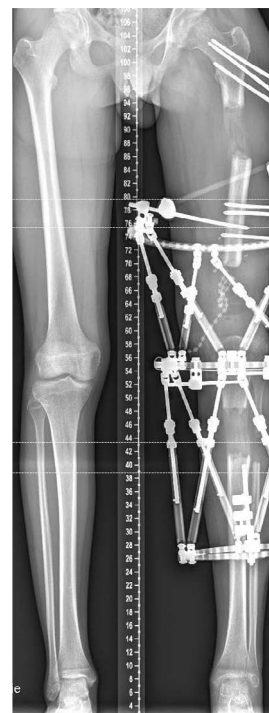

Figure 5: Case 2 – X-ray a.p. views using ring fixation for bifocal callus distraction.

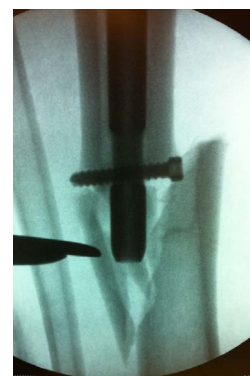

Figure 6: Case 2 – Periprosthetic fracture below the arthrodesis nail after a second MVA.

Kuchinad et al. [6] reported a series of bone lengthening using ring fixation with secondary nailing as a salvage procedure after failed TKA. He recommended a cement coated rod to avoid pin track infection. Furthermore a ten day period between frame removal and intramedullary nailing has been recommended [15] as a safety margin to prevent infection. However, temporary cast application is not possible after bifocal tibial and femoral bone elongation. In a further study “nailing after lengthening” did not increase the risk of infection [9]. In our cases thorough wound management was applied, including antibiotics, antibiotic cement spacers and antibiotic beads. Arthrodesis nail breakage or periprosthetic fractures [16] are most uncommon [17,18]. However, these complications need meticulous treatment either by implantation of a longer nail [7] or even plating [19], depending on the location of fracture and the treated bone. Hinarejos et al. [18] reported periprosthetic fractures above and below a modular knee arthrodesis nail. In one of our cases periprosthetic fracture occurred and was finally treated with a longer arthrodesis nail.

Regarding outcome, long intramedullary nail arthrodesis as a staged arthrodesis is reported to provide a painless functional gait with low complication and reoperation rates after infected TKA [17]. A slight limb shortening is recommended for knee arthrodesis to allow easier foot clearance during walking and to prevent “overlengthening” [3]. This was considered in the pre-surgical planning, during distraction phase, nailing and re-nailing in all of our cases.

Conclusion

Intramedullary knee arthrodesis presents to be an excellent surgical procedure in secondary treatment of large bone defects. It provides good stability, maintains form and axis of the reconstructed limb and allows early weight bearing with a high rate of union. This improves the patient’s comfort and quality of life.

References

1. MacDonald JH, Agarwal S, Lorei MP, Johanson NA, Freiberg AA (2006) Knee arthrodesis. J Am Acad Orthop Surg 14: 154-163.
2. Somayaji HS, Tsaggerides P, Ware HE, Dowd GS (2008) Knee arthrodesis—a review. Knee 15: 247-254.
3. Wood JH, Conway JD (2015) Advanced concepts in knee arthrodesis. World J Orthop 6: 202-210.
4. Guo Q, Zhang T, Zheng Y, Feng S, Ma X, et al. (2012) Tibial lengthening over an intramedullary nail in patients with short stature or leg-length discrepancy: a comparative study. Int Orthop 36: 179-184.
5. Inan M, Halici M, Ayan I, Tuncel M, Karaoglu S (2007) Treatment of type IIIA open fractures of tibial shaft with Ilizarov external fixator versus unreamed tibial nailing. Arch Orthop Trauma Surg 127: 617-623.
6. Kuchinad R, Fourman MS, Fragomen AT, Rozbruch SR (2014) Knee arthrodesis as limb salvage for complex failures of total knee arthroplasty. J Arthroplasty 29: 2150-2155.
7. Wani N, Baba A, Kangoo K, Mir M (2011) Role of early Ilizarov ring fixator in the definitive management of type II, IIIA and IIIB open tibial shaft fractures. Int Orthop 35: 915-923.
8. Song SH, Sinha S, Kim TY, Park YE, Kim SJ, et al. (2011) Analysis of corticalization using the pixel value ratio for fixator removal in tibial lengthening. J Orthop Sci 16: 177-183.
9. Koettstorfer J, Hofbauer M, Wozasek GE (2012) Successful limb salvage using the two-staged technique with internal fixation after osteodistraction in an effort to treat large segmental bone defects in the lower extremity. Arch Orthop Trauma Surg. 132: 1399-1405.
10. Wozasek GE (2015) Limb salvage in a partially amputated distal femur with extensive segmental bone loss using the nailing after lengthening technique: a case report. Strategies in trauma and limb reconstruction. 10: 59-63.
11. Putman S, Kern G, Senneville E, Beltrand E, Migaud H (2013) Knee arthrodesis using a customised modular intramedullary nail in failed infected total knee arthroplasty. Orthop Traumatol Surg Res 99: 391-398.
12. Giotakis N, Narayan B, Nayagam S (2007) Distraction osteogenesis and nonunion of the docking site: is there an ideal treatment option? Injury 38 Suppl 1: S100-107.
13. Lovisetti G, Sala F (2013) Clinical strategies at the docking site of distraction osteogenesis: are open procedures superior to the simple compression of Ilizarov? Injury 44 Suppl 1: S58-62.
14. Biz C, Iacobellis C (2014) Nailing treatment in bone transport complications. Strategies Trauma Limb Reconstr 9: 89-96.
15. Antich-Adrover P, Martí-Garin D, Murias-Alvarez J, Puente-Alonso C (1997) External fixation and secondary intramedullary nailing of open tibial fractures. A randomised, prospective trial. J Bone Joint Surg Br 79: 433-437.
16. Woods JB, Shinabarger AB, Burns PR (2012) Periprosthetic fracture after femoral intramedullary nail use in two cases of tibiototalcanal arthrodesis. J Foot Ankle Surg 51: 266-269.
17. Bargiotas K, Wohlrab D, Sewecke JJ, Lavinge G, Demeo PJ, et al. (2006) Arthrodesis of the knee with a long intramedullary nail following the failure of a total knee arthroplasty as the result of infection. J Bone Joint Surg Am 88: 553-558.
18. Hinarejos P, Ginés A, Monllau JC, Puig L, Cáceres E (2005) Fractures above and below a modular nail for knee arthrodesis. A case report. Knee 12: 231-233.
19. Divecha HM, Marynissen HA (2013) Distal humeral fixation of an intramedullary nail periprosthetic fracture. Case Rep Orthop 690906.