

Klebsiella Meningitis as the Initial Presentation of Macroprolactinoma: A Case Report

Elamir Y* and Grist W

Department of Internal Medicine, Jersey City Medical Center, Jersey City, USA

Abstract

Introduction: Gram negative bacterial meningitis is a rare initial presentation of a macroprolactinoma. Meningitis in these cases is likely caused by a defect in the sellar floor from surgical manipulation or treatment with a dopamine agonist causing rapid shrinkage of a tumor. Patients generally have headaches as the predominant symptom. Our case is an illustration of where meningitis is caused by a transsphenoidal surgery and where meningitis is the presenting symptom to diagnosing a macroprolactinoma.

Case presentation: The patient is a 20-year old African female with history of transsphenoidal surgery over one year ago, who presents with headache associated with subjective fevers, nausea, and vomiting. The patient states that she had similar headaches for the past 2 years but not to this severity. She reports that when she was in her country one year ago she had an unknown surgery through her nose that helped the headaches for a short period of time. She recalls having increasingly irregular periods over the past year and milky discharge from her breasts.

Results: Physical exam was significant for nuchal rigidity. CT scan showed large sellar mass and MRI was consistent with likely pituitary adenoma. The patient's presentation was suspicious for meningitis, so a lumbar puncture was performed, and CSF analysis was consistent with bacterial meningitis. The patient was started on broad spectrum antibiotics until CSF cultures returned showing *Klebsiella pneumoniae* sensitive to ceftriaxone. Further testing showed very high prolactin levels. Endocrinology was consulted and agreed the tumor was a pituitary macroadenoma, most likely a prolactinoma due to her laboratory findings and symptoms of menstrual irregularity and galactorrhea. The patient was treated with Cabergoline 0.5 mg two times per week.

Conclusion: Bacterial meningitis, especially when caused by gram negative organisms is a rare presentation of a pituitary macroprolactinoma. Thorough history taking, and prompt diagnostic evaluation is crucial, especially when medical records cannot be obtained. Treatment of both conditions quickly and simultaneously is important. The case also illustrates that how treating a prolactinoma can result in complications such as meningitis not just immediately after surgery but in any stage of treatment.

Keywords: Prolactinoma; Pituitary disorders; Meningitis

Introduction

Bacterial meningitis, especially gram-negative meningitis, is a rare initial presentation of a macroprolactinoma. Meningitis in these cases are likely caused by a defect in the pituitary sellar floor from surgical manipulation or treatment with a dopamine agonist causing rapid shrinkage of a tumor. Patients generally have headaches as the predominant symptom. Our case is an illustration of where meningitis is caused by a transsphenoidal surgery and where meningitis is the presenting symptom to diagnosing a macroprolactinoma.

Case Presentation

Our patient is a 20-year-old female from Burkina Faso, Africa with a significant past medical history of transsphenoidal surgery over one year ago, who presents with a three-day history of a worsening frontal headache associated with subjective fevers, nausea, and vomiting. The patient states that she had similar headaches for the past two years which had increased in frequency the past six months since arriving in the United States but not to this severity. The patient reports that when she was in her country one year ago she had an unknown surgery through her nose that helped the headaches for a brief period. The patient could not provide any other information about the reason for the surgery or the surgery itself, except that it was for a headache. On further questioning the patient admits to having increasingly irregular periods over the past year and milky discharge from her breasts. On physical exam she was an afebrile, well-nourished looking female in mild painful distress from the headache. She was found to have nuchal rigidity but a negative Kernig/

Brudzinski sign. Computed tomography of the brain was performed that revealed a large sellar mass 5.3 x 4.2 cm.

Due to concern for meningitis a subsequent lumbar puncture was performed which demonstrated markedly increased protein in the CSF 720 mg/dl (normal 15-45), with low glucose <20 mg/dl (normal 40), white blood cell count of 2012 cu/mm (normal 0). Cerebral spinal fluid results were consistent with bacterial meningitis.

Magnetic resonance imaging of the brain revealed a large central skull base mass (0.7x5.6x4.4cm) with remodeling, ossification and/or destruction of bone. The sella was enlarged. Encroachment into paranasal, sphenoid, ethmoid, and left maxillary sinuses was seen. Trapped secretions in the lateral recesses of the sphenoid sinus bilaterally were observed. The enlarged sella itself is in part empty in appearance. Diagnosis was consistent with pituitary macroadenoma. The mass appeared to be contiguous with the left optic nerve (Figures 1 and 2).

The sella itself was enlarged, and partially empty, presumed to be from the patient's previous surgery in Africa. The patient was started

*Corresponding author: Elamir Y, Department of Internal Medicine, Jersey City Medical Center, Jersey City, USA, Tel: 201-316-6564; E-mail: yasmine.elamir@rwjbh.org

Received April 25, 2018; Accepted May 01, 2018; Published May 07, 2018

Citation: Elamir Y, Grist W (2018) Klebsiella Meningitis as the Initial Presentation of Macroprolactinoma: A Case Report. J Clin Case Rep 8: 1111. doi: [10.4172/2165-7920.1000111](https://doi.org/10.4172/2165-7920.1000111)

Copyright: © 2018 Elamir Y, et al. This is an open-access article distributed under the terms of the Creative Commons Attribution License, which permits unrestricted use, distribution, and reproduction in any medium, provided the original author and source are credited.

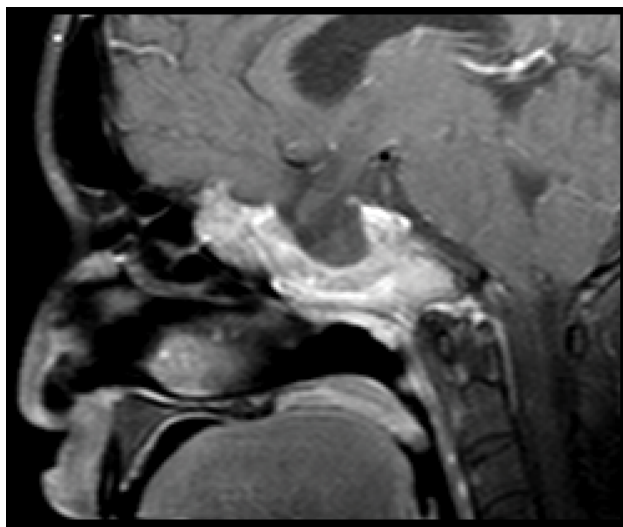


Figure 1: CT scan – Sagittal view.

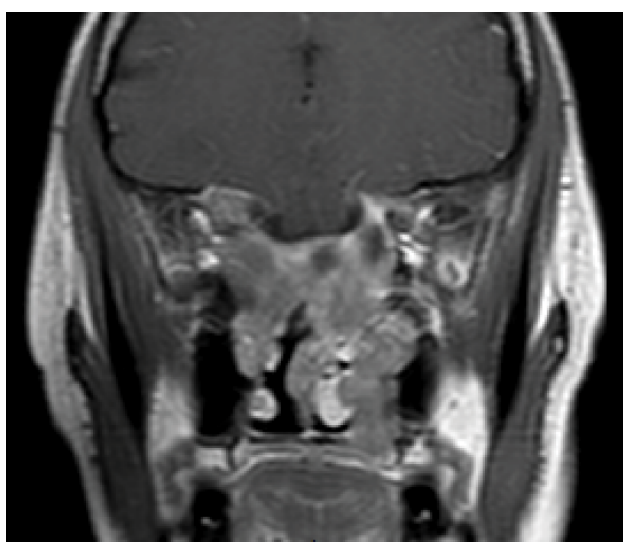


Figure 2: CT scan – Coronal view.

on broad spectrum antibiotics until CSF cultures and blood cultures returned showing *Klebsiella pneumoniae* sensitive to ceftriaxone. A twenty-one-day course of the antibiotic was then started. Hormone profiling revealed prolactin levels of 1897 ng/ml. The rest of the endocrinology workup including thyroid stimulating hormone, follicle stimulating hormone, ACTH, and somatomedin C were within normal. Endocrinology was consulted and agreed the tumor was a pituitary macroadenoma, most likely a prolactinoma due to her laboratory findings and symptoms of menstrual irregularity and galactorrhea. The patient was treated with Cabergoline 0.5 mg two times per week. Patient was discharged but was lost to follow up. The patient's *Klebsiella* meningitis was likely secondary to manipulation of the blood brain barrier during her surgery. The surgery was presumed to be an attempt by her doctor in Africa to remove the prolactinoma.

Discussion

Pituitary macroadenomas represent 10% of all brain tumors.

5% of pituitary macroadenomas become locally invasive by a diffuse destruction of the sellar floor [1] of the 53 isolated cases with spontaneously or medically induced CSF leaks in the setting of pituitary adenoma, 38 (73%) developed CSF rhinorrhea following medical therapy versus spontaneous CSF leakage with no rhinorrhea in 14 (23%) cases. The patient's average age was 42.8 years-old (range 23-68 years-old). Only 8 of these went on to develop meningitis. These cases were either due to nonfunctioning pituitary adenomas, growth hormone secreting adenomas, mammosomatotroph cell adenomas, and ACTH secreting adenomas. Generally, medically induced CSF leakage are dopamine agonists and somatostatin analogs. The time of onset of rhinorrhea is usually within a couple of months but can be as long as 1.5 years as seen in the literature [2].

Macroprolactinomas most commonly present with headache or features of high prolactin including galactorrhea menstrual irregularities in female and impotency in males. Medical treatment with dopaminergic agonists such as bromocriptine and cabergoline are considered first-line treatment for macroprolactinomas compared with other pituitary tumors. Surgery is reserved for patients who do not respond to medical treatment or when there is significant CSF leaking at which point surgical repair of the dural defect is necessary [3].

There are cases in the literature where a macroprolactinoma is complicated by meningitis [1-4]. The most common pathogens were *Streptococcus pneumoniae*, *Neisseria meningitidis* and *Haemophilus influenzae*. This is likely because, as hypothesized by Nutkiewicz et al, when there is a defect in the sellar wall, it generally favors an inferior defect to the sphenoid sinus resulting in a direct route of entry for nasopharyngeal organisms [5]. In addition to our case there have been only 3 cases reported with prolactinoma and meningitis with no rhinorrhea as a sign of CSF leakage [1,3]. Generally, it is caused by some type of sellar defect. Dopamine agonist therapy causes rapid shrinkage of the tumor and can produce a defect. Surgical manipulation, as in our case, can also cause a defect in the sellar floor. These defects predispose to bacterial meningitis. It is important to recognize that the absence of rhinorrhea does not exclude a defect in the skull base [6]. It is also important to recognize that this complication can lead to meningitis. This complication of meningitis can happen as much as 4 years after initial treatment [4]. Finally, although respiratory pathogens are the most common found in these cases, non-respiratory pathogens such as *Klebsiella* meningitis can also be present, as seen in our case.

As far as preventative measures are concerned, when a CSF leak is proven, vaccinations against common respiratory pathogens such as *Streptococcus pneumoniae*, *Herophilus influenzae*, and *Neisseria meningitidis* should be considered. It is feasible to consider using this strategy for those with invasive macroprolactinomas before therapeutics are started. When suspecting meningitis, treatment should be prompt with IV antibiotics after blood cultures are drawn and a lumbar puncture is performed.

Conclusion

Bacterial meningitis, especially when caused by gram negative organisms is a rare presentation of a pituitary macroprolactinoma. Thorough history taking, and prompt diagnostic evaluation is crucial, especially when medical records cannot be obtained. Treatment of both conditions quickly and simultaneously is important. The case also illustrates that *how* treating a prolactinoma can result in complications such as meningitis not just immediately after surgery but in any stage of treatment.

References

1. Robert T, Sajadi A, Uske A, Levivier M, Bloch J (2010) Fulminant meningoencephalitis as the first clinical sign of an invasive pituitary macroadenoma. Case Rep Neurol 2: 133-138.
2. Lam G, Mehta V, Zada G (2012) Spontaneous and medically induced cerebrospinal fluid leakage in the setting of pituitary adenomas: A review of the literature. Neurosurg Focus 32: 2.
3. Margari N, Page S (2014) Bacterial meningitis as a first presentation of pituitary macroprolactinoma. Endocrinol Diabetes Metab Case Rep 2014: 140028.
4. Wood R, Sandeman DD, Gawne-Cain ML, Holt RI (2002) Meningitis four years after treatment of macroprolactinoma. J R Soc Med 95: 501-502.
5. Nutkiewicz A, DeFeo DR, Kohut RI, Fierstein S (1980) Cerebrospinal fluid rhinorrhea as a presentation of pituitary adenoma. Neurosurgery 6: 195-197.
6. Davis JR, Sheppard MC, Heath DA (1990) Giant invasive prolactinoma: A case report and review of nine further cases. Q J Med 74: 227-238.