

Commentary

Open Access

Keratosis Follicularis Spinulosa Decalvans: Diagnosis and Therapeutic Evaluation

Khaled Gharib*, Mohamed Khater, Mohamed Nasr, Mohamed Soliman and Ahmed Abdelshafi

Department of Dermatology, Zagazig University, Egypt

Introduction and Objectives

Keratosis Follicularis Spinulosa Decalvans (KFSD) is an X-linked genodermatosis characterized by scarring alopecia and follicular hyperkeratosis. This condition mainly affects males with females being carriers and will have milder symptoms. We present a family of two siblings of KFSD, boy had nine years and girl had five years old. This genodermatosis often starts at infancy or early childhood. Keratosis pilaris atrophicans (KPA) is the umbrella term for a group of three rare and distinct clinical entities representing the scarring types of keratosis pilaris [1].

Three categories of KPA include: Keratosis pilaris atrophicans faciei (KPAF), Atrophoderma Vermiculatum (AV) and Keratosis Follicularis Spinulosa Decalvans (KFSD). They have the following features in common: keratotic follicular papules, nonpurulent inflammation of variable degree, and atrophic end stages characterized by irreversible hair loss and/or atrophic depressions similar to pitted scars [2].

KFSD simulates the ichthyosis follicularis alopecia photophobia (IFAP) syndrome. The latter is characterized by non-scarring alopecia, extensive keratosis pilaris, severe photophobia and corneal dystrophy. The presence of scarring alopecia in our patients favors the diagnosis of KFSD over the IFAP syndrome. The other follicular conditions that it needs to be differentiated from are lichen planopilaris and lichen spinulosus [3].

Material and Methods

This paper reviews the different aspects of KFSD, including pathogenesis, clinical, histological, differential diagnosis and different therapeutic modalities and their impact on the prognosis of the disease.

Results

A nine year old male and his sister five years old who born from a first-degree consanguineous marriage visited our outpatient department with complaints of rough skin over the scalp and over the body since five years for the boy and two year for the girl in association with total loss of scalp and eyebrow hair in the boy and partial loss in the girl. At birth, their parents noted the absence of scalp and eyebrow hair, which gradually, over the next three to four years grew to some measure and eventually became scanty (Figure 1).

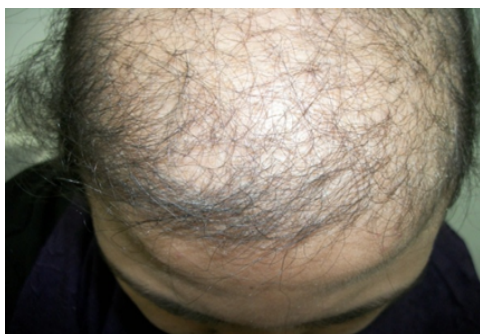

Figure 1: Partial loss in the scalp hair in the girl.

Physical examination disclosed multiple follicular flesh-colored horny papules over the scalp, eyebrows, cheeks and both upper and lower limbs. A closer view of the scalp, cheek and eyebrow revealed fine scaling and areas of scarring alopecia, punctate atrophy, hair loss of eyebrow in the boy and hair loss of the lateral half of eyebrows in the girl. The teeth, nails, palms and soles were found to be normal. The boy had history of photophobia but not in the girl (Figures 2 and 3).

A punch biopsy specimen from the scalp showed follicular plugging in the epidermis with mild acanthosis, early perifollicular fibrosis with mild lymphocytic infiltrate. The dermis was decreased in thickness with ill-formed sebaceous units. The hair shafts appeared to be normal. With all the above findings in hand, a clinical diagnosis of keratosis follicularis spinulosa decalvans was made.

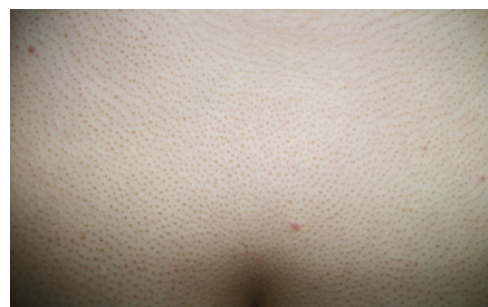


Figure 2: Multiple follicular flesh-colored horny papules in chest.

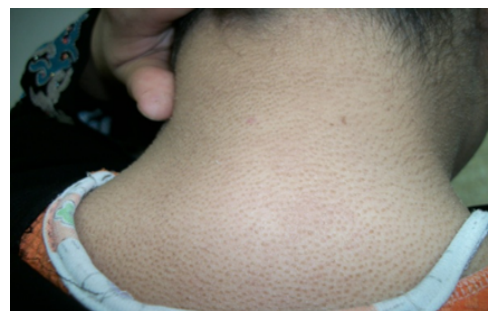

Figure 3: Multiple follicular flesh-colored horny papules in neck.

*Corresponding author: Khaled Gharib, Department of Dermatology, Zagazig University, Egypt, Tel: 44519-57487; E-mail: kh_gharib@hotmail.com

Received April 24, 2015; Accepted May 22, 2015; Published May 25, 2015

Citation: Gharib K, Khater M, Nasr M, Soliman M, Abdelshafi A (2015) Keratosis Follicularis Spinulosa Decalvans: Diagnosis and Therapeutic Evaluation. J Clin Case Rep 5: 532. doi:10.4172/2165-7920.1000532

Copyright: © 2015 Gharib K, et al. This is an open-access article distributed under the terms of the Creative Commons Attribution License, which permits unrestricted use, distribution, and reproduction in any medium, provided the original author and source are credited.

There is no specific treatment for KFSD. Various drugs have been tried to delay scarring alopecia. Our patients were started on oral acetrutin by dose of 1 mg/ kg /day, topical retinoic acid 0.025% on alternate days for the scalp at night and salicylic-steroid lotion during the day. The body was treated with urea and lecithin containing moisturizers. One month later, patient had marked improvement in terms of decreased roughness, increased hair growth and absence of disease progression. They were asked to continue the same systemic and topical medication and come back for review every month. The boy had six sittings of platelet rich plasma subcutaneous injection in scalp areas with appearance of villous hair, the girl continue treatment on topical minoxidil spray which refuses injection.

Discussion

The evaluation of hair loss is a diagnostic challenge to both dermatologist and pathologist. A good clinico-pathological correlation is very much essential. Alopecia can broadly be classified as scarring and non-scarring. KFSD is a rare type of primary scarring alopecia with lymphocyte predominance [4].

KFSD is a rare genetic disorder with X-linked and autosomal dominant pattern of inheritance. The gene has been mapped to Xp21.2-p22.2. Sporadic cases have also been described. In X-linked dominant inheritance pattern, men present with full blown disease, whereas female act as carriers and have milder form of disease. Females with severe form of disease have also been reported [5].

These cases either had autosomal dominant pattern of inheritance and few cases were sporadic in onset. A theory of non-random X inactivation (process of lyonization) was proposed in cases with sporadic onset. In present case report, both brother and sister were affected without any other family members being involved. They may

either have autosomal dominant pattern of inheritance or process of lyonization [6].

So far no effective therapy is known to work for KFSD. Frequent application of topical keratolytic agents and emollients improve skin texture. Antibiotics such as tetracyclines, sulfonamides (dapson), macrolides, penicillins and rifampin have been used at therapeutic doses and found to be ineffective. Topical and intralesional corticosteroids were tried but caused transient improvement. Etreinate and isotretinoin have also been used but with variable results. It is likely that retinoids, which are useful in disorders of keratinization, act by downregulating the process of follicular hyperkeratosis and inflammation. Laser-assisted hair removal with the long-pulse non-Q-switched ruby laser has been found to be useful in progressive or recalcitrant KFSD [7].

References

1. Maheswari UG, Chaitra V, Mohan SS (2013) Keratosis follicularis spinulosa decalvans: a rare cause of scarring alopecia in two young Indian girls. *Int J Trichology* 5: 29-31.
2. Sequeira FF, Jayaseelan E (2011) Keratosis follicularis spinulosa decalvans in a female. *Indian J Dermatol Venereol Leprol* 77: 325-327.
3. Lacarrubba F, Dall'Oglio F, Rossi A, Schwartz RA, Micali G (2007) Familial keratosis follicularis spinulosa decalvans associated with woolly hair. *Int J Dermatol* 46: 840-843.
4. Alfadley A, Al Hawsawi K, Hainau B, Al Aboud K (2002) Two brothers with keratosis follicularis spinulosa decalvans. *J Am Acad Dermatol* 47: S275-278.
5. Porteous ME, Strain L, Logie LJ, Herd RM, Benton EC (1998) Keratosis follicularis spinulosa decalvans: confirmation of linkage to Xp22.13-p22.2. *J Med Genet* 35: 336-337.
6. Bellet JS, Kaplan AL, Selim MA, Olsen EA (2008) Keratosis follicularis spinulosa decalvans in a family. *J Am Acad Dermatol* 58: 499-502.
7. Sellheyer K, Bergfeld WF (2006) Histopathologic evaluation of alopecias. *Am J Dermatopathol* 28: 236-259.