

Inoperable Ovarian Sertoli Cell Tumor in an Elderly Patient, Case Report and Review of Literature

Bedoudou H^{1*}, Abou El Jaoud¹, Mai A², Banani A³, Alaoui Lamrani Y², El-Fatemi H⁴ and Arifi S¹

¹Department of Oncology, University Hospital Hassan II, Fez, Morocco

²Department of Radiology, University Hospital Hassan II, Fez, Morocco

³Department of Gynecology, University Hospital Hassan II, Fez, Morocco

⁴Anatomical Pathology and Cytology Laboratory, University Hospital Hassan II, Fez, Morocco

Abstract

Ovarian sex cord-stromal tumors are a group of rare neoplasms, considered to be low-grade malignant tumors. The Sertoli-Leydig cell tumors subgroup occur mostly in young patients and reveals itself with virilization symptoms. Here we report a rare case of a voluminous well differentiated tumor in a 75-year-old patient with no sign of secretory effects. The radical treatment was impossible, and a palliative chemotherapy was indicated.

Keywords: Sertoli-Leydig cell tumor; Ovary; Virilization; Elderly; Chemotherapy

Introduction

Ovarian sex cord-stromal tumors are a heterogeneous group of neoplasms that develop from the stem cells that would typically furnish cells surrounding the oocytes [1]. They are uncommon benign or malignant tumors, comprising only 0.5% of all ovarian cancers [2]. In contrast with epithelial ovarian cancer, most patients with malignant sex cord-stromal tumors are diagnosed with early-stage disease; the tumors are generally considered to be low-grade malignant neoplasms. Sertoli-Leydig cell tumors constitute less than 0.2 percent of ovarian neoplasms [3]. They may behave in each individual case. Approximately 75 percent of the cases occur in women under the age of 40, but they can occur in all age groups. These neoplasms are characterized by the presence of testicular structures that produce androgens, which can result in virilization.

Case Report

In May 2016, a 73-year-old female was oriented to the gynecology department for the management of an abdomino-pelvic mass growing gradually over many years. It was associated with abdominal pain and an altered general condition. The patient had a history of infertility and reached menopause at the age of 30. A computerized tomography (CT) scan was then performed; it showed a voluminous abdomino-pelvic mass of 21.5 cm × 14.5 cm × 22.5 cm, which was highly vascularised and contained wide liquefaction areas. The mass was compressing the aorta and the inferior vena cava. There were also intra and retroperitoneal lymph nodes. The uterus and the left ovary were of normal appearance. There was no sign of lung or liver metastasis (Figure 1). The patient underwent a biopsy that showed, within a fibrous stroma, a tumorous proliferation arranged in regular tubes and cords (Figure 2). Tumor cells were small, monomorphic, with a scarce eosinophilic cytoplasm, with rounded or oval nuclei (Figure 2). An immunohistochemical study was performed, which revealed that the tumor cells expressed pan cytokeratin antibody E1/AE3 and hormonal receptors (estrogens and progesterone) (Figure 3). They did not however express cytokeratin 7 (CK7) nor cytokeratin 20 (CK20). Inhibin marked some rare cells dispersed within the stroma (Leydig cells) and Vimentin marked the fibrotic tumor stroma. These features are compatible with a well differentiated Sertoli tumor (Figure 3).

At the time of diagnosis, the Eastern Cooperative Oncology Group (ECOG) performance status of the patient was 1 and she had no sign

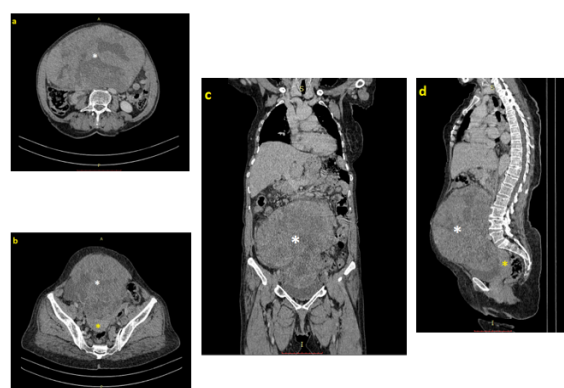


Figure 1: Voluminous abdomino-pelvic mass (white star) repressing other organs (yellow star=uterus) on axial (a; b) coronal (c) and sagittal cut of a CT scan.

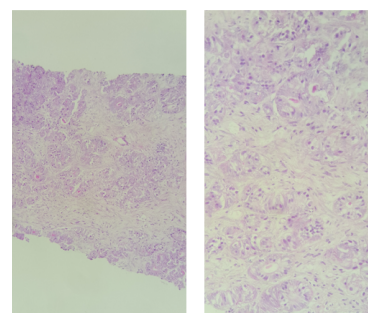


Figure 2: Tumorous proliferation of small cells arranged in regular tubes and cords within fibrous stroma.

***Corresponding author:** Hanae Bedoudou, Department of Oncology, University Hospital Hassan II, Fez, Morocco; Tel: 212535619053; E-mail: hanae.bedoudou@usmba.ac.ma

Received November 22, 2017; **Accepted** January 19, 2018; **Published** January 22, 2018

Citation: Bedoudou H, Jaoud AE, Mai A, Banani A, Alaoui Lamrani Y, et al. (2018) Inoperable Ovarian Sertoli Cell Tumor in an Elderly Patient, Case Report and Review of Literature. J Cancer Sci Ther 10: 008-010. doi:[10.4172/1948-5956.1000507](https://doi.org/10.4172/1948-5956.1000507)

Copyright: © 2018 Bedoudou H, et al. This is an open-access article distributed under the terms of the Creative Commons Attribution License, which permits unrestricted use, distribution, and reproduction in any medium, provided the original author and source are credited.

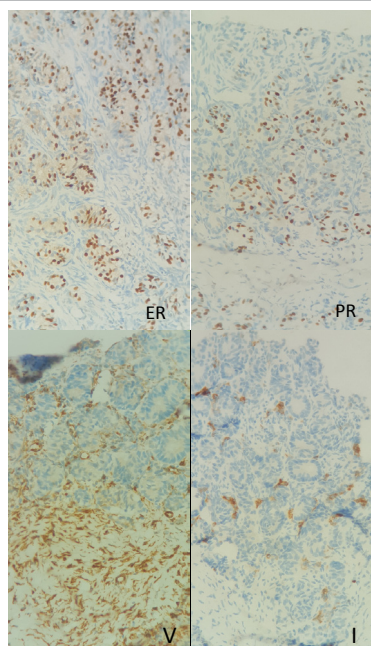


Figure 3: Expression of estrogens receptors (ER), progesterone receptors (PR), inhibin (I) and vimentin (V) on immunohistochemical staining.

of hyperandrogenism. The biological parameters showed that germinal tumor markers were within normal limits (Alpha fetoprotein AFP 2.49 ng/mL; Human chorionic gonadotropin HCG 1.51 mU/mL), however, the testosterone and CA 125 were respectively at: 2.68 ng/mL and 51 IU/mL, which is slightly elevated. According to recommendation of palliative care for ovarian sex cord-stromal tumors (NCCN guideline for less common ovarian histopathologies, version 2.2017), the patient was commenced on carboplatine-paclitaxel. After four cycles, the patient had clinical improvement and a radiological stable disease. The chemotherapy was therefore continued for four other cycles. At the end of treatment, the mass was still relatively stable at 20 cm × 15 cm × 21 cm but still inoperable. The patient had a clear clinical benefit. The laboratory tests showed CA 125 at 42.5 IU/mL and testosterone levels at 2.69 ng/mL. After 4 months of surveillance, the patient is still in good condition with no sign of malignant progression.

Discussion

Epidemiology

Sertoli and Leydig cell tumors account for 25% of endocrine tumors in the ovary. They are rare with a prevalence of 0.2% of all ovarian cancers [2]. Family forms of these types of tumors have been described [4].

Histology

These tumors derive from the mesenchyme and the sexual cords that bring together all the phases of the embryonic development of the testicle, from the undifferentiated diffuse and cordonal stromal aspect to the well differentiated sertoli tube [1]. Depending on the variable proportions of Sertolian and Leydigian elements, these tumors are classified into 3 groups: well-differentiated benign forms which are secretory in 60%, intermediate differentiation (immature sertoli cells) and undifferentiated, sarcomatoid or retiniform [1]. The bilateral and synchronous involvement of the two ovaries is rare [5].

Diagnosis

Clinically, the mean age of onset is around 25 years [2,5] which contrasts with our case. Symptoms are not specific. This may include a tumor syndrome, pelvic pain, or a secondary amenorrhea-like disorder. Signs of virilization such as hirsutism, voice hoarseness, clitoral hypertrophy, defeminization of the silhouette and changes in psycho-sexual behavior can be found in 30 to 50% of cases. In addition to the classical signs mentioned above, some patients in the prepubertal period may exhibit manifestations of hyper-estrogenism such as premature iso-sexual puberty or menorrhagia. The explanation for this hyper-estrogenism is a transformation of the androsterone produced by the tumor cells into estradiol [5-7]. Our patient had a history of infertility and early menopause with no sign of virilisation at the time of diagnosis, her case belongs to the group of 40% well-differentiated non-secretory tumors. At the time of diagnosis, we could not determine whether the early menopause is a causal factor or reveals a slow tumor growth. On ultrasound, Sertoli-Leydig cell tumors appear to be heterogeneous vascularized masses with solid zones; in the pure Sertoli cell forms, they are multilocular, associated with anechoic liquid zones. Their size can achieve up to about 20 cm [8]. In our case, the patient neglected the enlargement of the abdomen over the years, the tumor reached 22 cm in the major axis. The hormonal balance depends on the symptomatology. In the presence of signs of virilization, it is appropriate to dose the major androgenic hormones in women: testosterone, delta-4-androstenedione, dehydroepiandrosterone, dehydroepiandrosterone sulphate. In general, only androgens of ovarian origin are elevated. In the presence of amenorrhoea, the androgen dosage will be coupled with FSH, LH and Prolactin. However, it is not necessary to have exhaustive hormonal tests in case of an isolated tumor syndrome [5-7]. Other markers have been proposed by some authors in the context of biological monitoring, namely alpha fetoprotein, inhibin A and inhibin B [9]. The histological examination confirms the diagnosis and allows to classify the tumors according to the varying proportions of the Sertoleian and Leydigian elements and their degree of differentiation. Well-differentiated tumors are those with pure Sertoli cells which have the appearance of the prepubescent testis, pure Leydig cells that develop at the hilum, and mixed tumors, composed of Sertoli cells separated by clusters of Leydig cells. The intermediate differentiated tumors contain immature Sertoli tubes and a stroma of Leydig cell in a minor proportion. The slightly differentiated forms are composed of fusiform, pseudo-sarcomatous or retiniform cells, evoking the rete testis. It should be noted that heterologous elements can be found in the latter two forms (bone tissue, cartilage, gastrointestinal epithelium, hepatocytes) [5,9,10].

Treatment

Curative treatment is mainly based on surgery and takes into account prognostic factors such as tumor volume, tumor differentiation, capsular integrity and the importance of mitoses. It should be optimal and the least mutilating. Adenectomy or unilateral ovariectomy is possible in young women of childbearing age who desire pregnancy. If conservative treatment is considered, peritoneal staging should be combined with biopsies on suspect lesions. In the absence of any desire of pregnancy, and in case of undifferentiated forms, the treatment should be radical with a non-conservative hysterectomy associated with an omentectomy [5]. Node dissection has not yet proven its pertinence. Adjuvant chemotherapy, if required, is modeled on that of malignant germ cell tumors with poor prognosis. It uses bleomycin, etoposide and cisplatin (BEP). Currently taxanes have demonstrated their efficacy with less toxicity than BEP. The association cisplatin

and taxanes could be interesting in the future [5]. The surgery could not be done in our case, the management of the disease consisted on a palliative care. Some publications report a radiosensitivity of these tumors, but at the price of a much higher toxicity than chemotherapy [4]. Palliative treatment Management of recurrent or metastatic disease- overt metastatic disease is treated with chemotherapy. As with granulosa cell tumors, the optimal regimen for treatment of advanced Sertoli-Leydig cell tumors is unknown. However, BEP is recommended most often. As with other advanced sex cord-stromal tumors, the rate of objective response is high, but responses are not durable. Other platinum-based regimens can be used as alternatives, particularly for second-line therapy. These include cyclophosphamide, doxorubicin, plus cisplatin (CAP); carboplatin, epirubicin, plus etoposide; cisplatin, vinblastine, plus bleomycin; and taxane/platinum combination therapy [11-17]. The Gynecologic Oncology Group is currently conducting a randomized phase II trial of BEP versus the combination of paclitaxel and carboplatin for patients with newly diagnosed and chemo-naïve recurrent metastatic sex cord-stromal tumors of the ovary [18]. Due to the age of our patient, the carboplatine paclitaxel doublet was justified.

Prognosis and follow up

The overall five-year survival is 70 to 90 percent and is related to the stage and the degree of histologic differentiation. In one large series of 207 patients with Sertoli-Leydig cell tumors, the level of differentiation was well, intermediate, and poor in 11, 54, and 13 percent, respectively, and 22 percent contained heterologous elements [19]. With prolonged follow-up, the tumor was clinically malignant (i.e., it recurred and/or metastasized) in 18 percent of patients. All of the well-differentiated tumors were benign, while malignant behavior occurred in 11 percent of those with intermediate differentiation, 59 percent of poorly differentiated tumors, and 19 percent of those with heterologous elements. The follow-up is clinical, biological (testosterone levels or other markers, such as inhibin, estradiol, or alpha-fetoprotein, if initially elevated) and radiological, especially after conservative treatment. The rare tumor observatory recommends follow-up every three months in the first two years, a clinical and biological follow-up every six months, and a radiological examination every year from the third to the fifth year and then annually.

Conclusion

Non-epithelial tumors of the ovary derived from mesenchyme and sexual cords are rare, those with Sertoli-Leydig cells are the most common. The signs of virilization of ovarian origin particular to these neoplasms, although not all of them are functionally active. The combination chemotherapy of platinum and taxanes is an interesting therapeutic option. The non-operable tumors can be controlled by paclitaxel- carboplatine in elderly patients.

References

1. Tavassoli FA, Mooney E, Gersell DJ (2003) Sertoli-leydig cell tumours. In: Tavassoli FA, Devilee P, (eds). World Health Organisation Classification of IARC Press.
2. Colombo N, Parma G, Zanagnolo V (2007) Managment of ovarian stromal cell tumors. *J Clin Oncol* 25: 2944-2951.
3. DiSaia PJ, Creasman WT (1997) Germ cell, stromal and other ovarian tumors. In: *Clinical Gynecologic Oncology*, Mosby-Yearbook 351.
4. Samant R, Fung MF, Le T, Hopkins L (2006) Palliative radiotherapy for recurrent granulosa cell tumor of the ovary: a report of 3 cases with radiological evidence of response. *GynecolOncol* 102: 406-410.
5. Litta P, Saccardi C, Conte L, Codroma A, Angioni S, et al (2013) Sertoli-Leydig cell tumors: Current status of surgical management: Literature review and proposal of treatment. *Gynecol Endocrinol* 29: 412-417.
6. Zavagnolo V, Pasinetti B, Sartori E (2004) Clinical review of 63 cases of sex cord stromal tumors. *Eur J Gynaecol Oncol* 25: 431-438.
7. Oliva E, Alvarez T, Young RH (2005) Sertoli cell tumors of the ovary: A clinicopathologic and immunohistochemical study of 54 cases. *Am J Surg Pathol* 29: 143-156.
8. Demidov VN, Lipatenkova J, Vikhareva O, Van Holsbeke C, Timmerman D, et al. (2008) Imaging of gynecological disease: Clinical and ultrasound characteristics of sertoli cell tumors, sertoli-leydig cell tumors and leydig cell tumors. *Ultrasound Obstet Gynecol* 31: 85-91.
9. Roger V, Cravello L (2004) Tumeurs endocrines de l'ovaire: tumeurs de Sertoli-Leydig et tumeur de la granulosa. *La lettre du gynécologue* 289: 18-22.
10. Stacher E, Pristauz G, Scholz HS, Moinfar F (2010) Bilateral ovarian well differentiated Sertoli-Leydig cell tumors with heterologous elements associated with unilateral serous cystadenoma - a case report. *Int J Gynecol Pathol* 29: 419-422.
11. Homesley HD, Bundy BN, Hurteau JA, Roth LM (1999) Bleomycin, etoposide, and cisplatin combination therapy of ovarian granulosa cell tumors and other stromal malignancies: A Gynecologic Oncology Group study. *Gynecol Oncol* 72: 131-137.
12. Gershenson DM, Morris M, Burke TW, Levenback C, Matthews CM, et al. (1996) Treatment of poor-prognosis sex cord-stromal tumors of the ovary with the combination of bleomycin, etoposide, and cisplatin. *Obstet Gynecol* 87: 527-531.
13. Gershenson DM, Copeland LJ, Kavanagh JJ, Stringer CA, Saul PB, et al. (1987) Treatment of metastatic stromal tumors of the ovary with cisplatin, doxorubicin, and cyclophosphamide. *Obstet Gynecol* 70: 765-769.
14. Tomlinson MW, Treadwell MC, Deppe G (1997) Platinum based chemotherapy to treat recurrent Sertoli-Leydig cell ovarian carcinoma during pregnancy. *Eur J Gynaecol Oncol* 8: 44.
15. Fujimoto A, Saitou M, Ishihara O, Takeda S, Kinoshita K, et al. (1995) A case of ovarian malignant Sertoli-Leidig cell tumor treated with CBDCA, etoposide and epirubicin chemotherapy. *Gan To Kagaku Ryoho* 22: 1843-1846.
16. van der Meer J, de Vries EG, Vriesendorp R, Willemse PH, Donker AJ, et al. (1985) Hemolytic uremic syndrome in a patient on cis-platinum, vinblastine and bleomycin. *J Cancer Res Clin Oncol* 110: 119-122.
17. Brown J, Shvartsman HS, Deavers MT, Burke TW, Munsell MF, et al. (2004) The activity of taxanes in the treatment of sex cord-stromal ovarian tumors. *J Clin Oncol* 22: 3517-3523.
18. Gynecologic Oncology Group (2010) Paclitaxel and carboplatin or bleomycin sulfate, etoposide phosphate, and cisplatin in treating patients with advanced or recurrent sex cord-ovarian stromal tumors. *ClinicalTrials.gov Identifier: NCT01042522*
19. Young RH, Scully RE (1985) Ovarian Sertoli-Leydig cell tumors. A clinicopathological analysis of 207 cases. *Am J Surg Pathol* 9: 543-569.