

IMRT for Nasal Tumors – Local Control and Cosmetic Outcome

Stefan Janssen¹, Christoph Glanzmann¹, David Holzmann² and Gabriela Studer^{1*}

¹Department of Radiation Oncology, University Hospital Zurich, Zurich, Switzerland

²Department of Otorhinolaryngology, Head and Neck Surgery, University Hospital Zurich, Zurich, Switzerland

*Corresponding author: Studer G, Department of Radiation Oncology, University Hospital Zurich, Zurich, Switzerland, Tel: +1 44 255 29 30; E-mail: gabriela.studer@usz.ch

Received date: Feb 28, 2014, Accepted date: April 04, 2014, Publication date: April 15, 2014

Copyright: © 2014 Janssen S, et al. This is an open-access article distributed under the terms of the Creative Commons Attribution License, which permits unrestricted use, distribution, and reproduction in any medium, provided the original author and source are credited.

Abstract

Background: To evaluate local control and cosmetic outcome in patients with cancer in the nasal cavity/vestibule treated with intensity-modulated radiotherapy (IMRT).

Methods: From 06/2008 – 11/2012 15 consecutive patients presenting nasal cavity (n=5), ala of the nose (n=5) or nasal vestibule tumors (n=5) were treated in our institution either postoperatively (n=8) or as definitive treatment (n=7).

Results: Mean/median follow-up (FU) was 30/22 months (range 17-62). Two patients suffered from a local relapse. As a salvage therapy an ablatio nasi was carried out in curative intention in both patients. Thereafter no failure was reported. Local control rate, ultimate local control and overall survival after 2 years were 87%, 100% and 100%, respectively. None of the patients developed grade II or higher late sequels. Cosmetic outcome after RT was very satisfying so far.

Conclusion: IMRT for nasal tumors is effective and well tolerated. Radical surgical procedures can be saved for curative salvage treatment.

Keywords: Nasal tumors; IMRT; SIB-IMRT; Definitive radiotherapy; Cosmetic outcome

Introduction

Tumors of the nasal cavity or of the nasal vestibule are rare [1]. Optimal treatment depends on tumor size, tumor expansion and nodal status and includes definitive or postoperative radiotherapy, or surgery alone. Surgical removal often implies complex reconstruction which may end in disfiguring results and consecutively essential impairment of quality of life. Radiation therapy (RT) can be carried out as external beam or brachytherapy, with good local control rates of 67-92% after 5 years [2-6].

Recently, few single center study groups presented retrospective data on treating patients with sinonasal cancer with intensity modulated radiotherapy (IMRT). They revealed excellent local control rates with minimized toxicity [7-12]. In those series only a minority of included patients were diagnosed with nasal cavity or nasal vestibule tumors. Cosmetic outcomes were therefore not evaluated.

The goal of the present study was to show effectiveness of IMRT in a single center series of a homogeneous patient collective with nasal tumors in terms of local control and cosmetic outcome.

Patients and Methods

From 06/2008 to 11/2012 15 consecutive patients presenting with histologically proven squamous cell cancer (SCC, n=13) or adenocarcinoma (n=2) were treated in our institution with IMRT

either postoperatively after tumor excision (n=8) or as definitive treatment (n=7).

Patient and treatment parameters are summarized in Table 1. One patient had ipsilateral lymph node metastases (N1). In this case a neck dissection was carried out prior to IMRT.

The dose was normalized to the mean dose in planning target volume (PTV) 1. For intensity optimization, the prescribed dose encompassed at least 95% of the PTV. Simultaneously integrated boost (SIB) was used delivering two-three different dose levels in the same treatment session.

Target volumes were delineated as follows: GTV included the gross extent of primary disease, taking clinical and radiological findings into account; PTV1 was defined by adding 10-15 mm margin to the GTV, dependent on the GTV proximity to critical structures eye, optical nerve); PTV2 covered areas considered at high risk for potential microscopic disease. No elective lymph node irradiation was carried out. Mean GTV volume was 12.4 ccm (range: 2.9-27.9 ccm).

Mean age (years)	58 (range: 28-78)
Gender	
Male	12 (80%)
Female	3 (20%)
RT sequence	
Postoperative IMRT	8 (54%)

Definitive IMRT	7 (46%)
Histology	
SCC	13 (87%)
adenocarcinoma	2 (13%)
Location	
nasal cavity	5 (33.3%)
vestibule	5 (33.3%)
ala of the nose	5 (33.3%)
RT doses (5 fractions/week)	
35x2=70 Gy	6 (40%)
34x2=68Gy	2 (13%)
33x2=66 Gy	5 (33%)
32x2=64 Gy	1 (7%)
31x2=62Gy	1 (7%)
TN-status	
T1	2 (13%)
T2	10 (66%)
T3	1 (7%)
T4	2 (13%)
N1	1
N2	0
N3	0
N4	0
Cisplatin or cetuximab concomitant	8 (54%)

Table 1: Patient and treatment related characteristics.

Mean dose to the left and right lacrimal glands was 2.9 Gy (range: 0.5-9.3 Gy), and 2.6 Gy (range: 0.5-7 Gy). The maximal lens dose was 6.6 Gy (range: 3.7-11.6 Gy) and 6.5 Gy (range: 1.9-13.3 Gy) on the right and left side, respectively. Dose to the lacrimal sac/proximal nasolacrimal duct was estimated and summed up to a mean value of 25 Gy (range: 3-58) on the right side and 29 Gy (range: 2-56) on the left.

To ensure sufficient dose delivery to the skin close to GTVs, bolus material (0.5.1 cm thickness) was used in all patients (Figure 2-7). Nasal tamponade was used in all patients, to reduce/avoid build up effect. Irradiation was delivered with three to seven coplanar beam angles by a 6-MV dynamic MLC system (Varian Medical Systems, Palo Alto, CA) using sliding window technique, or using volumetric modulated arc technique (VMAT, since 04/2010). Patients were immobilized from head to shoulders using a commercially available thermoplastic mask in supine position.

Regular FU visits were carried out in our joint clinic at the Department of Otorhinolaryngology, Head and Neck Surgery. Institutional standards for patient assessment included physical examination approximately every 2 months in the first year of follow-up, every three months in the second to third year and every 6 months in the fourth to fifth year. Last FU and grading of toxicity (CTCAE grading system) was performed personally or by phone calling (S) or GS in 08-09/13).

Systemic Therapy

Systemic therapy preferably consisted of cisplatin (40 mg/m² weekly) and was switched to cetuximab in case of cisplatin related adverse effects (cetuximab loading dose: 400 mg/m² followed by weekly applications of 250 mg/m² referring to Bonner et al. [13]). For patients with contraindications against cisplatin, cetuximab was favored primarily. The indication for systemic therapy was based on tumor stage, resection status, age and Karnofsky performance score. 8 patients presenting with T4 tumors, N1 or R1 resection received systemic therapy. Cisplatin was started in 6 patients, a switch to cetuximab was carried out in four patients after 2 (n=3) and 4 (n=1) courses due to tinnitus (n=3) or rising levels of creatinine (n=1). In two patients with contraindications against cisplatin, cetuximab was preferred as first choice.

Statistics

Statistical calculation was performed using the statistic program implemented in Stat View (Version 4.5; SAS Institute, Cary, NC).

Results

Outcome

Mean/median FU was 30/22 months (range 17-62). Median local control, ultimate local control and overall survival after 2 years was 87% (Figure 1), 100% and 100%, respectively. Two patients developed a loco-regional relapse after 6 and 10 months, respectively. One of those patients was treated with definitive RT; one had an excision before RT. Ablatio nasi was carried out in both cases as successful salvage therapy revealing no recurrence up to now 7 and 26 months later, respectively.

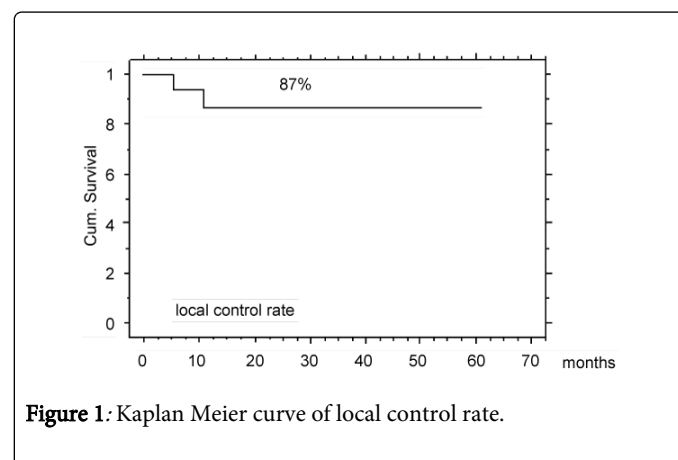


Figure 1: Kaplan Meier curve of local control rate.

Late term effects

No grade II or higher late sequels were seen during the FU time so far. 12/13 organ preserved tumor free patients suffered from a mild to moderate dryness of the nasal mucosa which was tolerable under symptomatic therapy (Table 3). One patient described a repetitive grade 2 epistaxis, one patient a grade 1 epistaxis. In consequence to the low doses to the lacrimal glands and lenses mentioned in the methods section no severe late adverse effect concerning the lacrimal glands or vision is expected. No nasolacrimal stenosis occurred in any patient.

Cosmetic results

At the time of last visit each patient was asked to evaluate the cosmetic results of RT using a scale from 1-5 in which 1 would stand for no satisfaction with respect to cosmetic outcome and 5 for high satisfaction with the cosmetic outcome comparable with status before initial diagnosis and treatment. Patients rated cosmetic outcome either as excellent (grade 5, 9/13) or as good (grade 4, 4/13). Table 2 summarizes the results for each patient. In Figures 2-7 exemplary photographs demonstrate objective outcome related to the isodose plans of patients who underwent definitive IMRT.

	RT sequence	T stage	Tumor site	RT dose	Patients' satisfaction with cosmesis *	Late sequels
1	definitive	2	ala	70	ablatio	dry nasal mucosa grade I
2	definitive	2	vestibule	70	5	none
3	definitive	2	nasal cavity	70	5	Intermittent epistaxis, dry nasal mucosa grade I
4	definitive	4	vestibule	68	5	dry nasal mucosa grade I
5	definitive	2	nasal cavity	68	5	dry nasal mucosa grade I
6	definitive	2	ala	70	5	dry nasal mucosa grade I
7	definitive	2	nasal cavity	70	4	dry nasal mucosa grade I
8	postoperative	4	vestibule	66	ablatio	dry nasal mucosa grade I
9	postoperative	1	ala	66	5	dry nasal mucosa grade I
10	postoperative	2	nasal cavity	66	5	dry nasal mucosa grade I
11	postoperative	3	vestibule	62	5	dry nasal mucosa grade I, intermittent epistaxis
12	postoperative	2	ala	66	4	slightly olfactory impairment, dry nasal mucosa grade I
13	postoperative	2	ala	66	4	dry nasal mucosa grade I
14	postoperative	2	nasal cavity	64	5	dry nasal mucosa grade I
15	postoperative	1	vestibule	70	4	dry nasal mucosa grade I

Table 2: Summary of cosmetic outcome and late sequels for each patient (CTCAE grade 1=asymptomatic mucosal crusting, grade 2: interfering with airflow, grade 3: significant nasal obstruction)*Cosmetic outcome in self-assessment using a 5 point scale (“1”=poor cosmetic outcome, “5”=very satisfying).

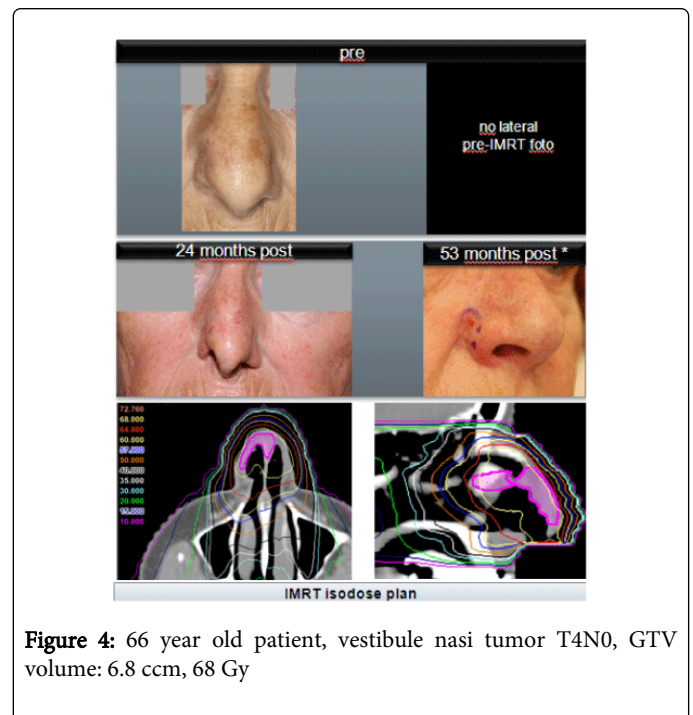
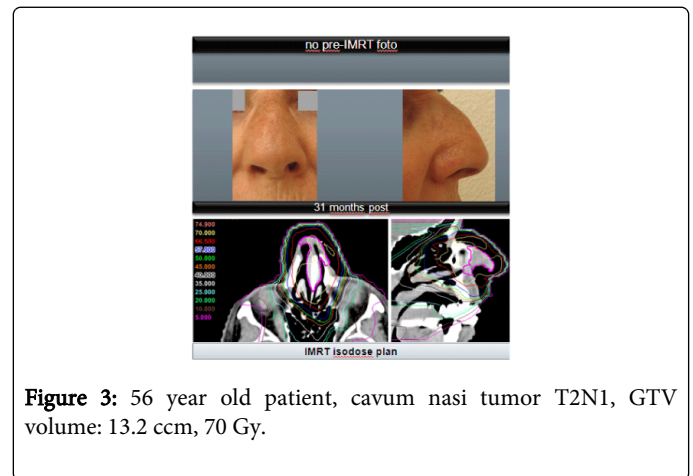
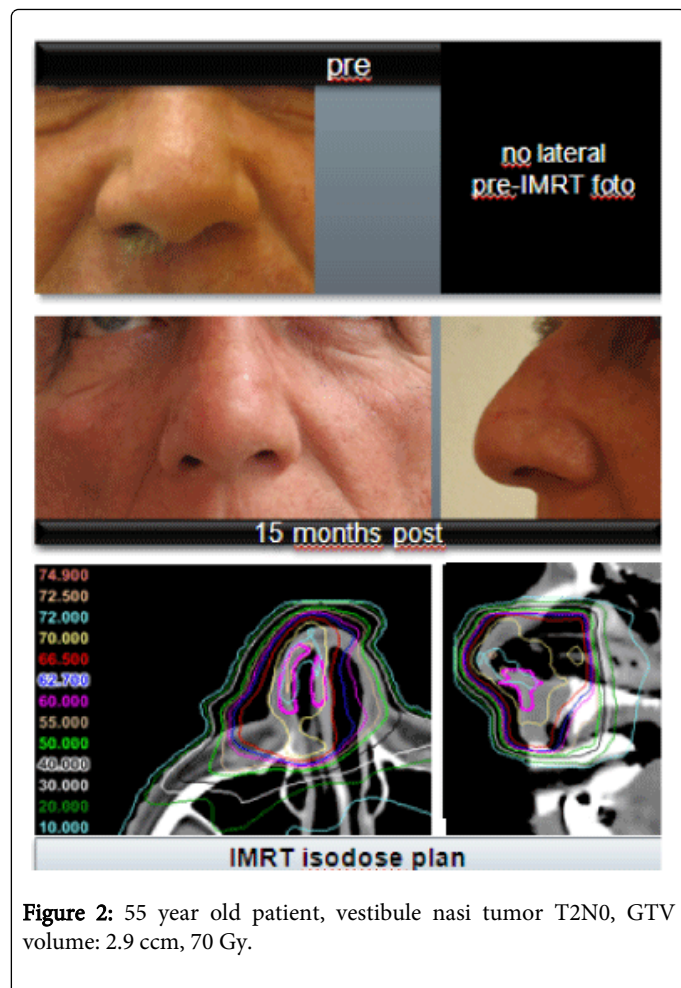
	Patients (n)	Nasal tumors (%)	Definitive RT (%)	RT technique	RT dose (Gy) (Dose/fraction)	CTx (%)	LC (%)	OS (%)	Cosmetic results
Katz et al. [14]	78	62	60	Anterior and lateral fields	68 (1.8 or 1.2 twice daily)	1	60 (5yrs)	50 (5yrs)	n.a.
Langendijk et al. [4]	56	100	100	Opposed lateral 6MV fields +/- BT boost	67.5 (2.5)	0	80 (2yrs)	66 (2yrs)	n.a.
Levendag et al. [6]	64	100	78	BT	44 (3 twice daily)	0	92 (5yrs)	59 (5yrs)	65% excellent or good results (n=23)
Wallace et al. [2]	71	100	89	Anterior field MV elektrons and 6MV,	65-75	3	87 (5yrs)	76(5yrs)	n.a.for def. treatment, poor for 6 patients

				BT					and good for 2 patients treated with surgery and RT
Agger et al. [14]	174	100	69	Opposed lateral fields 250KV or MV	54 (3) 62-66 (2)	0	67 (5yrs)	50 (5yrs)	n.a.
Total	443	92	79			1	77	60	

Table 3: Summary of studies on conventionally treated patients with nasal cancer published in the IMRT era (not treated with IMRT). BT: Brachytherapy; n.a.: not assessed

Systemic therapy

No late sequels were observed concerning systemic therapy.



Discussion

We evaluated clinical outcome and early cosmetic results in a patient group presenting with exclusively nasal tumors treated with IMRT.

In historic series on cohorts treating nasal vestibule tumors with conventional RT or brachytherapy, local control and overall survival rates range from 67% to 92% and 50% to 90%, respectively [2,4,6,14]. The largest series of the DAHANCA study group including 174 patients with nasal vestibule cancer reports a local control rate and an overall survival rate of 67% and 50% at 5 years, respectively [14] (Table 3). In the latter series RT was delivered in opposed lateral fields (KV or MV) or with an anterior electron field +/- brachytherapy boost. Doses range from 54 Gy in 3 Gy single doses to 62-69 Gy in 2 Gy or 2.5 Gy doses [2,4,14]. Langendijk et al. observed rhinorrhoea in 45%, nasal dryness in 39% and epistaxis in 15% of the patients as late toxicity (4). Radiation induced necrosis of the skin was seen in 3 patients. Wallace et al. showed severe late term complications requiring hospitalization and/or surgical intervention in 3 out of 8 postoperatively treated patients. 21% of patients treated with RT only experienced complications which resolved without intervention [2].

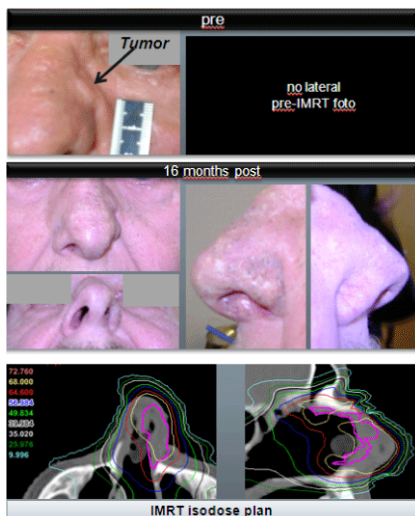


Figure 5: 67 year old patient, cavum nasi tumor T2N0, GTV volume: 9.5 ccm, 68G y

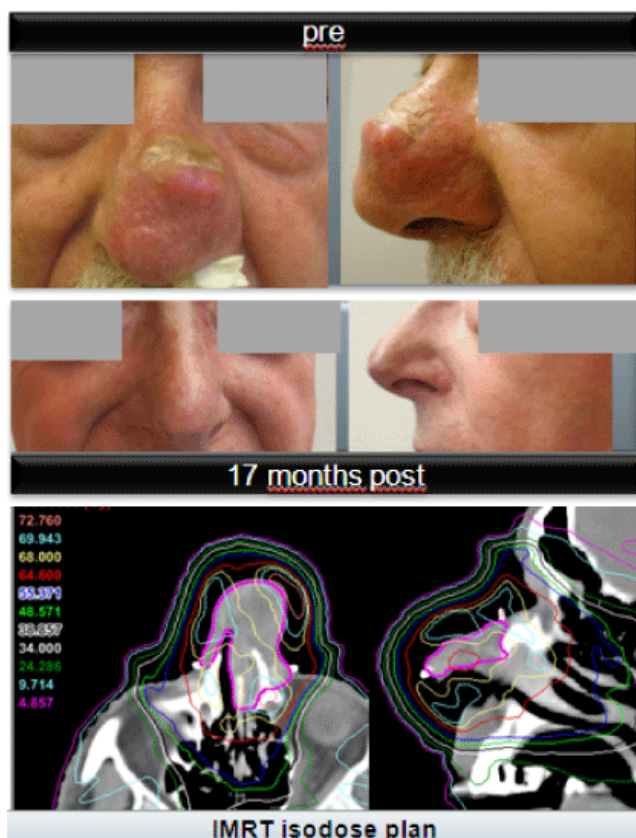


Figure 6: 69 year old patient, ala nasi tumor T2N0, GTV volume: 27.9 ccm, 70 Gy.

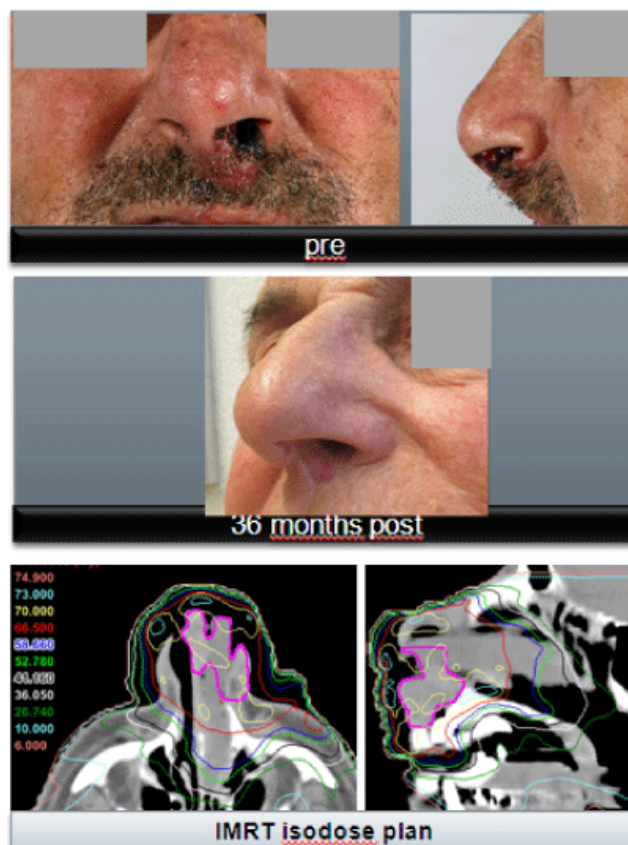


Figure 7: 78 year old patient, vestibule nasi tumor T2N0, GTV volume: 20.2 ccm, 70 Gy.

IMRT is effective to deliver high doses to target volumes while limiting the dose to adjacent critical structures [12]. We found 7 other

single center retrospective studies reporting comparable local control (49-87%) and overall survival data of 45-100% at 2-5 years with low rate of toxicity in patients with sinunasal cancer [7-12,15]. Most IMRT series did not observe any grade 3 visual impairment [8-11]. In contrast to the above mentioned series with conventional RT techniques, those IMRT series included mostly paranasal cavity tumors with different histologies ranging from SCC to esthesioneuroblastoma, adenoidcystic carcinoma and sarcomas. Only a small number of patients with nasal cavity/nasal vestibule tumors were included (Table 4). No published IMRT series evaluating patients with nasal cancer exclusively could be found.

Furthermore most of the patients were treated postoperatively. Definitive treatment was carried out in only 9% - 21% in the collectives of Wiegner, Duprez and Madani, respectively while other reports assessed series with only postoperatively treated patients [9-11].

In contrast we had half the cases treated with definitive IMRT. Our results of local control and overall survival are comparable with the

large series of conventional treated patients as well as the heterogeneous group treated with IMRT. For our small sample size, disease control was identical for postoperative and definitive IMRT. Cosmetic outcomes were not evaluated in any of the other IMRT studies. Wallace et al. treating nasal vestibule cancer patients with conventional RT only report of “poor” cosmetic results in 6 patients and “good” cosmetic results in 2 patients treated with surgery and RT [2]. Levendag et al. evaluated cosmetic outcome consequently in patients with early-stage nasal vestibule cancer treated with brachytherapy. They scored cosmetic results using a 3 point scale. 65% showed good or excellent objective results judged by an external panel [6]. We used a five point scale in order to further differentiate outcome. Furthermore, we did not assemble an external panel to evaluate cosmetic outcome; cosmetic results as presenting at last visit of the patients treated with 70Gy are shown in Figure 2. Altogether cosmetic outcome is very satisfying with only grade 4 and 5 in self-assessment standing for good and excellent outcomes.

	Patients with sinunasal tumors (n)	Nasal tumors (%)	Definitive RT (%)	RT technique	RT dose (Dose/fraction) (Gy)	CTx (%)	LC (%)	OS (%)	Cosmetic results
Combs et al. [9]	46	16/46 (35)	0	IMRT	64 (2)	0	49 (3yrs)	90 (3yrs)	n.a.
Daly et al. [10]	36	7/36 (19)	0	IMRT	70 (2.12)	17	58 (5yrs)	45 (5yrs)	n.a.
Hoppe et al. [15]	85	24/85 (28)	0	IMRT in 35%	50-70 (1.8-2)	2	87 (5yrs)	67 (5yrs)	n.a.
Madani et al. [7]	84	16/84 (19)	11	IMRT	70 (2)	0	71 (5yrs)	59 (5yrs)	n.a.
Dirix et al. [11]	40	6/40 (15)	0	IMRT	60/66 (2)	0	76 (2yrs)	89 (2yrs)	n.a.
Duprez et al. [8]	130	31/130 (24)	22	IMRT	70 (2)	5	59 (5yrs)	52 (5yrs)	n.a.
Wiegner et al. [12]	52	11/52 (21)	9	IMRT	66 (2.2)	56	74 (2yrs)	66 (2yrs)	n.a.
Present study	15	15/15 (100)	47	IMRT		53	87 (2yrs)	100 (2yrs)	69% excellent, 31% good
Total	488	126	11			17	70	71	

Table 4: Summary of series including all sinunasal tumor sites treated with IMRT, no separate analysis of outcome in patients with nasal tumors, n.a. = not assessed.

Larger studies including nasal tumors executively are mostly not applying chemotherapy [2,4,6,14]. IMRT studies dealing with a heterogeneous patient collective including paranasal sinus cancers were applying systemic therapy in 0 to and 17% [7-11,15]. Wiegner et al. applied chemotherapy in a sub collective of patients with nasal cancer in 36% [12]. In our study collective systemic therapy was given in 54%.

Even our study collective is small and the FU is short, to our knowledge this is the first study evaluating cosmetic outcomes in patients with nasal tumors treated with IMRT.

Conclusion

SIB-IMRT in patients presenting with nasal cancer is effective in terms of local control and overall survival either postoperatively after tumor excision or as definitive organ sparing IMRT. Early cosmetic outcomes were subjectively as well as objectively very satisfying. Ablatio nasi can be saved for curative salvage therapy.

References

1. Muir CS, Nectoux J (1980) Descriptive epidemiology of malignant neoplasms of nose, nasal cavities, middle ear and accessory sinuses. Clin Otolaryngol Allied Sci 5: 195-211.

2. Wallace A, Morris CG, Kirwan J, Amdur RJ, Werning JW, et al. (2007) Radiotherapy for squamous cell carcinoma of the nasal vestibule. *Am J Clin Oncol* 30: 612-616.
3. Thorup C, Sebbesen L, Danø H, Leetmaa M, Andersen M, et al. (2010) Carcinoma of the nasal cavity and paranasal sinuses in Denmark 1995-2004. *Acta Oncol* 49: 389-394.
4. Langendijk JA, Poorter R, Leemans CR, de Bree R, Doornaert P, et al. (2004) Radiotherapy of squamous cell carcinoma of the nasal vestibule. *Int J Radiat Oncol Biol Phys* 59: 1319-1325.
5. Chen AM, Daly ME, Bucci MK, Xia P, Akazawa C, et al. (2007) Carcinomas of the paranasal sinuses and nasal cavity treated with radiotherapy at a single institution over five decades: are we making improvement? *Int J Radiat Oncol Biol Phys* 69: 141-147.
6. Levendag PC, Nijdam WM, van Moolenburgh SE, Tan L, Noever I, et al. (2006) Interstitial radiation therapy for early-stage nasal vestibule cancer: a continuing quest for optimal tumor control and cosmesis. *Int J Radiat Oncol Biol Phys* 66: 160-169.
7. Madani I, Vakaet L, Bonte K, Boterberg T, De Neve W (2008) Intensity-modulated radiotherapy for cervical lymph node metastases from unknown primary cancer. *Int J Radiat Oncol Biol Phys* 71: 1158-1166.
8. Duprez F, Madani I, Morbée L, Bonte K, Deron P, et al. (2012) IMRT for sinonasal tumors minimizes severe late ocular toxicity and preserves disease control and survival. *Int J Radiat Oncol Biol Phys* 83: 252-259.
9. Combs SE, Konkell S, Schulz-Ertner D, Münter MW, Debus J, et al. (2006) Intensity modulated radiotherapy (IMRT) in patients with carcinomas of the paranasal sinuses: clinical benefit for complex shaped target volumes. *Radiat Oncol* 1: 23.
10. Daly ME, Chen AM, Bucci MK, El-Sayed I, Xia P, et al. (2007) Intensity-modulated radiation therapy for malignancies of the nasal cavity and paranasal sinuses. *Int J Radiat Oncol Biol Phys* 67: 151-157.
11. Dirix P, Vanstraelen B, Jorissen M, Vander Poorten V, Nuyts S (2010) Intensity-modulated radiotherapy for sinonasal cancer: improved outcome compared to conventional radiotherapy. *Int J Radiat Oncol Biol Phys* 78: 998-1004.
12. Wiegner EA, Daly ME, Murphy JD, Abelson J, Chapman CH, et al. (2012) Intensity-modulated radiotherapy for tumors of the nasal cavity and paranasal sinuses: clinical outcomes and patterns of failure. *Int J Radiat Oncol Biol Phys* 83: 243-251.
13. Bonner JA, Harari PM, Giralt J, Azarnia N, Shin DM, et al. (2006) Radiotherapy plus cetuximab for squamous-cell carcinoma of the head and neck. *N Engl J Med* 354: 567-578.
14. Katz TS, Mendenhall WM, Morris CG, Amdur RJ, Hinerman RW, Villaret DB (2002) Malignant tumors of the nasal cavity and paranasal sinuses. *Head Neck* 24: 821-829.
15. Hoppe BS, Stegman LD, Zelefsky MJ, et al. (2007) Treatment of nasal cavity and paranasal sinus cancer with modern radiotherapy techniques in the postoperative setting--the MSKCC experience. *Int J Radiat Oncol Biol Phys* 67: 691-702.

This article was originally published in a special issue, entitled: "**Cancer Radiation Therapy**", Edited by Xin Chen, University of Arkansas for Medical Sciences, USA