

## Immunopathological Diagnosis of Mucous Membrane Pemphigoid (MMP)

Pejcic A<sup>1</sup>, Zivkovic V<sup>2</sup>, Pesic Z<sup>3</sup>, Obradovic R<sup>1</sup>, Awan K<sup>4</sup>, Dencic T<sup>2</sup>, Minic I<sup>1\*</sup>, Mirkovic D<sup>1</sup> and Zarev M<sup>3</sup>

<sup>1</sup>Department of Periodontology, Medical Faculty, University of Nis, Serbia

<sup>2</sup>Institute for Pathology, Medical Faculty, University of Nis, Serbia

<sup>3</sup>Department for Maxillo Facial Surgery, Medical faculty, University of Nis, Serbia

<sup>4</sup>Department of Oral Medicine and Diagnostic Sciences, College of Dentistry, King Saud University, Riyadh, Saudi Arabia

\*Corresponding author: Ivan Minic, Department of Periodontology, Medical Faculty, University of Nis, Serbia, Tel: +381643004883; E-mail: ivanminic@yahoo.com

Rec date: May 20, 2016; Acc date: June 22, 2016; Pub date: June 27, 2016

Copyright: © 2016, Pejcic A, et al. This is an open-access article distributed under the terms of the Creative Commons Attribution License, which permits unrestricted use, distribution, and reproduction in any medium, provided the original author and source are credited.

### Abstract

**Background:** Mucous membrane pemphigoid (MMP) is a serious, autoimmune, blistering disorder which primarily involves the mucous membranes and that can result in blindness and other complications as a result of scarring of mucous membranes. The oral cavity and the eye are most frequently involved. Since extension of the lesion into pharynx causes dysphagia and progressive ocular lesions may cause blindness, early and valid diagnosis is very important. Diagnosis of MMP is a problem because patients afflicted are elderly, the disease is chronic, and is often in an advanced stage when the diagnosis is established and requires aggressive therapy for control. Oral and dental care is important in all phases of the diagnosis and treatment of the patient with mucous membrane pemphigoid. Early recognition and diagnosis are important for early treatment, improving survival and for limiting the complications of therapy.

**Methods:** Here we present a case of mucous membrane pemphigoid with onset at age 49 in patient who manifested severe periodontal disease and showed the lesion only on the mucous membrane of the gingiva. We describe how we made a differential diagnosis from other diseases which also accompany similar lesions.

**Results:** We examined the clinical manifestations, blood test results, histopathologic findings of the affected tissue, and immunological findings in relation to autoimmunity.

**Conclusion:** We believe that the diagnostic strategy described in the present study will be quite informative for making rapid and definite diagnoses of similar cases.

**Keywords:** Mucous membrane pemphigoid; Diagnosis; Therapy; Immunopathology; Histopathology

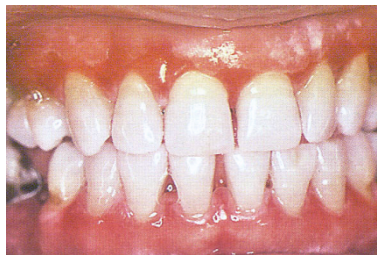diagnosis and treatment and to facilitate future investigations for mucous membrane pemphigoid.

### Introduction

Mucous membrane pemphigoid (MMP) is a heterogeneous group of blistering autoimmune bullous disorder of the skin and mucosae and unknown etiology [1,2]. Intraoral manifestations of MMP feature the formation of vesiculobullous lesions that eventually rupture, leading to pseudo membrane covered irregular-shaped ulcerations. The presence of these often painful oral lesions may hinder oral hygiene efforts resulting in increased plaque accumulation and may increase the risk of developing periodontal disease [3]. The success of any treatment depends on a proper and correct diagnosis. However, MMP frequently presents diagnostic problems because the clinical symptoms often resemble other diseases showing desquamated gingivitis and histological examination of biopsies cannot always differentiate MMP from these diseases [4]. Since the oral membrane is most frequently involved, periodontitis have an opportunity to meet MMP patients before a definite diagnosis is made. Since oral lesions may progress if untreated, a definite diagnosis is an important component in the overall program of therapy for MMP patients [5]. We aimed to develop consensus-based recommendations for medical communication among various health care professional, to improve accuracy of

### Case Report

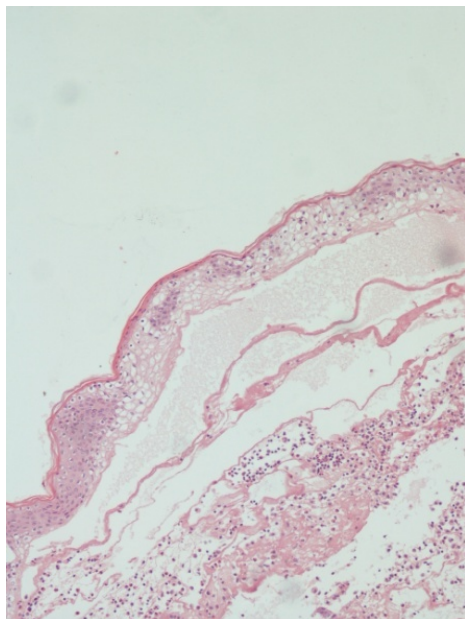
A 49-year-old Serbian woman was in good health but with spontaneous bleeding from gingiva and painful desquamation of the gingiva. A year and a half before she visited her dentist but her problem was not resolved. After that, a gingival biopsy was taken, however, the histology showed only non-specific gingivitis. She received oral cavity irrigation and topical application of corticosteroid for about 3 months. Clinical symptoms did not improve and she was referred to us, to Dental Clinic in Nis at the Department of Periodontology and oral medicine for further examination and treatment. Clinical oral examination revealed redness, epithelial desquamation, swelling and vesiculation of the gingiva. The diagnosis of periodontal disease was made based on the medical history, clinical findings and results of the radiographic examination (Figure 1).



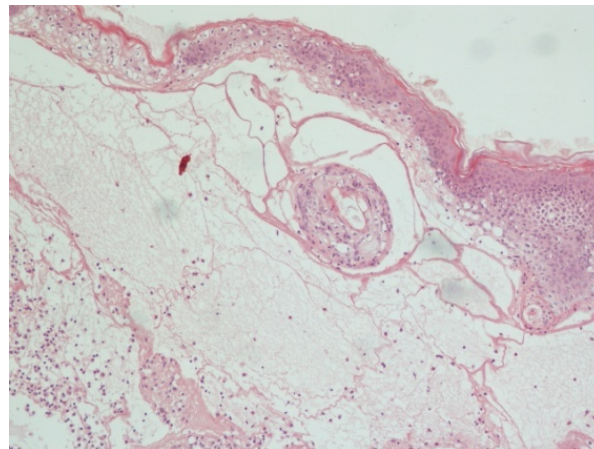
**Figure 1:** Clinical condition with redness, desquamation and swelling of the gingiva.

The results of laboratory examinations were within normal ranges and data not shown.

The biopsy of the gingival tissue was taken in the Department for Maxillofacial surgery at Dental Clinic in Nis and sent to the Institute of Pathology, Medical faculty in Nis. Histopathological examination revealed separation of the epithelium from the basement membrane, but not within the epithelium and sub epidermal bulla with fibrin net and inflammatory infiltrate. Massive infiltrates were observed in the connective tissues (lymphocytes, polymorphonuclear leukocytes and plasma cells) (Figures 2 and 3).

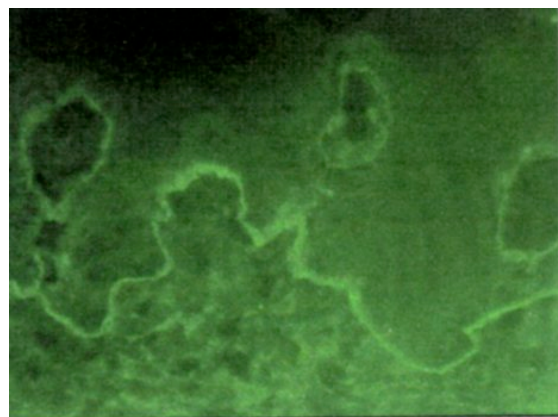


**Figure 2:** Separation of the epithelium from the basement membrane, but not within the epithelium (HEX200).



**Figure 3:** Bullous pemphigoid–sub epidermal bula with fibrin net and inflammatory infiltrate (Hex200).

Immunological examination for differential diagnosis of autoimmune disease was performed at the Central laboratory for immunological examination at Medical faculty in Nis. By indirect immunofluorescence, the patient's IgG reacted with the basement membrane zone of human gingiva sections (Figure 4).



**IgG**

**Figure 4:** Presence of IgG deposits (indirect immunofluorescence, original magnification x400).

Based on the clinical findings and the results of immunological examination, diagnosis of this patient was MMP with advanced periodontitis. Treatment of MMP consisted of systemic and topical administration of corticosteroid (Dexamethasone at a dosage of 1.5 mg daily and tapered to 0.5 mg daily). In addition to steroid therapy, periodontal treatment was performed with conventional conservative therapy. Several months later, following therapy, the gingival appearance improved dramatically.

## Discussion

Mucous membrane pemphigoid is a subepithelial vesiculobullous disorder mainly of late middle age; it has a slight predilection for women [6]. Whereas mucous membrane pemphigoid was formerly considered a single entity, it is now quite evident that a number of subepithelial vesiculobullous disorders may produce similar clinical pictures and also that a range of variants of mucous membrane pemphigoid exists, with antibodies directed against various hemidesmosomal components or components of the epithelial basement membrane. Mucous membrane pemphigoid, a chronic systemic autoimmune blistering disease that affects any mucous membrane, is characterized by linear deposition of IgG, IgM, IgA or C3 along the epithelial basement membrane that leads in most mucosal tissue to progressive scar formation [7,8].

Diagnosis and management of immune-mediated sub-epithelial blistering diseases on clinical grounds alone are impossible; a full history, general and oral examinations, and biopsy with immune staining are now invariably required, sometimes supplemented with other investigations. Most patients with mucous membrane pemphigoid affecting the mouth manifest desquamative gingivitis, a fairly common complaint typically seen in women who are middle-aged or older [4,9]. Oral vesicles and erosions may also occur, and there can be a positive Nikolsky sign. Some patients have lesions of other stratified squamous epithelia, presenting as conjunctival, nasal, esophageal, and laryngeal, vulval, penile, or anal involvement. Apart from improving oral hygiene, immunomodulatory-in particular, immunosuppressive-therapy is typically required to control oral lesions in mucous membrane pemphigoid. No single treatment regimen reliably controls all these disorders.

The present case exhibited desquamative gingivitis and severe periodontal disease. The differential diagnosis of MMP includes Pemphigus vulgaris, Stevens-Johnson syndrome, Erythema multiform, Paraneoplastic pemphigus and Pseudopemphigoid, as and oral viral infection [3,10,11]. Based on the clinical findings and patient's history, pemphigus vulgaris, paraneoplastic pemphigus and pseudopemphigoid were suspected. Differential diagnosis among these diseases is especially important. In MMP, oral mucosal lesions frequently extend into the pharynx and esophagus causing a sore throat and dysphagia, and severe ocular involvement may cause blindness.

Histopathological examination using tissue sections of gingiva revealed separation of the epithelium from the basement membrane zone. These findings suggested the possibility of pemphigoid, but not pemphigus. Early in disease, infiltration of T lymphocytes, plasma cells, polymorphonuclear leukocytes and occasional eosinophils are present. In the acute phase, there are numerous polymorphonuclear leukocytes, and in the later phases, sub-epithelial fibrosis ensues. In order to make a definite diagnosis, indirect immunofluorescence was performed. The patient's IgG reacted with the basement membrane zone of human gingiva sections [12]. Medical treatment is a multidisciplinary approach that is essential in the management of MMP. The choice of agents for treatment of MMP is based upon the sites of involvement, clinical severity, and disease progression.

Because MMP is a systemic disease, topical therapy alone is insufficient. Evaluation of the clinical picture-combined with the severity of inflammation, location and rapidity of progression-should direct selection of anti-inflammatory medical treatment. For patients with severe, rapidly progressive disease, the treatment should consist of

prednisone (1 mg to 1.5 mg per kg body weight per day) and cyclophosphamide or azathioprine [13]. The most common side effects of cyclophosphamide include myelosuppression and hemorrhagic cystitis, whereas azathioprine most commonly causes gastrointestinal discomfort, although reversible hepatic toxicity can occur in 2% of patients. Patients need to be carefully monitored by their internist for these complications. For less progressive disease, dapsone (50 mg to 200 mg per day) can be considered as an alternative initial therapy [14]. Dapsone treatment should be avoided in sulfa-allergic patients. Other promising treatments include mycophenolate mofetil combined with dapsone and steroid, intravenous immunoglobulin, and biologics such as rituximab and daclizumab. Immunosuppressive treatment is usually continued 2 to 3 years into remission [15,16].

Topical treatments are often used as adjunctive therapy in the treatment of MMP, and occasionally as monotherapy in patients with limited oral disease [17]. Successful treatment of oral lesions has been reported with the use of topical steroids, tacrolimus, and cyclosporine [18,19]. Topical therapy of MMP involving the oral mucosa can be augmented with specialized application devices and administration at bedtime when oral secretions are relatively low. The patients diagnosed with MMP appear to be no more at risk an increased progression periodontal disease. Oral care includes appropriate dental hygiene, referral for dental care, monitoring for candidosis, and topical anesthetics for pain. Soft, bland foods may cause less injury to eroded mucosa when disease is flaring. Fortunately, oral disease does not commonly result in functionally significant scarring.

## Conclusions

In this case, based on the clinical findings and the results of immunological examination, we diagnosed that this patient has MMP accompanied with advanced periodontitis. The initial oral findings and diagnosis and treatment in this case of mucous membrane pemphigoid are presented. Histologic and immunologic studies were undertaken in this case to confirm the clinical diagnosis. Early diagnosis and aggressive local and systemic therapy are critical to long-term visual outcome in cases of mucous membrane pemphigoid. The treatments prescribed illustrate that topical steroids are effective, but in this case systemic steroid therapy with or without other immunological active drugs is required. The diagnosis of MMP remains a challenge as patients may present to a variety of specialists, depending upon their initial symptomatology, and due to the diverse clinical manifestations.

## References

1. Chan LS, Ahmed AR, Anhalt GJ, Bernauer W, Cooper KD, et al. (2002) The first international consensus on mucous membrane pemphigoid: definition, diagnostic criteria, pathogenic factors, medical treatment, and prognostic indicators. *Arch Dermatol* 138: 370-379.
2. Alexandre M, Brette MD, Pascal F, Tsianakas P, Fraïtag S, et al. (2006) A prospective study of upper aerodigestive tract manifestations of mucous membrane pemphigoid. *Medicine (Baltimore)* 85: 239-252.
3. Thorne JE, Anhalt GJ, Jabs DA (2004) Mucous membrane pemphigoid and pseudopemphigoid. *Ophthalmology* 111: 45-52.
4. Markopoulos AK, Antoniadis D, Papanayotou P, Trigonidis G (1996) Desquamative gingivitis: a clinical, histopathologic, and immunologic study. *Quintessence Int* 27: 763-767.
5. Bernauer W, Wright P, Dart JK, Leonard JN, Lightman S (1993) The conjunctiva in acute and chronic mucous membrane pemphigoid. An immunohistochemical analysis. *Ophthalmology* 100: 339-346.
6. Sollecito TP, Parisi E (2005) Mucous membrane pemphigoid. *Dent Clin North Am* 49: 91-106, viii.

7. Demers PE, Robin H, Prost C, Toutblanc M, Hoang-Xuan T (1998) Immunohistopathologic testing in patients suspected of ocular cicatricial pemphigoid. *Curr Eye Res* 17: 823-827.
8. Michel B, Waisman M, Thomas CI, Levine M (1974) Immunofluorescent test in bullous diseases of skin and mucous membranes. *Ann Ophthalmol* 6: 1311-1316.
9. Sánchez AR, Rogers RS 3rd, Kupp LI, Sheridan PJ (2004) Desquamative gingivitis associated with IgG/IgA pemphigoid presents a challenging diagnosis and treatment: a case report. *J Periodontol* 75: 1714-1719.
10. Robinson ND, Hashimoto T, Amagai M, Chan LS (1999) The new pemphigus variants. *J Am Acad Dermatol* 40: 649-671.
11. Favia GF, Di Alberti L, Piattelli A (1998) Paraneoplastic pemphigus: a report of two cases. *Oral Oncol* 34: 571-575.
12. Vaughn Jones SA, Palmer I, Bhogal BS, Eady RA, Black MM (1995) The use of Michel's transport medium for immunofluorescence and immunoelectron microscopy in autoimmune bullous diseases. *J Cutan Pathol* 22: 365-370.
13. Brody HJ, Pirozzi DJ (1977) Benign mucous membrane pemphigoid. Response to therapy with cyclophosphamide. *Arch Dermatol* 113: 1598-1599.
14. Ciarrocca KN, Greenberg MS (1999) A retrospective study of the management of oral mucous membrane pemphigoid with dapsone. *Oral Surg Oral Med Oral Pathol Oral Radiol Endod* 88: 159-163.
15. Daoud YJ, Amin KG (2006) Comparison of cost of immune globulin intravenous therapy to conventional immunosuppressive therapy in treating patients with autoimmune mucocutaneous blistering diseases. *Int Immunopharmacol* 6: 600-606.
16. Foster CS, Chang PY, Ahmed AR (2010) Combination of rituximab and intravenous immunoglobulin for recalcitrant ocular cicatricial pemphigoid: a preliminary report. *Ophthalmology* 117: 861-869.
17. Arduino PG, Farci V, D'Aiuto F, Carcieri P, Carbone M, et al. (2011) Periodontal status in oral mucous membrane pemphigoid: initial results of a case-control study. *Oral Dis* 17: 90-94.
18. Suresh L, Martinez Calixto LE, Radfar L (2006) Successful treatment of mucous membrane pemphigoid with tacrolimus. *Spec Care Dentist* 26: 66-70.