

Images – Pulmonary Alveolar Microlithiasis (PAM)

Ritu Galhotra* and Kamini Gupta

Department of Radiodiagnosis, Dyanand Medical College & Hospital, Ludhiana – 141001, India

Abstract

Pulmonary alveolar microlithiasis (PAM) is a rare disease of unknown origin in which calcific concretions collect in alveolar spaces. No known cause for the disease had been identified and there appears to be no systemic disorder of calcium metabolism. Plain chest X-ray shows a white lung consisting of fine sandlike micro calcification diffusely scattered throughout both lungs with high density at lung basis. CT reveals ground glass haze with inter and intra lobular septal thickening suggestive of crazy paving pattern. We here report the typical X-ray and HRCT images of a case of PAM: a rare disease characterized by wide spread sand like intra alveolar calcifications.

Case Report

We here present a case of a 54 year old male who presented to us with history of breathlessness on exertion from last 7 years which increased in last six months. Auscultation revealed wheezing and coarse crepitations. Pulmonary function tests revealed features of restrictive lung disease with reduced lung capacity (55%). In the past he was diagnosed as a case of pulmonary tuberculosis 7 years back, for which he took treatment but was not relieved of the symptoms. Sputum for AFB was found to be negative. Chest X-ray revealed a diffuse bilaterally symmetric micronodular sand storm pattern predominantly in the middle and lower lung zones with obliteration of heart borders and the diaphragm (Figure 1). HRCT (High Resolution Computed Tomography) revealed extensive ground glass attenuation with inter and intralobular septal thickening suggestive of crazy paving pattern with multiple calcified nodules predominantly in lower lobes and in sub-pleural location. Calcification was also seen along the vessels as well as along the interlobular septa. Multiple subpleural cysts were seen along the costal and mediastinal pleura (Figures 2-4). On the bases of typical X-ray and HRCT findings, diagnosis of PAM was made.

Discussion

Pulmonary alveolar microlithiasis (PAM) is an uncommon chronic disease characterized by calcification within the alveoli and paucity of symptoms in contrast to the imaging findings [1]. No known cause for the disease had been identified and there appears to be no systemic disorder of calcium metabolism [2]. A rare disease, it has been reported fewer

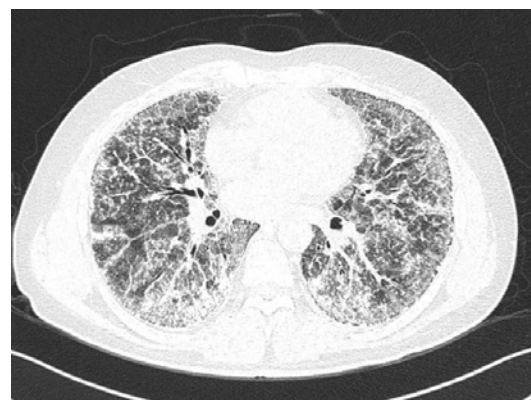

Figure 2: HRCT sections showing ground glass attenuation with inter and intralobular septal thickening with multiple calcified nodules predominantly in lower lobes and in sub-pleural location.

than 160 times in the literature. Although the cause is unknown, one possibility is an inborn error of metabolism. The high rate of occurrence within families suggests an autosomal recessive hereditary factor [3]. Its pathogenesis has yet to be elucidated. The main characteristic of PAM is widespread laminated calcipherites in the alveolar spaces in the absence of any known disorder of calcium metabolism [1]. The alveolar walls gradually get scarified and slowly progressive physiologic lung impairment becomes apparent [2]. Patient may remain asymptomatic or usually becomes symptomatic in 3rd or 4th decade [1]. Though the age range is wide there is some evidence that women are affected more than men in familial cases. There seems to be equal distribution between the sexes in the sporadic cases. In over 50 percent of reported cases, a familial association with sibling has been established [2]. Clinical presentation is usually as a lung disorder with restrictive pattern [1]. The diagnosis of pulmonary alveolar microlithiasis is mainly radiological and is based on 2 factors i.e. characteristic radiological appearance and clinico-radiological association. Chest radiograph is all that is needed for the diagnosis but confirmation with CT scan, scintigraphy,

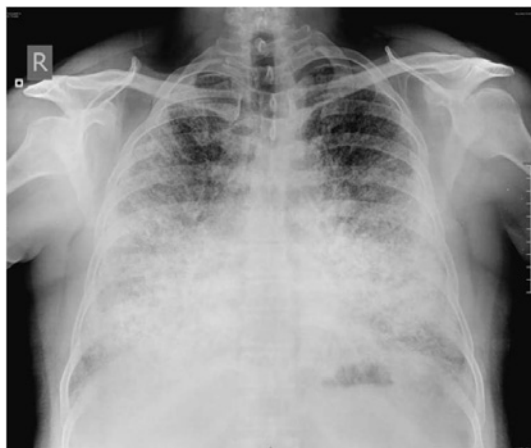

Figure 1: Chest X-ray showing diffuse bilaterally symmetric micronodular calcification (sand storm pattern) involving predominantly the middle and lower lung zones with obliteration of heart borders and the diaphragm.

***Corresponding Author:** Dr. Ritu Galhotra (MD, Radiodiagnosis), 96-Lal Bagh, Near Rajguru Nagar, Ludhiana, Punjab-141001, India, Tel: 0161-2802414, 09876137494, E-mail: ritugalhotra96@gmail.com

Received March 16, 2012; **Accepted** June 22, 2012; **Published** June 24, 2012

Citation: Galhotra R, Gupta K (2012) Images – Pulmonary Alveolar Microlithiasis (PAM). J Pulmon Resp Med 2:124. doi:[10.4172/2161-105X.1000124](https://doi.org/10.4172/2161-105X.1000124)

Copyright: © 2012 Galhotra R, et al. This is an open-access article distributed under the terms of the Creative Commons Attribution License, which permits unrestricted use, distribution, and reproduction in any medium, provided the original author and source are credited.

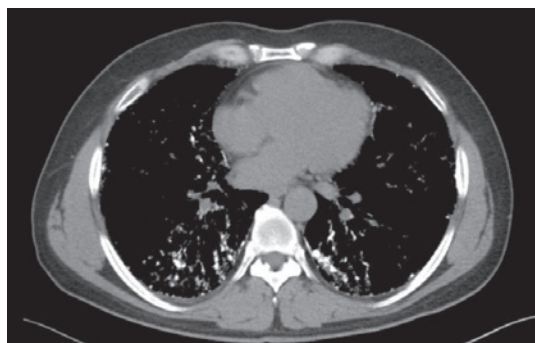

Figure 3: HRCT sections showing ground glass attenuation with inter and intralobular septal thickening with multiple calcified nodules predominantly in lower lobes and in sub-pleural location.

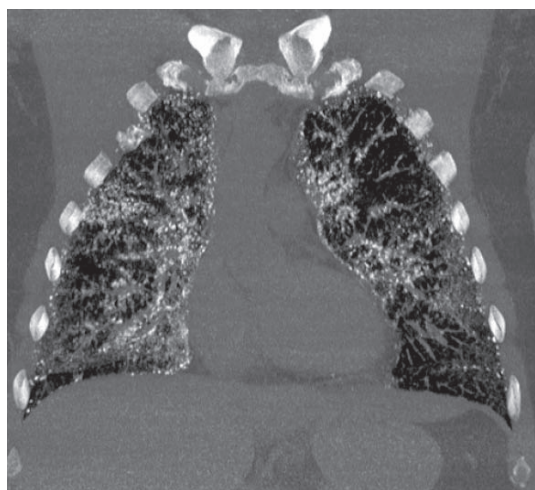


Figure 4: HRCT sections showing ground glass attenuation with inter and intralobular septal thickening with multiple calcified nodules predominantly in lower lobes and in sub-pleural location.

2. Dwivedi MK, Pal RK, Borkar PB (1999) Images: pulmonary alveolar microlithiasis. *Indian J Radiol Imaging* 9: 195-196.
3. Korn MA, Schurawitzki H, Klepetko W, Burghuber OC (1992) Pulmonary alveolar microlithiasis: findings on high-resolution CT. *AJR Am J Roentgenol* 158: 981-982.
4. Cluzel P, Grenier P, Bernadac P, Laurent F, Picard JD (1991) Pulmonary alveolar microlithiasis: CT findings. *J Comput Assist Tomogr* 15: 938-942.
5. Marchiori E, Gonçalves CM, Escuissato DL, Teixeira KI, Rodrigues R, et al. (2007) Pulmonary alveolar microlithiasis: high-resolution computed tomography findings in 10 patients. *J Bras Pneumol* 33: 552-557.

transbronchial biopsy can be done [2]. Plain chest radiograph usually reveals diffusely scattered bilateral areas of micronodular calcification (sandstorm pattern) that predominates in the middle and lower lung zones. The heart border and the diaphragm are usually silhouetted [1]. CT chest reveals a peribular and bronchovascular distribution of the disease process at the level of secondary pulmonary lobule. This pattern correlates closely with pathological findings [4]. Other relevant findings can be small parenchymal nodules, calcification along the interlobular septa, nodular fissures, sub-pleural nodules, sub-pleural cysts, dense consolidation and a mosaic pattern of attenuation [5]. HRCT chest findings of an individual with PAM are distinct. In most cases such findings form the basis of diagnosis, thus eliminating the need to perform a lung biopsy [5].

Conclusion

PAM is a rare entity characterized by wide spread calcification in lung parenchyma. In most cases characteristic X-ray and HR findings form the basis of the diagnosis eliminating the need for lung biopsy.

References

1. Gasparetto EL, Tazoniero P, Escuissato DL, Marchiori E, Frare E Silva RL, et al. (2004) Pulmonary alveolar microlithiasis presenting with crazy-paving pattern on high resolution CT. *Br J Radiol* 77: 974-976.