

Hypertrophic Olivary Degeneration After Pontine Hemorrhage: A Case Report

Yingxin Yu and Xiaokun Qi*

Department of Neurology, Navy General Hospital, PR China

Abstract

Introduction: Hypertrophic olivary degeneration (HOD) is a rarely neurologic disease, occurring after damage to the dentato-rubro-olivary pathway.

Case presentation: A 50-year-old hypertensive man suffered pontine hemorrhage resulting in numerous neurological deficits. Neurologic examination 4 months after the hemorrhage showed mild to moderate improvement. 8 months after the hemorrhage, the patient developed truncal and limb tremors, unsteady gait and dysarthria. Magnetic resonance showed increasing bilateral hypertrophic olivary degeneration. Administration of clonazepam and levodopa were ineffective for symptom relief.

Conclusion: This case was presented in order to describe the clinical manifestations of HOD and to recognize the possibility of hypertrophic olivary degeneration after the pontomesencephalic stroke.

Keywords: Hypertrophic olivary degeneration; Pontine hemorrhage; Guillain-Mollaret triangle

Introduction

Hypertrophic olivary degeneration (HOD) is a rare neurologic disease. The involved neuronal pathway includes the red nucleus, the ipsilateral inferior olivary nucleus, and the contralateral cerebellar dentate nucleus. The pathway was defined by Guillain and Mollaret in 1931 [1], and is therefore referred to as the “Guillain-Mollaret triangle.” HOD occurs as a result of lesions in the neuronal connections of the dentatorubral olivary pathway [2] which lesion may be referred to.

Here we report a case of hypertrophic olivary degeneration after pontine hemorrhage. The case had significant clinical symptoms. At same time, we report the clinical manifestation and the findings on CT and MRI in this patient.

Case Presentation

A 50-year-old hypertensive man developed acute onset right face numbness, left upper and lower limb weakness, and dysarthria. Neurologic examination demonstrated a decreased level of consciousness, bilateral miosis, horizontal gaze paralysis, right ptosis, dysarthria, left hemiplegia, and left tongue deviation. CT and MRI showed hemorrhage throughout the length of the right pontine tegmentum (Figures a and b). In the ensuing months, the patient's condition slowly improved, and his hypertension was controlled by medication. Neurologic examination 4 months after the hemorrhage showed mild to moderate improvement.

Eight months after pontine hemorrhage, the patient acutely developed a resting tremor with a frequency of 3-5Hz in the head, trunk and all of limbs. The tremor was increased when standing, and the left upper arm was contracted. His trunk and limbs were ataxic. Examination revealed speech was dysarthric but intelligible. Ocular abnormalities included mild right adduction and mild right ptosis, although vertical and pendular nystagmus was absent. He had right peripheral facial paralysis and facial and ocular spasm. Deep and superficial sensory deficits persisted in the left side of the face and extremity. Bilateral Babinski signs were positive. Gradually, his gait also became ataxic and he was unable to walk independently.

Magnetic resonance studies at 9 months (Figure c) and 11

months (Figure d) showed residual hemosiderin in the right pontine tegmentum, extending rostrally to the mesencephalon and caudally to the medulla oblongata, and increasing bilateral hypertrophic olivary degeneration (HOD). Pharmacotherapy was attempted sequentially with clonazepam and levodopa, without effect.

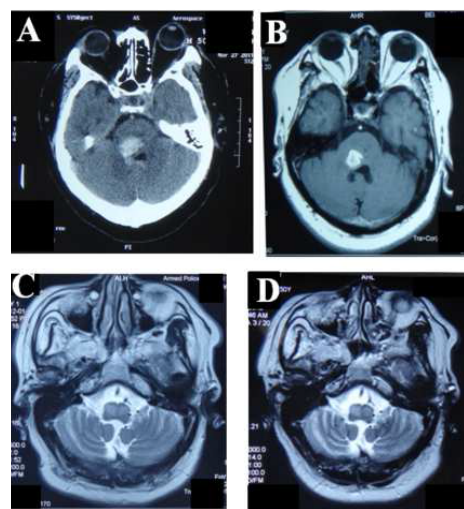


Figure 1: A Brain CT scan showing dorsal pontine hemorrhage on Mar 27th, 2011 (Figure A). MRI revealed high intensity lesions in dorsal pons on sagittal T1 on Apr 22nd, 2011 (Figure B). MRI sagittal T2 revealed high intensity lesions indicating hypertrophic olivary degeneration on Dec 1st, 2011 (Figure C). Brain MRI T2 revealed a symmetric enlargement of the inferior olivary nuclei with high signal intensity on Feb 28th, 2012 (Figure D).

*Corresponding author: Xiaokun Qi, Department of Neurology, Navy General Hospital, PR China, Tel: 86-10-6657520; Fax: 86-10-6657526; E-mail: xiaokun_qi@yahoo.com

Received June 12, 2015; Accepted April 12, 2016; Published April 17, 2016

Citation: Yu Y, Qi X (2016) Hypertrophic Olivary Degeneration After Pontine Hemorrhage: A Case Report. J Clin Case Rep 6: 762. doi:10.4172/2165-7920.1000762

Copyright: © 2016 Yu Y, et al. This is an open-access article distributed under the terms of the Creative Commons Attribution License, which permits unrestricted use, distribution, and reproduction in any medium, provided the original author and source are credited.

Discussion

Hypertrophic olivary degeneration may occur after damage to the dentato-rubro-olivary pathway [3]. This pathway is also known as the Guillain-Mollaret triangle, and disruption of this pathway may result in palatal myoclonus and other manifestations of cerebellar system dysfunction [1]. Hypertrophic olivary degeneration is considered a unique type of degeneration because the degenerating olive becomes hypertrophic rather than atrophic. The proposed mechanism of this change is trans-synaptic degeneration. Pathologically, there is glial hypertrophy and proliferation of gemistocytic astrocytes [2]. It is important to recognize that both the cerebellar symptoms and hypertrophic olivary degeneration developed months after the pontomesencephalic stroke. Without knowledge of this clinical pathologic entity, this sequence of events could be misinterpreted as a new progressive neurodegenerative disorder affecting the cerebellar system. This case was misdiagnosed as medulla oblongata demyelination at another center.

Dyskinesia is commonly associated with HOD. Theoretically, all HOD patients should develop palatal myoclonus [2], however

clinically not all do, as demonstrated in this case. This patient also did not develop pendular nystagmus [4], which is another common manifestation. The duration from initial stroke to HOD occurs as early as 3 months [5] and as late as 9 months. Pharmacotherapy is typically ineffective, and thalamotomy or chronic thalamic stimulation remain the most effective treatments [4].

References

1. Guillain G, Mollaret P (1931) Deus de myoclonies synchrones et rythmees velepharyngo-oculo-diaphramnatiques. *Rev Neurol* 2: 545-566.
2. Shepherd GM, Tauböll E, Bakke SJ, Nyberg-Hansen R (1997) Midbrain tremor and hypertrophic olivary degeneration after pontine hemorrhage. *Movement Disorders* 12: 432-437.
3. Hornyak M, Osborn AG, Couldwell WT (2008) Hypertrophic olivary degeneration after surgical removal of cavernous malformations of the brain stem: report of four cases and review of the literature. *Acta Neurochir* 150: 149-156, discussion 156.
4. Carota A, Düron N, Cereda C, Bassetti CL (2012) Vertical pendular nystagmus and hypertrophic inferior olivary nuclei degeneration: an "odd couple". *J Neurol* 259: 372-374.
5. Bruno MK, Wooten GF (2012) Hypertrophic Olivary Degeneration. *Arch Neurol* 69: 274-275.