

Human T-Cell Lymphoma Virus-Positive Allograft Used For Effective Orthotopic Liver Transplantation: A Case Report and Review of the Literature

TR Harring¹, NT Nguyen¹, JA Goss^{1,2} and CA O'Mahony^{1,2*}

¹Michael E. DeBakey Department of Surgery, Baylor College Of Medicine, One Baylor Plaza, Jewish Bldg #404D, Houston, TX 77030

²The Liver Center, Michael E. DeBakey Department of Surgery, Baylor College Of Medicine, 1709 Dryden Rd, Suite #1500, Houston, TX 77030

Abstract

Introduction: The human T-cell lymphoma virus was screened for previously in organ donors secondary to concern for progressive disease in an immunocompromised host. However, due to the low prevalence of the virus, a shortage of suitable allografts, and the lack of a time-effective test, this practice has been abandoned in the United States. The human T-cell lymphoma virus type-I may cause progression to several diseases, including human T-cell lymphoma virus-associated myelopathy, and adult T-cell lymphoma/leukemia. Moreover, there is an overall lack of data relating to the safety profile in the medical literature with use of human T-cell lymphoma virus-positive allografts.

Aim: To determine the safety of human T-cell lymphoma virus-positive allografts in orthotopic liver transplantation.

Materials and Methods: Our database was queried for recipients of known human T-cell lymphoma virus-positive allografts at time of transplantation. We present one patient case report followed by a review of the medical literature.

Results: The patient was transplanted secondary to cirrhosis due to alcohol and hepatitis-C virus infection with hepatocellular carcinoma. When a suitable allograft became available, the patient was advised that it was human T-cell lymphoma virus type I-positive. The risks and benefits were discussed thoroughly with the patient and he elected to proceed with the operation. His operation and post-operative course were unremarkable. He continues to do well during on follow-up of over 777 days, and currently he has no symptoms of any human T-cell lymphoma virus-associated disease. Review of the medical literature demonstrates few reports on human T-cell lymphoma virus-related complications after orthotopic liver transplantation; however, there are theories that immunosuppression may cause progressive disease in these patients.

Conclusions: Human T-cell lymphoma virus type I-positive donors can be life-saving sources of allografts. Our center supports the use of these allografts in patients that otherwise continue to be on the waiting list.

Keywords: HTLV; Liver transplantation; Infectious diseases; Allograft

Abbreviations: HTLV: Human T-cell Lymphoma Virus; HTLV-I: Human T-cell Lymphoma Virus, Type I; HTLV-II: Human T-cell Lymphoma Virus, Type II; HAM/TSP: HTLV-Associated Myelopathy or Tropical Spastic Paraparesis; UNOS: United Network of Organ Sharing; OPTN: Organ Procurement and Transplantation Network; OLT: Orthotopic Liver Transplantation; PT: Prothrombin Time; INR: International Normalized Ratio; AST: Aspartate Aminotransferase; ALT: Alanine Aminotransferase; BUN: Blood Urea Nitrogen

Introduction

Human T-cell lymphoma virus (HTLV) is estimated to infect 15 million people in the United States, and it provides one of the few virus-to-cancer links known in medicine. Previously, HTLV was screened for in organ donors secondary to concern for progressive disease in an immunocompromised host. Due to several reasons, including the relative low prevalence of the virus, the dearth of suitable allografts, and the lack of a cost-efficient or time-efficient test, this practice has been abandoned in the United States.

The HTLV viruses, type-I (HTLV-I) and type-II (HTLV-II), were the first identified human retroviruses. HTLV-I may progress to several devastating diseases in approximately 4 to 5% of infected individuals [1], including HTLV-associated myelopathy or tropical spastic paraparesis (HAM/TSP), adult T-cell lymphoma or leukemia, uveitis, and infective dermatitis [2]. The incidence of HAM/TSP has been estimated at 0.25 to 0.3% among HTLV-I-infected persons [1]. HTLV-II has not been specifically linked to any disease to date. Transmission

of HTLV is through breastfeeding, sexual contact, and exposure to contaminated blood.

The prevalence of HTLV varies greatly between geographical areas. In endemic areas including South America, Asia, Africa, the Middle East, Pacific Melanesian islands, Papua New Guinea, and the Caribbean, the prevalence can be as high as 30%, but in low-risk populations in the United States and in Europe, the prevalence is estimated to be less than 1% [2]. However, with global networking and larger donor pools coming from areas with increased immigrant populations, the actual seroprevalence in the United States and Europe may be greater than estimated. Moreover, the risk of seroconversion approaches 60% after blood transfusions with median time to conversion of 51 days, and the risk of seroconversion from mother-to-infant transmission via breastfeeding approaches 30% [2]. Theoretically, transplant patients could receive an allograft from a donor infected with HTLV that

***Corresponding author:** Christine A. O'Mahony, Assistant Professor, Michael E. DeBakey Department of Surgery, Division of Abdominal Transplantation, The Liver Center, 1709 Dryden Street, Ste #1500 Houston, TX 77030, Tel. 713-798-8355; Fax: 713-798-8319; E-mail: comahony@bcm.edu

Received September 15, 2020; Accepted November 05, 2020; Published November 12, 2020

Citation: Harring TR, Nguyen NT, Goss JA, O'Mahony CA (2011) Human T-Cell Lymphoma Virus-Positive Allograft Used For Effective Orthotopic Liver Transplantation: A Case Report and Review of the Literature. J Transplant Technol Res 1:102. doi:10.4172/2161-0991.1000102

Copyright: © 2011 Harring TR, et al. This is an open-access article distributed under the terms of the Creative Commons Attribution License, which permits unrestricted use, distribution, and reproduction in any medium, provided the original author and source are credited.

may still be sero-negative, and the recipient could seroconvert post-transplant leading towards deadly consequences.

Per current United Network of Organ Sharing/Organ Procurement and Transplantation Network (UNOS/OPTN) guidelines, HTLV testing is no longer part of the workup of deceased donors [3]. The requirement was discontinued due to the low seroprevalence in the United States and the lack of availability of testing within a reasonable amount of time. The UNOS/OPTN Board of Directors voted to discontinue the requirement to perform prospective HTLV screening of deceased donors during the June 22-23, 2009 meeting [4]. The enzyme immunoassay test system used previously was discontinued on December 31, 2009, and the only method to perform HTLV testing is now through the use of a high-throughput genomic sequencing platform [4]. This type of testing is problematic due to the time constraints of donor procurement and the time required performing genomic testing, leading to the decision by the Board of Directors to discontinue routine screening.

Given the diseases that HTLV infection may cause, and the theory that immunosuppression associated with solid organ transplantation may actually enhance the risk of associated diseases and infection, reduce the latency period, and accelerate the clinical picture of the associated diseases [5], our center sought to report on the safety of use of these allografts in recipients at our own center and those reported in the medical literature.

Materials and Methods

Our database was queried for patients who received a known HTLV-positive allograft at the time of orthotopic liver transplant (OLT). Between September 1998 and December 2010, 996 patients were transplanted and one patient received an allograft from a known HTLV-positive donor. In the following, we present the case of that patient and a review of the recent medical literature pertaining to HTLV-positive allografts used in OLT.

Results/Case Report

The patient is a 60 year old male Caucasian who presented for OLT due to end-stage-liver-disease secondary to alcoholic and hepatitis-C virus induced cirrhosis with hepatocellular carcinoma. The characteristics of the hepatocellular carcinoma met the requirements for transplantation per Milan criteria [6]. The patient underwent transcatheter arterial chemoembolization of the mass approximately three months prior to OLT. At the time of transplant, the patient had the following laboratory values: prothrombin time (PT) - 13.1 seconds, International Normalized Ratio (INR) - 1.3, albumin - 3.6 gm/dL, total bilirubin - 2.1 mg/dL, direct bilirubin - 0.6 mg/dL, aspartate aminotransferase (AST) - 107 U/L, alanine aminotransferase (ALT) - 80 U/L, alkaline phosphatase - 125 U/L, blood urea nitrogen (BUN) - 19 mg/dL, and creatinine - 0.88 mg/dL (Table 1). The patient had a Model-for-End-Stage-Liver-Disease score of 12 based on these laboratory values. At the time a suitable allograft became available, he was advised that it was HTLV-I-positive. There were no other infections associated with the donor. The risks and benefits were discussed thoroughly with the patient and he elected to proceed with the operation. Documentation was included in his chart specifying that he consented to receive an allograft with a transmissible disease. There were no intraoperative complications, and his post-operative course was unremarkable. The patient was transferred to the intensive care unit after the operation per our center's protocol and was extubated shortly after recovery in the unit. On post-operative day one the patient experienced minimal nausea, which was successfully treated with

medication, and his nasogastric tube was removed. On post-operative day two, the patient was sitting up in a chair. He was transferred to a floor unit on post-operative day three, and began walking with the physical therapy team and working with the occupational therapy team. On post-operative day four, the patient was ambulating with assistance, tolerating an advanced diet, having bowel movements, and his pain was well controlled. He was discharged on post-operative day five after consuming a regular diet and completing his transplant education.

The patient continues to do well during follow-up over the past 777 days (calculated through 9/1/2011). The patient has not had any episodes of allograft rejection and he has no symptoms of any HTLV-associated disease.

Discussion

Concern for diseases resulting from transplantation of HTLV-positive allografts remains debatable, even after UNOS/OPTN has removed the policy requirement for donor HTLV screening on June 23, 2009 [3]. Because seroprevalence in the United States remains quite low, few transplant centers ever confront this issue, and only a handful have power to report the significance of this disease on patient and allograft outcomes after OLT. Our center has currently performed over 1,000 OLT since 1998, yet the case report we present is the only HTLV-I-positive allograft known to be transplanted at our institution.

Two other single-center reports describing their results with the use of HTLV-positive allografts are present in the current medical literature. In one from Indiana, the presence of positive serologies in 55 patients, including HTLV, did not affect early allograft failure [7]. Moreover, patient and allograft survival at 90 days, 1-, and 2-years in the 'high-risk' serology group was 96.4%, 93%, and 92.6%, respectively, and was not significantly different compared to the control group [7]. In a case series from New York, of five HTLV-I-positive liver allografts used for transplant, only two were true positives: one liver was allocated to a patient with concurrent human immunodeficiency virus and hepatitis-C virus infection and subsequently died at 12 months due to recurrent hepatitis-C virus infection; the other liver was allocated to a patient with concurrent human immunodeficiency virus and hepatitis-B virus infection, and this patient was reported to be free of HTLV-associated diseases 18 months post-transplant [8].

Several reports analyzing information from the UNOS/OPTN database show no survival difference between recipients of HTLV-positive liver allografts and HTLV-negative liver allografts. Per Angelis' observations, nine HTLV-positive livers allografts were used but none of the recipients developed HTLV-related disease during a median follow-up of 11.9 months [9]. Kauffman reported that of 6 HTLV-positive organs transplanted, including 3 liver allografts,

	Patient Laboratory Values	Normal Laboratory Values
PT	13.1 seconds*	9.8-12.0 seconds
INR	1.3	-
Albumin	3.6 gm/dL	3.5-5.0 gm/dL
Total Bilirubin	2.1 mg/dL*	0.1-1.2 mg/dL
Direct Bilirubin	0.6 mg/dL*	0.0-0.4 mg/dL
AST	107 U/L*	5-40 U/L
ALT	80 U/L*	5-50 U/L
Alkaline Phosphatase	125 U/L*	30-115 U/L
BUN	19 mg/dL	10-26 mg/dL
Creatinine	0.88 mg/dL	0.50-1.20 mg/dL

*denotes patient laboratory value outside of the normal laboratory value range

Table 1: Patient Laboratory Values at Time of OLT Compared to Normal Laboratory Values.

no malignancy was identified during a range of 1 to 31 months [10]. Marvin et al. showed no statistically significant difference in 1-, 3-, or 5-year patient and allograft survivals of 81 recipients of HTLV-positive liver allografts compared to recipients of HTLV-negative liver allografts [11]. Finally, our own center produced a matched-control group comparison between 18 recipients of HTLV-positive allografts and 36 recipients of HTLV-negative allografts [16]. We demonstrated there was no patient or allograft survival difference between the two groups: 69.7% in HTLV-positive allograft recipients and 65.2% in HTLV-negative allograft recipients ($p > 0.05$, Figure 1) [16].

Transplant center studies in countries where HTLV seroprevalence is high may give additional insight into the risks and benefits of using affected allografts in OLT. The first instance of HTLV transmission through solid organ transplantation was reported in Spain. Per several articles [5,12-14], one HTLV-I-positive organ donor caused disease in three recipients: one liver allograft recipient and two kidney allograft recipients. The donor had no risk factors but his mother was from Venezuela, an endemic area for HTLV, and the donor supposedly contracted HTLV-I during mother-to-infant transmission through breastfeeding [5,12-14]. The donor's organs were procured and transplanted into the recipients in October 1998 [5,14]. All three recipients subsequently seroconverted, which was confirmed after symptoms were apparent [5,14]. The recipients had various neurological deficits ranging from progressive lower extremity weakness and spasticity to pyramidal symptoms [5,14]. All were eventually diagnosed with HAM/TSP; the liver allograft recipient had no improvement of her symptoms and remained paraplegic despite aggressive treatment [5,14]. Regardless of these potential consequences, there remain few other reports examining the outcomes of using these allografts. This leads to the speculation that while HTLV-positive allografts have a theoretical risk for causing devastating disease post-transplantation, the true risk to recipients is within acceptable limits.

Several authors have theorized that immunosuppression coupled with a high viral-load transferred with solid organ transplant may play a role in disease progression in recipients of HTLV-positive allografts [14]. A single-center study in Japan examined the incidence of adult T-cell leukemia post-transplantation in HTLV-positive patients. They discovered that only three of eight (37.5%) pre-transplant HTLV-positive patients developed adult T-cell leukemia after OLT [15]. The authors noted that all patients had acute liver failure as their indication

for OLT, and all patients were on tacrolimus for immunosuppression post-transplant [15]. Interestingly, one other patient fell into both of these same categories, but did not develop leukemia. The researchers further determined that the HTLV strain causing the leukemia was actually the same strain present in the recipient prior to transplantation, and was not due to HTLV acquired from the donor [15]. The patients were diagnosed with adult T-cell leukemia at 3-, 9-, and 25-months after OLT, and the leukemia progression resulted in death in the three patients at 6-, 14-, and 40-months, respectively [15]. The authors of this study also reported that one patient that was HTLV-negative prior to transplantation, received a HTLV-positive allograft but did not develop adult T-cell leukemia [15]. Similarly, in a single-center series from Kentucky, five pre-transplant HTLV-positive patients underwent OLT and none developed HTLV-associated disease subsequently [11].

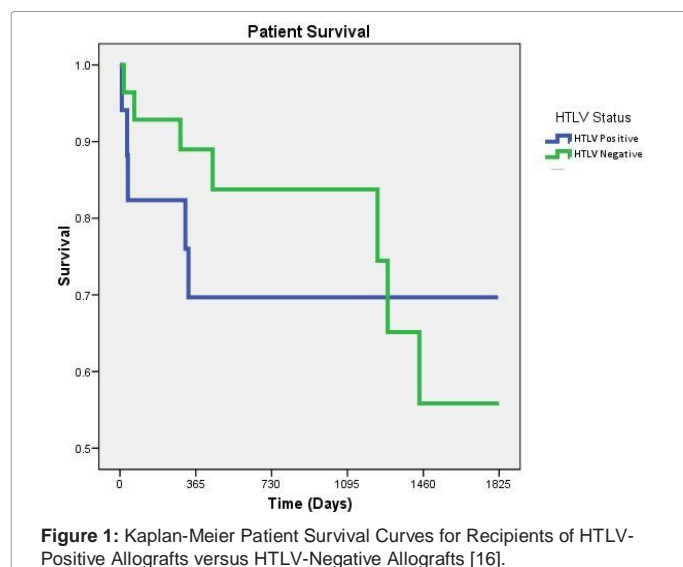
As a whole, these studies suggest that HTLV infection coupled with immunosuppression may not be the only factor in determining HTLV-associated disease post-transplantation. Even similar factors including acute liver failure and the same immunosuppression medication regimen, as pointed out by Kawano et al., do not universally produce the same results [15]. The evolution of post-transplant HTLV-associated diseases is clearly more complex; therefore, there must be other factors influencing the chances of disease progression in individual patients.

Due to the relative low seroprevalence in the United States, and despite an unknown magnitude of devastating consequences, HTLV-positive allografts should remain an option for certain recipients and UNOS/OPTN policy excluding mandatory testing for HTLV should be maintained. Some recipients will gain significant benefit from the use of these allografts, especially those with an urgent need of transplant, older patients, and even those with known pre-transplant HTLV infection [8,9,11]. The group of authors from Spain recommended excluding any potential donors with HTLV infection such as intravenous drug users, individuals from endemic areas, and sexual partners of individuals from endemic areas, due to their collective unfortunate experiences [13]; however, beyond this group there are no other advocates against this UNOS/OPTN policy change. Conversely, many suggest that the risk may be warranted in selected recipients that accept the risk [11,16]. Our center agrees with this philosophy, especially for patients who may be subjected to longer waiting-times prior to transplantation. However, we also stress the importance of a timely discussion with the intended recipient with accurate and thorough documentation of the risks and benefits pertaining to the use of a known HTLV-positive allograft. Additional consent forms with specific language documenting the recipient's acceptance of the use of a 'high-risk' allograft are warranted. Moreover, since routine screening for HTLV is no longer required in the United States, a high-index of suspicion and additional testing is necessary in a patient with any unusual neurological symptoms or signs of lymphoma or leukemia, especially in those at an increased risk of acquiring HTLV.

Ultimately, even with the low chance of disease transmission, any known recipients of HTLV-positive allografts should receive heightened screening post-transplantation [5,7,8,11]. Not only will this process allow for the prompt identification and treatment of HTLV-associated diseases, but it will allow further studies examining the actual risk associated with use of these allografts.

Conclusions

We report one case of HTLV-I-positive liver allograft used in a patient with alcoholic and hepatitis-C virus-associated cirrhosis and hepatocellular carcinoma. Similar to the few reports in the medical literature, we found that HTLV-positive allografts can be suitable and



life-saving organ sources for patients who otherwise would be waiting much longer for a donor.

The use of these allografts is not without increased risk; therefore, we recommend judicious documentation of informed consent. The documentation should reflect an in-depth discussion of the risks and benefits of using HTLV-positive allografts, including the possibilities of disease transmission and devastating progression. The patient must be aware of the immediate risk associated with the acceptance of these allografts versus the continued risk of remaining on the waiting-list.

Our case report supports the use of HTLV-positive allografts and the UNOS/OPTN policy change removing the requirement of prospective donor HTLV screening, as these allografts can provide life-saving organs for patients that may otherwise deteriorate. Transplant practitioners should test for the infection in patients with symptoms suspicious for HTLV-associated diseases, and patients receiving known HTLV-positive allografts should receive heightened screening post-transplantation. As this continues to be a rare disease, additional information from large transplant centers nationally and internationally should be gathered and analyzed regularly to determine the true risk of using HTLV-positive allografts in solid organ transplantation.

Acknowledgements

This work was not funded by grants. Approval to conduct this study is through the Baylor College of Medicine Institutional Review Board, H-22045.

References

1. Kaplan JE, Osame M, Kubota H, Igata A, Nishitani H, et al. (1990) The risk of development of HTLV-I-associated myelopathy/tropical spastic paraparesis among persons infected with HTLV-I. *J Acquir Immune Defic Syndr* 3: 1096-1101.
2. Manns A, M Hisada, LL Grenade (1999) Human T-lymphotropic virus type I infection. *Lancet* 353: 1951-1958.
3. United Network of Organ Sharing/Organ Procurement and Transplantation Network Policies and By-Laws: 2.2.4.1. 2010 [cited 2011 July 28].
4. Leykum LK, El-Serag HB, Cornell J, Papadopoulos KP, et al. (2007) Screening for hepatocellular carcinoma among veterans with hepatitis C on disease stage, treatment received, and survival. *Clin Gastroenterol Hepatol* 5: 508-512.
5. Zarranz JJ, Rouco I, Gómez-Esteban JC, Corral J (2001) Human T lymphotropic virus type I (HTLV-1) associated myelopathy acquired through a liver transplant. *J Neurol Neurosurg Psychiatry* 71: 818.
6. Mazzaferro V, Regalia E, Doci R, Andreola S, Pulvirenti A, et al. (1996) Liver transplantation for the treatment of small hepatocellular carcinomas in patients with cirrhosis. *N Engl J Med* 334: 693-699.
7. Tector AJ, Mangus RS, Chestovich P, Vianna R, Fridell JA, et al. (2006) Use of Extended Criteria Livers Decreases Wait Time for Liver Transplantation Without Adversely Impacting Posttransplant Survival. *Ann Surg* 244: 439-450.
8. Alkofer B, Samstein B, Guarrera JV, Kin C, Jan D, et al. (2006) Extended-Donor Criteria Liver Allografts. *Semin Liver Dis* 26: 221-233.
9. Angelis M, Cooper JT, Freeman RB (2003) Impact of donor infections on outcome of orthotopic liver transplantation. *Liver Transpl* 9: 451-462.
10. Kauffman HM, Taranto SE (2003) Human T-cell lymphotropic virus type-1 and organ donors. *Transplantation* 76: 745-746.
11. Marvin MR, Brock GN, Kwarteng K, Nagubandi R, Ravindra KV, et al. (2009) Increasing Utilization of Human T-Cell Lymphotropic Virus (+) Donors in Liver Transplantation: Is it Safe? *Transplantation* 87: 1180-1190.
12. Toro C, Rodés B, Poveda E, Soriano V (2003) Rapid development of subacute myelopathy in three organ transplant recipients after transmission of human T-cell lymphotropic virus type I from a single donor. *Transplantation* 75: 102-104.
13. Gonzalez-Perez MP, Muñoz-Juárez L, Cárdenas FC, Zarranz Imirizaldu JJ, Carranceja JC, et al. (2003) Human T-cell leukemia virus type I infection in various recipients of transplants from the same donor. *Transplantation* 75: 1006-1011.
14. Zarranz Imirizaldu JJ, Gomez Esteban JC, Rouco Ape I, Perez Concha T, Velasco Juanes F, et al. (2003) Post-transplantation HTLV-1 myelopathy in three recipients from a single donor. *J Neurol Neurosurg Psychiatry* 74: 1080-1084.
15. Kawano N, Shimoda K, Ishikawa F, Taketomi A, Yoshizumi T, et al. (2006) Adult T-cell Leukemia Development From a Human T-cell Leukemia Virus Type I Carrier After a Living-Donor Liver Transplantation. *Transplantation* 82: 840-843.
16. Guiteau JJ (2009) Transplantation of Human T-Cell Lymphoma Virus (HTLV) Positive Liver Allografts. Baylor College of Medicine: Houston.