

Heterotopic Ectopic Pregnancy after Assisted Reproductive Technology: Case Reports

Li X, Yue-Lan F, Yong-Chao Q, Le-Le C, He X, Wang T, Chan-Wei J, Lu D and Yan-Min M*

Department of Reproductive Medicine, Beijing Obstetrics and Gynecology Hospital, Capital Medical University, Beijing, P.R. China

Abstract

Objective: To study the characteristic of heterotopic pregnancy, we describe three different types of HPs observed at Beijing Obstetrics and Gynecology Hospital including concurrent ovarian and ipsilateral tubal ectopic pregnancies and an HP involving a caesarean section scar, which is rare, worldwide.

Design: Case report.

Setting: Clinic.

Patients: The first case was a 30-year-old woman diagnosed with concurrent tubal and ovarian pregnancy. The second was a 36-year-old woman of caesarean scar pregnancy. The last patient was diagnosed as heterotopic pregnancy.

Interventions: The three patients all underwent emergency surgery.

Main outcome measure(s): The three patients recovered fluently. In the third case, the patient gave birth to an infant at 38 weeks of gestation.

Result and Discussion: Heterotopic pregnancy (HP) is often defined as the presence of simultaneous pregnancies at two different implantation sites. Most cases include the coexistence of intrauterine and ectopic pregnancies. Due to the prevalence of assisted reproductive technology, including intrauterine insemination (IUI), ovarian stimulation and *in vitro* fertilization (IVF), the rate of HP is increasing. However, a systemic classification of HP is lacking.

Conclusion: The three cases suggest three different types of HP that can occur after assisted reproduction technology. Early diagnosis is essential to avoid maternal morbidity and mortality.

Keywords: Heterotopic pregnancy; Ectopic pregnancy; Assisted reproductive technology

Introduction

Heterotopic pregnancy (HP) is a rare and life-threatening condition. It is uncommon in spontaneous conception cycles, occurring in 1:30,000 pregnancies [1]. An increased rate of heterotopic pregnancies, approximately 152 of 100,000 cases, has been reported after using assisted reproductive technology [2-4].

The first published case of HP was a unilateral tubal pregnancy reported by De Ott in 1891 [5]. Since then, approximately 250 twin ectopic pregnancies have been reported, most of which were concomitant intrauterine and extrauterine pregnancies.

With the increase in the number of caesarean sections, the incidence of caesarean scar pregnancy (CSP) is increasing. A caesarean scar, combined with an ectopic pregnancy or intrauterine pregnancy, is termed a heterotopic caesarean scar pregnancy (HCSP). According to a 2018 review, when searching a list of keywords, including "ectopic pregnancy", "caesarean section scar", and "heterotopic caesarean pregnancy", fewer than 25 cases have been reported [6]. Even if this condition is rare worldwide, there is no doubt that the rate of HCSP will increase in the future with the development of assisted reproductive technology.

HP symptoms usually include pain, an extrauterine pelvic mass, amenorrhea, and suspicion of pregnancy [7]. In this paper, we present three cases of HP at Beijing Obstetrics and Gynecology Hospital.

Case Reports

A 30-year-old woman was referred to our hospital for suspected

ectopic pregnancy and bleeding. She had not been pregnant for 2 years. She had undergone a fresh embryo transfer (ET) 34 days before admission, and two embryos were transferred under ultrasound guidance. She had a history of transcervical hysteroscopic endometrial ablation, and she denied any history of pelvic inflammatory disease or intrauterine device use. A physical examination showed tenderness in the right pelvic region. Her serum human chorionic gonadotropin (hCG) level was 2261 mIU/ml. A transvaginal ultrasound scan showed an empty uterine cavity and a 40 mm echo-complex mass at the right adnexa. A 23 mm gestational sac was found. Free fluid was not observed. The sonographic findings and serum β -hCG level suggested an ectopic pregnancy. Emergency laparoscopy was performed with a pre-diagnosis of ectopic pregnancy. Exploration showed only 20 ml of blood in the abdominal cavity. The uterus, right fallopian tube, and left ovary appeared normal. The right ovary was enlarged, with a 5 cm intact mass. However, a complete ampullary ectopic pregnancy of 2 cm in diameter was also found in the left tube. A left linear salpingostomy of the left fallopian tube and wedge resection of the right ovary were performed.

*Corresponding author: Yan-Min M, Department of Reproductive Medicine, Beijing Obstetrics and Gynecology Hospital, Capital Medical University, Beijing 100026, P.R. China, Tel: +86 10 8639 1449; E-mail: minyanma@163.com

Received October 16, 2018; Accepted October 22, 2018; Published October 23, 2018

Citation: Li X, Yue-Lan F, Yong-Chao Q, Le-Le C, He X, et al. (2018) Heterotopic Ectopic Pregnancy after Assisted Reproductive Technology: Case Reports. J Clin Case Rep 8: 1180. doi: [10.4172/2165-7920.10001180](https://doi.org/10.4172/2165-7920.10001180)

Copyright: © 2018 Li X, et al. This is an open-access article distributed under the terms of the Creative Commons Attribution License, which permits unrestricted use, distribution, and reproduction in any medium, provided the original author and source are credited.

The pathologic diagnosis was reviewed, and concurrent tubal and ovarian pregnancy was confirmed.

A 36-year-old, married, non-smoking, non-alcoholic woman was referred to our emergency room for further management of a HP. The patient had experienced secondary infertility for 6 years, and ultrasound findings indicated polycystic ovaries. The patient presented with acute abdominal pain and vaginal bleeding. The bleeding had increased in volume, and she had passed an increasing number of clots. She had a history of pulmonary tuberculosis. Upon physical examination, the patient was cooperative and well oriented, with stable vital signs. An abdominal examination revealed mild tenderness in the left lower abdomen. Her quantitative hCG level was 11,903.5 mIU/ml. A gestational sac (2 × 3 cm) with cardiac activity and a yolk sac were located in her uterine scar area, and a 2 × 2 cm yolk sac was located in her left adnexa. Her right ovary was normal. Bilateral uterine artery embolization (UAE) was performed with the intention of controlling uterine bleeding and preserving the uterus. One day after UAE, hysteroscopy combined with laparoscopy was proposed for the 95 patients. The operative findings included a 2 × 2 × 2 cm red tissue mass on the anterior wall of her uterus and an enlarged ampullary region of the fallopian tube. The gestational products were removed from the uterus and left fallopian tube. Intraoperative and postoperative bleeding was minimal. Histopathology reports confirmed the presence of decidual tissue in both gestational products. The patient recovered well after the surgery, and her hCG level was normal at 4 weeks postoperatively.

A 35-year-old woman visited our clinic due to infertility. The couple had complained of infertility for 10 years, since after her first pregnancy. The couple was sent to the *in vitro* fertilization-embryo transfer (IVF-ET) programme. On day 4 after oocyte retrieval, two embryos were transferred into the uterus. Two weeks later, pregnancy was confirmed when the female patient's serum hCG level reached 184,172.8 IU/L. However, an ultrasound scan performed at 5 gestational weeks showed a gestational sac (4.3 × 4.6 cm) with cardiac activity, and another gestational sac (2.7 × 2.0 cm) with cardiac activity was in her right uterine cornu. The couple was informed about the foetal reduction protocol. Selective foetal reduction was performed on day 66 of the pregnancy. Under ultrasound guidance, along with a transducer, a 20-gauge needle was inserted into the right uterine horn, injecting diazepam (5 mg) into the yolk sac. The other foetus inside the uterine cavity was intact. The next day, an examination revealed that the remaining foetus was normal. A live female infant was delivered by caesarean section at 38 weeks of gestation.

Discussion

HP is defined as the presence of simultaneous pregnancies in two different implantation sites, generally one intrauterine pregnancy and one extrauterine pregnancy (usually tubal) [8]. A significant increase in HP has been reported after the use of IVF, ranging from 2.1 to 8.6% [9,10]. The three patients in this article all had a history of assisted reproductive technology. However, to date, there has been no clear classification of HP. Here, we summarized the characteristics of HP, according to the location of the gestation sac. The incidence differs for different types of HP.

Intrauterine pregnancy combined with extrauterine pregnancy

HP is defined as a combined extrauterine and intrauterine pregnancy. The second patient in our paper represents a typical case of this type of HP. The reviews of this type of HP are well-documented.

When the extrauterine gestational sac is in the interstitium of the fallopian tube, it is challenging to treat and preserve an intrauterine pregnancy. Jiang Y et al., investigated the pregnancy outcomes of 17 women diagnosed with heterotopic interstitial pregnancy. They concluded that laparoscopic surgery is effective and favorable for long-term pregnancy outcomes [11]. A clinical analysis of 50 cases compared the clinical characteristics, prenatal diagnosis and management of patients [12]. The study concluded that ovulation induction and ET are significantly related to an increase in HP. Even if the patient underwent bilateral salpingectomy or tubal obstruction, HP could not be excluded. Lyu JT et al., summarized the clinical features of 40 HP patients after IVF-ET. They suggested that transvaginal ultrasonography (TVS) at day 27 after ET is helpful for the diagnosis of HP [13].

Extrauterine pregnancy combined with extrauterine pregnancy

This condition is life-threatening, with an estimated incidence of 1 in 20,000 spontaneous pregnancies [14]. This condition is rarely reported. The second case in our paper represents this type of HP. The first case report of HP worldwide was a unilateral twin tubal pregnancy, reported by De Ott [5]. Since then, an average of one case per year has been reported in the literature [15,16]. Even fewer cases of concurrent tubal and ovarian ectopic pregnancy occur. The case reported in our paper is the first case of tubal pregnancy combined with contralateral ovarian pregnancy. The management of this type of HP primarily consists of surgery. An early diagnosis is helpful to avoid patient mortality and morbidity.

HSCP

HSCP is rare. We summarized the HSCP cases reported in PubMed (approximately 19 cases). Except for 1 case reported by Dueñas-García et al, in which the patient did not desire to continue with the intrauterine pregnancy, most cases have resulted in successful pregnancy outcomes. The following (Figure 1) summarizes the occurrence and management of HSCP.

As shown in Table 1, 6 of these cases occurred after IVF-ET. The fetal reduction of viable pregnancies with local injection of potassium chloride is a common practice for management of HSCP. The intrauterine material cannot be affected by this surgery (Figure 2). This conclusion is limited because the number of cases reported is small, and reports of CSP combined with ectopic pregnancy, such as the third case in our paper, are lacking. Additional studies have shown that fetal reduction can be associated with an increased risk of abdominal pain, pregnancy loss, excessive vaginal bleeding, and prematurity [17-

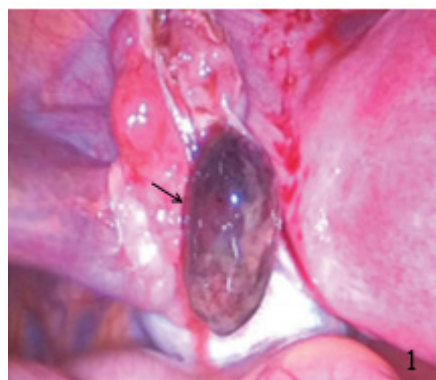

Figure 1: Shows the enlarged fallopian tube.

Management and occurrence of HCSP				
Litwicka K et al.	Spontaneous	Foetal reduction	2014	Successful management of a triplet heterotopic caesarean scar pregnancy after <i>in vitro</i> fertilization-embryo transfer
Wang CJ et al.	IVF	Hysteroscopic-directed evacuation of CSP	2010	Hysteroscopic management of heterotopic caesarean scar pregnancy
Kim ML et al.	Spontaneous	Expectant management	--	Successful full-term twin deliveries in heterotopic caesarean scar pregnancy in a spontaneous cycle with expectant management
Salomon LJ et al.	Unknown	Foetal reduction	2003	Successful management of a heterotopic caesarean scar pregnancy: Potassium chloride injection with preservation of the intrauterine gestation: Case report
Vetter MH et al.	Spontaneous	Resection of an ectopic pregnancy through mini-laparotomy	2016	Surgical management of a heterotopic caesarean scar pregnancy with preservation of an intrauterine pregnancy
Bai XX et al.	IVF	Expectant management	2012	Expectant management of heterotopic caesarean scar pregnancy
*Dueñas-Garcia et al.	Spontaneous	MTX	2011	Heterotopic caesarean scar pregnancy associated with a levonorgestrel-releasing intrauterine device
Uqurlucan FG et al.	Spontaneous	Foetal reduction	2012	Management of caesarean heterotopic pregnancy with transvaginal ultrasound-guided potassium chloride injection and gestational sac aspiration and review of the literature
Taskin S et al.	Spontaneous	Foetal reduction	2009	Heterotopic caesarean scar pregnancy: How should it be managed?
Demirel LC et al.	Spontaneous	Laparoscopic surgery	2009	Laparoscopic management of heterotopic caesarean scar pregnancy with preservation of intrauterine gestation and delivery at term: Case report
Gupta R et al.	IVF	Foetal reduction	2010	Heterotopic caesarean section scar pregnancy
Wang CN et al.	IVF	Foetal reduction	2007	Successful management of heterotopic caesarean scar pregnancy combined with intrauterine pregnancy after <i>in vitro</i> fertilization-embryo transfer
Piotr Czuczwar et al.	Spontaneous	Foetal reduction	2016	Successful treatment of spontaneous heterotopic caesarean scar pregnancy by local potassium chloride injection with preservation of the intrauterine pregnancy
Armbrust R et al.	IVF	Foetal reduction	2014	Operative therapy for heterotopic scar pregnancy and successful birth of the intrauterine foetus – case report and review of the literature
Hsieh BC et al.	IVF	Foetal reduction	2004	Heterotopic caesarean scar pregnancy combined with intrauterine pregnancy successfully treated with embryo aspiration for selective embryo reduction: Case report
Paoletti D et al.	Spontaneous	Foetal reduction	2011	A heterotopic pregnancy involving a caesarean section scar
Vikhareva O et al.	Spontaneous	Expectant management	2018	Normal vaginal delivery at term after expectant management of heterotopic caesarean scar pregnancy: A case report
Miyaque AH et al.	spontaneous	Foetal reduction	2017	Treatment of heterotopic caesarean scar pregnancy complicated with post termination increase in size of residual mass and morbidly adherent placenta
Lincenberg KR et al.	Spontaneous	Uterine repair	2016	Uterine rupture with caesarean scar heterotopic pregnancy with survival of the intrauterine twin

*The patient did not desire to continue with the intrauterine pregnancy.

Table 1: The occurrence and management of recent HCSP reports.

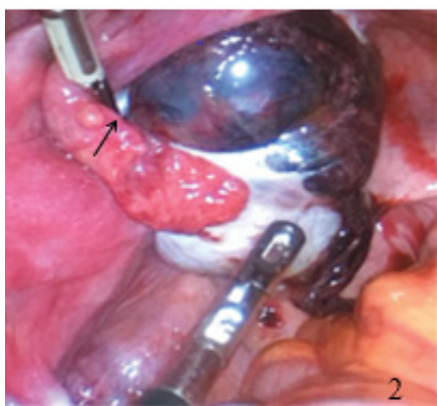


Figure 2: Shows the mass on the ovary.

22]. With the development of vascular surgery, UAE has become an ideal alternative to control uterine bleeding. However, it is unknown whether the methotrexate used in UAE has additional effects on the ovaries. Hence, proper management should be chosen based on the clinical conditions.

Conclusion

Attention should be directed towards select cases of idiopathic infertility, as heterotopic ectopic pregnancy may occur. Although many

reviews have summarized the characteristics of HP, more detailed classification is necessary for clinicians to determine further treatment. The mechanism of HP is unknown. Considering the possible positive effects of seminal plasma on implantation is necessary.

References

- Arsala L, Danso D (2009) Antiretrovirals: Blepharoptosis: 2 case reports. J Invest Med High Impact Case Rep 1251: 8.
- Dor J, Seidmen DS, Levran D, Ben-Rafael Z, Ben-Shlomo L, et al. (1991) The incidence of combined intrauterine and extrauterine pregnancy after *in vitro* fertilization and embryo transfer. Fertil Steril 55: 833-834.
- Marcus SF, Macnamee M, Brnsden P (1991) Heterotopic pregnancies after *in vitro* fertilization and embryo transfer. Hum Reprod 164: 161-164.
- Jeon JH, Hwang YI, Shin IH, Park CW, Yang KM, et al. (2016) The risk factors and pregnancy outcomes of 48 cases of heterotopic pregnancy from a single center. J Korean Med Sci 31: 1094-1099.
- De Ott (1891) A case of unilateral tubal twin gestation. Gynecol Obstet 36: 304.
- Yu H, Luo H, Zhao F, Liu X, Wang X (2016) Successful selective reduction of a heterotopic cesarean scar pregnancy in the second trimester: A case report and review of the literature. BMC Pregnancy Childbirth 16: 380.
- Mcelin TW, Boronow RC (1964) Tubo-ovarian pregnancy. Obstet Gynecol 24: 290-293.
- Paoletti D (2011) A heterotopic pregnancy involving a caesarean section scar. Austral J Ultrasound Med 14: 34-35.
- Clayton HB, Schieve LA, Peterson HB, Jamieson DJ, Reynolds MA, et al. (2006) Ectopic pregnancy risk with assisted reproductive technology procedures. Obstet Gynecol 107: 595-604.

10. Sueldo CM, Budinetz T, Maslow BS, Nulsen J, Engmann L, et al. (2014) Concurrent ovarian and ipsilateral tubal ectopic pregnancies after a double embryo transfer: A case report. *J Assist Reprod Gen* 31: 1643-1646.
11. Jiang Y, Chen J, Zhou H, Zheng M, Han K, et al. (2018) Management and obstetric outcomes of 17 heterotopic interstitial pregnancies. *BMC Pregnancy Childbirth* 18: 78.
12. Wu Z, Zhang X, Xu P, Huang X (2018) Clinical analysis of 50 patients with heterotopic pregnancy after ovulation induction or embryo transfer. *Eur J Med Res* 23: 17.
13. Lyu J, Ye H, Wang W, Lin Y, Sun W, et al. (2017) Diagnosis and management of heterotopic pregnancy following embryo transfer: Clinical analysis of 55 cases from a single institution. *Arch Gynecol Obstet* 296: 85-92.
14. Goswami D, Agrawal N, Arora V (2015) Twin tubal pregnancy: A large unruptured ectopic pregnancy. *J Obstet Gynaecol Res* 41: 1820-1822.
15. Sherer DM, Liberto L, Jr WJ (1990) Preoperative sonographic diagnosis of a unilateral tubal twin gestation with documented fetal heart activity. *J Ultrasound Med Official J Am Instit Ultrasound Med* 9: 729-731.
16. Kim CI, Lee TY, Park ST, Kim HB, Park SH (2018) A rare case of spontaneous live unilateral twin tubal pregnancy with both fetuses presenting with heart activities and a literature review. *Obstet Gynecol Sci* 61: 274-277.
17. Jurkovic D, Hillaby K, Woelfer B, Lawrence A, Salim R, et al. (2003) First-trimester diagnosis and management of pregnancies implanted into the lower uterine segment Cesarean section scar. *Ultrasound Obstet Gynecol Official J Inter Soc Ultrasound Obstet Gynecol* 21: 220-227.
18. Salomon LJ, Fernandez H, Chauveaud A, Doumerc S, Frydman R (2003) Successful management of a heterotopic Cesarean scar pregnancy: Potassium chloride injection with preservation of the intrauterine gestation: Case report. *Hum Reprod* 18: 189-191.
19. Monteagudo A, Minior VK, Stephenson C, Monda S, Timor-Tritsch IE (2005) Non-surgical management of live ectopic pregnancy with ultrasound-guided local injection: A case series. *Ultrasound Obstet Gynecol* 25: 282-288.
20. Michaels AY, Washburn EE, Pocius KD, Benson CB, Doubilet PM, et al. (2015) Outcome of cesarean scar pregnancies diagnosed sonographically in the first trimester. *J Ultrasound Med* 34: 595-599.
21. Alshelaly UE, Al-Mousa NH, Kurdi WI (2015) Obstetric outcomes in reduced and non-reduced twin pregnancies: A single hospital experience. *Saudi Med J* 36: 1122-1125.
22. Balaha MH, Amr MA, Elgilany AA, Alsheikh FM (2015) Obstetric and neonatal outcome of multifetal pregnancy reduction. *Middle East Fertil Soc J* 20: 176-181.