

Heart Failure with Preserved Ejection Fraction in Children without Congenital Heart Disease

Ju Hee Shin and Hee Joung Choi*

Department of Pediatrics, Keimyung University School of Medicine, Daegu, South Korea

Abstract

HF preserved EF (HFpEF) is not common in children but have been reported in patients with congenital heart disease and open heart surgery. In adult group, acute myocarditis can be presented as HFpEF. We report the HFpEF in children without underlying congenital heart disease, probably associated with acute myocarditis.

Keywords: Heart failure; Children; Diastolic function; Myocarditis

Introduction

Heart failure (HF) is usually observed to be caused by failure of ventricular contraction associated with reduced ejection fraction (EF). However, recently, HF with normal EF has become widely reported in adults, with an incidence of 40% to 70% in total HF patients [1]. Until now, only few cases of HF with preserved EF (HFpEF) in pediatric patients have been reported, and most cases of pediatric HFpEF were associated with congenital heart disease and open-heart surgery [2-5]. Herein, we report a case of HFpEF probably associated with acute myocarditis in children without underlying congenital heart disease.

Case Report

A 9-year-old boy with a 2-month history of abdominal pain was admitted at the Keimyung University Dongsan Medical Center. He had aggravated abdominal pain, dyspnea, orthopnea, facial edema, and weight gain for 3 days. Vital signs were stable without tachypnea. His blood pressure was 120/80 mmHg; pulse rate, 104/min; respiratory rate, 30–36/min, body temperature, 37.0°C; and pulse oximeter saturation, 99% in room air. On physical examination, heart and lung sounds were normal, and no jugular venous distension and hepatosplenomegaly were found. Chest radiography revealed pulmonary edema with both pleural effusions without cardiomegaly (CT ratio, 47.5%; Figure 1). Electrocardiography revealed normal sinus rhythm with no other abnormal finding. The N-terminal pro-B-type natriuretic peptide (NT-proBNP; 3,759 pg/mL) and creatinine kinase-MB levels (4.8 ng/mL) were increased, but the cardiac troponin I level was within the normal range (<0.017 ng/mL). The results of laboratory tests for tuberculosis and rheumatic disease were negative. The level of anti-streptolysin O (1.797 IU/mL) was increased, and polymerase chain reaction showed positive result for Norovirus G II; however, results of other tests for other causative bacteria or virus were all negative.

Echocardiography revealed a normal EF (76.6%) of the left ventricle (LV) with scanty pericardial effusion (3 mm in depth in the parasternal long-axis view). However, the enlarged left atrium (LA; left atrial aortic root ratio [LA/AO]=1.93, LA Z score=5.13) and elevated mitral E/e' ratio (17.2) represented a diastolic LV dysfunction. Cardiovascular magnetic resonance imaging (MRI) revealed normal LV contractility (EF=56%) with pericardial effusion but no evidence of focal myocardial infiltration, myocardial scar, and pericardial disease. However, a mild inflammatory response in the myocardium with edema, especially on the LV apex and anterior wall, was found. He did not undergo cardiac catheterization and cardiac biopsy.

The patient's facial edema and pleural effusion improved after

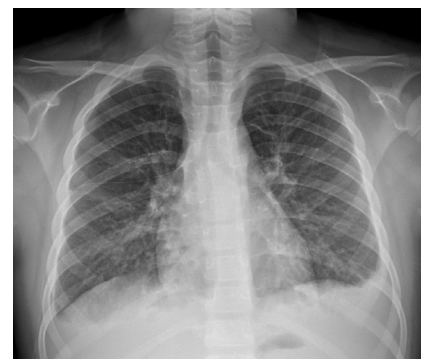


Figure 1: Chest radiograph of the patient on admission day.

Variables	HD 1	HD 3	HD 5	HD 8
NT-proBNP (pg/mL)	3,759	1,687	543	143
Creatinine kinase-MB (ng/mL)	4.8	1.5	1.1	1
Cardiac troponin-I (ng/mL)	<0.017	<0.017	<0.017	<0.017

HD: Hospital Day; NT-proBNP: N-Terminal Pro-B-Type Natriuretic Peptide.

Table 1: Laboratory data in hospital.

medication with diuretics. He did not complain of respiratory symptoms and was discharged on the ninth day of hospitalization. Serial echocardiography was performed at the outpatient department, and LV systolic and diastolic functions were normal after discontinuation of the medication. The serial laboratory and echocardiographic data are shown in Tables 1 and 2.

Discussion

The diagnostic criteria for HFpEF were as follows: (1) clinical signs or symptoms of HF; (2) evidence of normal or mildly abnormal LV

***Corresponding author:** Hee Joung Choi, Department of Pediatrics, Keimyung University School of Medicine, 56 Dalseong-ro, Jung-gu, Daegu 41931, South Korea, Tel: 82532507524; Fax: 82532507783; E-mail: joung756@dsmc.or.kr

Received January 23, 2018; Accepted February 05, 2018; Published February 09, 2018

Citation: Shin JH, Choi HJ (2018) Heart Failure with Preserved Ejection Fraction in Children without Congenital Heart Disease. J Cardiovasc Dis Diagn S2: 004. doi:10.4172/2329-9517.S2-004

Copyright: © 2018 Shin JH, et al. This is an open-access article distributed under the terms of the Creative Commons Attribution License, which permits unrestricted use, distribution, and reproduction in any medium, provided the original author and source are credited.

Variables	HD 1	HD 3	HD 5	HD 8
Left ventricle EF (%)	76.6	68.5	65	72
LA/AO	1.93	1.72	1.28	1.26
Left atrium Z score	5.13	4.55	2	1.86
Mitral E velocity (cm/sec)	1.34	1.17	1.02	0.97
Mitral A velocity (cm/sec)	0.78	0.76	0.58	0.48
Mitral E/A ratio	1.72	1.53	1.76	2.02
Mitral E velocity DT (msec)	218	161	182	160
Septal e' (cm/sec)	7.8	10.6	8.6	9.8
Lateral e' (cm/sec)	11.7	14.5	10.5	12.4
Mitral E/e' ratio	17.2	11.3	11.9	9.9

HD: Hospital Day; EF: Ejection Fraction; LA/AO: Left Atrial Aortic Root Ratio; E: Peak Early Diastole Mitral Inflow Velocity; A: Peak Late Diastole Mitral Inflow Velocity; DT: Deceleration Time; e': Peak Early Diastole Tissue Doppler Imaging Velocity.

Table 2: Echocardiographic data in hospital.

systolic function, and (3) evidence of abnormal LV diastolic function [6]. The incidence of HFpEF increases with older age and in females as they reach adulthood, with an overall incidence of approximately 1.1% to 5.5% [1]. The predisposing factors of HFpEF in adults were hypertension, atrial fibrillation, and several noncardiovascular diseases such as renal impairment, chronic lung disease, anemia, cancer, liver disease, peptic ulcer disease, and hypothyroidism [1]. HFpEF has been also reported in pediatric groups, including those with congenital aortic stenosis, hypertrophic cardiomyopathy, and restrictive cardiomyopathy [3-5]. One study that included pediatric patients who had undergone surgery for congenital heart disease demonstrated a 0.5% incidence of HFpEF [2]. These patients were mainly young children about 1 year of age who had concentric ventricular hypertrophy [2]. Furthermore, these HFpEF patients had significantly higher serum aldosterone levels and higher ratios of aldosterone level to BNP level than patients with HF with reduced EF [2]. In contrast to adult HFpEF, which has a high mortality rate of approximately 55% to 74%, pediatric HFpEF is transient and usually improved spontaneously [1,7].

Myocarditis presents with a wide range of symptoms, from no symptoms to cardiogenic shock [8]. Patients with acute myocarditis usually showed LV systolic failure with chamber enlargement; however, approximately 7% of patients with myocarditis showed LV diastolic failure in the adult group [9]. These patients usually showed infarct-like symptoms, and cardiac MRI is considered for a definite diagnosis of acute myocarditis [8]. Until now, no hypothesis has been proposed for the different presentations of myocarditis, that is, for explaining why some patients with acute myocarditis had diastolic dysfunction rather than the usual course of systolic dysfunction. In the pediatric group, acute myocarditis with restrictive pathophysiology in a 6-year-

old patient was reported [10]. The patient showed cardiomegaly and pulmonary edema on chest radiography, and restrictive LV dysfunction on echocardiography, which was confirmed as myocarditis by cardiac biopsy [10]. In our case, we did not perform cardiac biopsy, but the most probable cause of the LV diastolic dysfunction was acute myocarditis depending on cardiac MRI findings.

Conclusion

In conclusion, HFpEF can be found in children without underlying anatomical heart diseases, probably associated with acute myocarditis. In such a case, the subjective symptom was not severe as the usual course of acute myocarditis. LV diastolic failure should be considered in children without underlying anatomical heart diseases.

References

- Lam CS, Donal E, Kraigher-Krainer E, Vasan RS (2011) Epidemiology and clinical course of heart failure with preserved ejection fraction. *Eur J Heart Fail* 13: 18-28.
- Masutani S, Saiki H, Kurishima C, Ishido H, Tamura M, et al. (2013) Heart failure with preserved ejection fraction in children: hormonal imbalance between aldosterone and brain natriuretic peptide. *Circ J* 77: 2375-2382.
- Friedman KG, McElhinney DB, Rhodes J, Powell AJ, Colan SD, et al. (2013) Left ventricular diastolic function in children and young adults with congenital aortic valve disease. *Am J Cardiol* 111: 243-249.
- McMahon CJ, Nagueh SF, Pignatelli RH, Denfield SW, Dreyer WJ, et al. (2004) Characterization of left ventricular diastolic function by tissue Doppler imaging and clinical status in children with hypertrophic cardiomyopathy. *Circulation* 109: 1756-1762.
- Ntsinjana HN, Chung R, Ciliberti P, Muthurangu V, Schievano S, et al. (2017) Utility of cardiovascular magnetic resonance-derived wave intensity analysis as a marker of ventricular function in children with heart failure and normal ejection fraction. *Front Pediatr* 5: 65.
- Paulus WJ, Tschope C, Sanderson JE, Rusconi C, Flachskampf FA, et al. (2007) How to diagnose diastolic heart failure: a consensus statement on the diagnosis of heart failure with normal left ventricular ejection fraction by the Heart Failure and Echocardiography Associations of the European Society of Cardiology. *Eur Heart J* 28: 2539-2550.
- Nakagawa M (2013) Clinical characteristics of heart failure with preserved ejection fraction in children. *Circ J* 77: 2249-2250.
- Caforio AL, Pankuweit S, Arbustini E, Basso C, Gimeno-Blanes J, et al. (2013) Current state of knowledge on aetiology, diagnosis, management, and therapy of myocarditis: a position statement of The European Society of Cardiology Working Group on Myocardial and Pericardial Diseases. *Eur Heart J* 34: 2636-2648.
- Pinamonti B, Alberti E, Cigalotto A, Dreas L, Salvi A, et al. (1988) Echocardiographic findings in myocarditis. *Am J Cardiol* 62: 285-291.
- Kimball TR, Witt SA, Marasco LA, Bushman CJ, Schwartz DC, et al. (1994) A unique echocardiographic presentation of acute myocarditis: Restrictive pathophysiology. *J Am Soc Echocardiogr* 7: 187-189.