

H. pylori Gastritis Presenting as Multiple Black Macules in the Gastric Antrum

Tharani Sundararajan¹, Sheng Chen², Madhusudhanan Jegadeesan³ and Ramprasad Jegadeesan^{4*}

¹Department of Internal medicine, SIU School of Medicine, Springfield, Illinois, United States

²Department of Pathology, Memorial Medical Center, Springfield, Illinois, United States

³Department of Surgical Gastroenterology, Apollo Specialty Hospitals, Tamil Nadu, India

⁴Department of Gastroenterology, SIU School of Medicine, Springfield, IL, United States

About the Study

A 59-year-old male with past medical history of asthma, hypertension, type 2 diabetes mellitus, hyperlipidemia and coronary artery disease presented with complaints of intermittent epigastric pain, nausea and vomiting for past four months. CT of abdomen and pelvis showed moderate circumferential thickening in segments of mid small bowel and thickening of the lower esophagus. He underwent push enteroscopy which showed multiple 2-8 mm black macular lesions in the gastric antrum (red arrow in Figures 1 and 2) along with normal appearing small bowel and esophagus. Biopsies of the black macular lesions revealed evidence of *H. pylori* gastritis along with surface erosion and mild gastric atrophy (red arrow in Figure 3) and were negative for melanoma, iron deposition or melanin deposition. Small bowel biopsies were normal. *H. pylori* infection causes peptic ulcer disease, acute and chronic gastritis, atrophic gastritis, usually with gastric intestinal metaplasia and dysplasia, and gastric cancer, especially intestinal-type.[1,2].

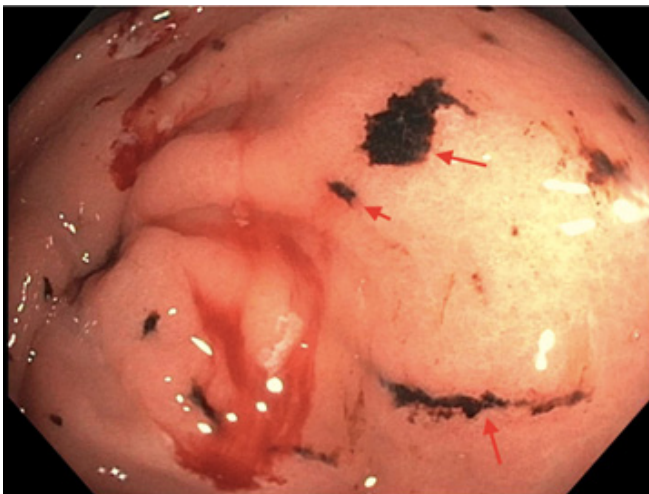


Figure 1. Multiple black macular lesions in the stomach (red arrows).

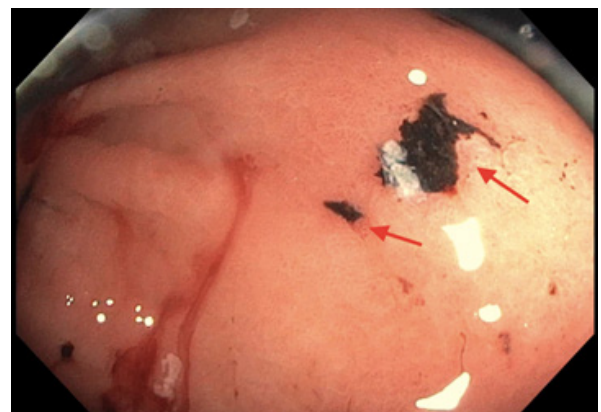


Figure 2. A large black macular lesion in the gastric antrum (red arrows).

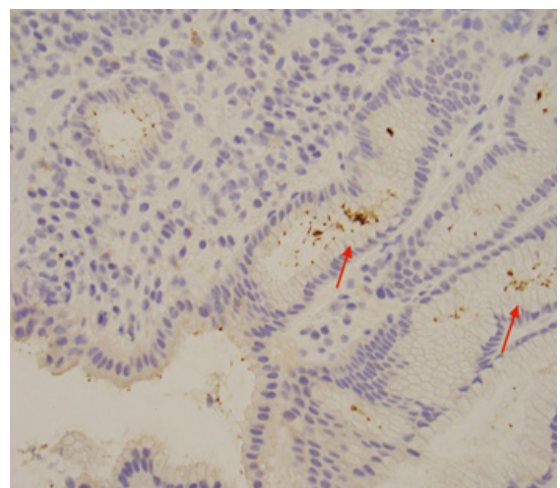


Figure 3. Evidence of *H. pylori* causing surface erosion (red arrows).

*Address for Correspondence: Jegadeesan Ramprasad, Department of Gastroenterology, SIU School of Medicine, Springfield, IL, United States; E-mail: drramprasad18@gmail.com

Copyright: © 2021 Sundararajan T, et al. This is an open-access article distributed under the terms of the Creative Commons Attribution License, which permits unrestricted use, distribution, and reproduction in any medium, provided the original author and source are credited.

Received: March 02, 2021; Accepted: March 16, 2021; Published: March 23, 2021

Informed Consent

Informed consent was obtained from the patient to submit the images.

Conflict of Interest Disclosure

Guarantor of the article

Ramprasad Jegadeesan will be the guarantor of the submitted image. He has access to and control of the images submitted.

Specific author contributions

Tharani Sundararajan: Author contributed in literature review, image collection and associated case information, drafting the manuscript. The author has revised and agree with the final image manuscript submitted.

Sheng Chen: Author has contributed in pathology image collection, review of the pathology slide. Author has critically revised and approved the image article for submission.

Madhusudhanan Jegadeesan: Author has contributed in image manuscript draft revision and he has approved the final manuscript submitted.

Ramprasad Jegadeesan: Author contributed in the planning of the image article. He revised and approved the final image manuscript prior to submission.

Financial Support

There is no financial support for this submitted image manuscript.

Potential Competing Interests

All authors have declared no conflicts of interest with the manuscript submitted.

References

1. Correa, Pelayo. "Helicobacter Pylori and Gastric Carcinogenesis." *Am J Surg Pathol* 19(1995):37-43.
2. Huang, Jia-Qing, Subbaramiah Sridhar, Ying Chen and Richard Hunt. "Meta-analysis of the Relationship between Helicobacter Pylori Seropositivity and Gastric Cancer." *Gastroenterology* 114(1998):1169-1179.

How to cite this article: Sundararajan, Tharani, Sheng Chen, Madhusudhanan Jegadeesan and Ramprasad Jegadeesan . "H. pylori Gastritis Presenting as Multiple Black Macules in the Gastric Antrum". *Clin Gastro J* 6(2021):141