

Gastroenterology 2020- Gynecomastia Treatment by Lyposuction with gland excision and H.H Method

Dr. Haider Ali Muslim AL Rahmahi, Lecturer in college of medicine –Wasit university

Abstract

Background:

Gynecomastia (GM) is benign enlargement of male breast (glandular enlargement with fat accumulation we classify in 6 grade depend on size and shape of breast .all cases was treated surgically as combine of gland excision and liposuction and added new method HH (Haider and Husam)method which is specific for grade 5 and 6 GM

Methods: From 2013to 2018, a chart review was performed for 300 patients. Preoperative examination included endocrine and urological examination and exclusion of other pathological conditions. The surgical technique consisted of liposuction through small incision in lateral side of breast ,combine with gland excision by sub areolar incision and sometime HH method depend on grade of gynecomastia.

Results:

Total number of patient 300 cases all of them under want combination of liposuction and gland excision with drain keep for about 8 hours .

Recurrent rate very rare and complication like infection or areolar necrosis also rare and 9 case only suffering from early postoperative bleeding and 22 case develop seroma within 2 weeks.

Conclusions:

This analysis data that include treatment of GM grade 1-6 is performed by liposuction combined with subcutaneous resection of the glandular tissue by sub areolar incision the procedure had low rate of complications and excellent patients satisfaction about the result. Preoperative follow up is important to rule out and prevent specific complication of procedure and to exclude diseases or

malignancy causing the GM as all gland sent to histopathology

Keywords

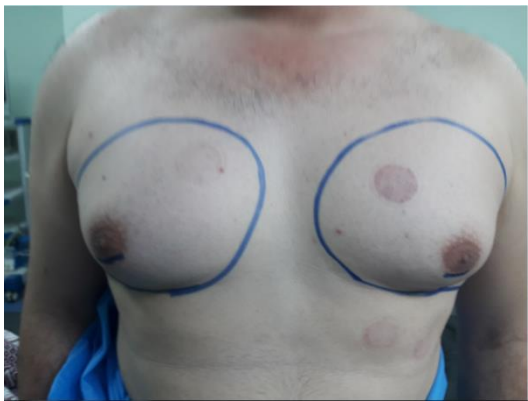Gynecomastia , HH method ,liposuction ,gland excision ,surgery ,combine treatment .

Introduction Gynecomastia (GM) is a common condition but with variable severity that occurs in men at all ages and refers to a benign condition of breast enlargement with benign glandular proliferation of various causes. It can be found at autopsy in 40-55% of all men [1,2,3,4,5]. GM most often presents bilaterally, although it can occur asymmetrically. Patients with GM most frequently present suffering from aesthetic or psychological symptoms [6]. Three peaks in the prevalence of palpable GM are described: The first one occurs in infants, caused by high materno-placental estrogen levels, and regresses in the first weeks after birth [7]. The second peak appears during puberty between the ages of 13 and 14 years, with a high rate of regression before the 17th year of life [8,9,10]. This transient form is related to the hormonal changes during puberty, which shows an earlier peak of estrogen before testosterone reaches its peak levels. The third peak occurs in men between 50 and 80 years of age related to diverse conditions [4]. Besides physiological categories, GM can be categorized by the triggers (25% persistent pubertal GM, 10-25% drug induced, 8% cirrhosis or malnutrition, 10% male hypogonadism, 3% testicular tumors, 1.5% hyperthyroidism, 1% chronic renal insufficiency, 25% idiopathic) [11]. GM results from an increased volume of glandular tissue or adipose tissue (pseudogynecomastia) or a mixture of both. All causes share an

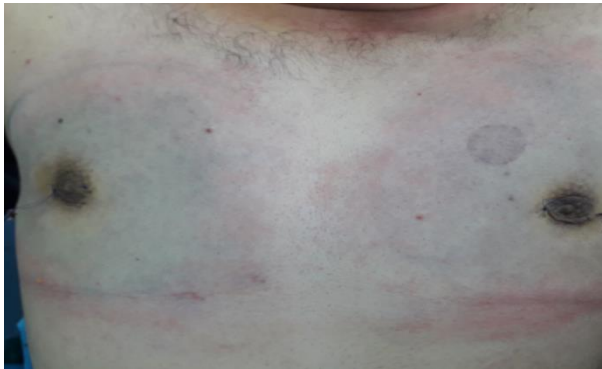Volume 11 Issue 5

imbalance of androgens and estrogens with a decreased testosterone-to-estradiol ratio, which directly affects the breast tissue [12]. Altered ratios of androgens and estrogens or the increased sensitivity of breast tissue to normal circulating estrogen levels gives rise to ductal hyperplasia, elongation and branching of the ducts correlated with proliferation of fibroblasts and neovascularization [13,14], which altogether form the clinical appearance of GM

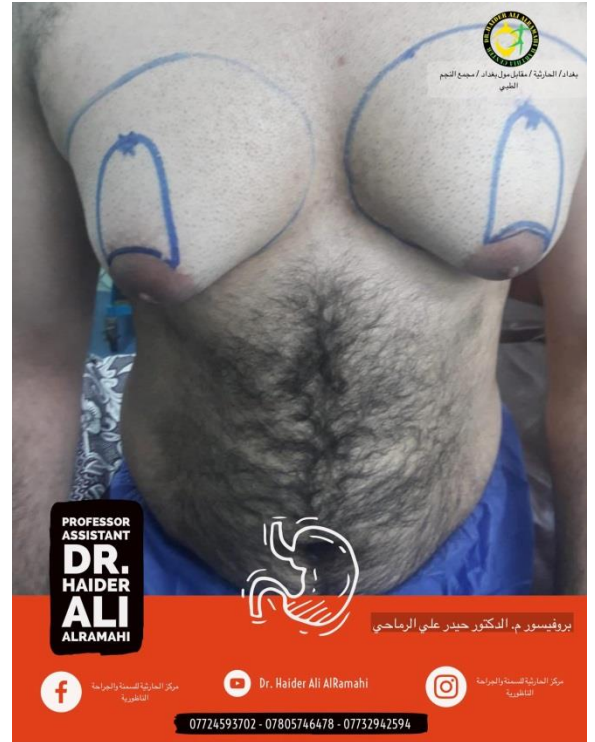
Fig. 1



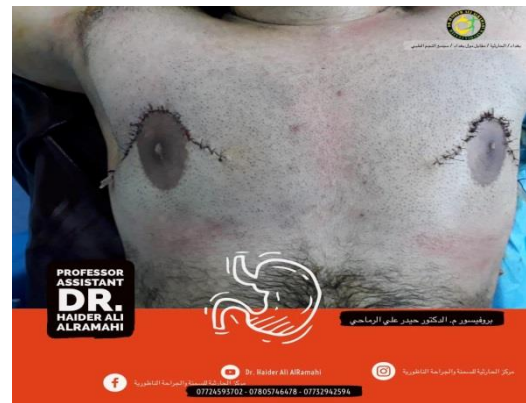Before (1)



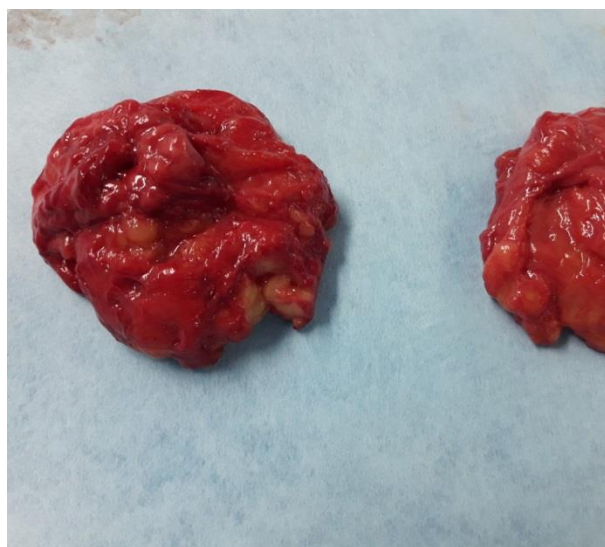After (1)



Before(2)



After(2)



Gland of breast

All pictures show the same patient before and after. In all cases, a bilateral gland excision and a bilateral liposuction were performed.

the classification of GM

type1: puffy look of the nipple coin like.

- Type 2: more extreme amount of glandular tissue and fat. as, fatty feeling in the outer zones.
- Type 3: includes breast sagging.
- Type 4: excess breast tissue sags below the chest fold, and the breasts look like a woman's breasts.
- Type 5: A more extreme degree of sagging, under armpits, and may extend toward the back.
- Type 6: the nipple appearing at the bottom of a large amount of saggy breast tissue.

most often used [15]. It groups patients into categories according to the size of the GM. Group I is characterized by minor but visible breast enlargement without skin redundancy. Group IIA features moderate breast enlargement without skin redundancy. Group IIB shows moderate breast enlargement with minor skin redundancy. Group III is characterized by gross breast enlargement with skin redundancy that simulates a pendulous female breast. Patients in groups I and II do not require skin excision during potential surgery, but the breast development associated

with group III is so marked that excess skin must be removed. Therapy of GM depends on several factors including its duration, grade, etiology, and the presence or absence of clinical symptoms. Treatment options include drug therapy and surgical removal of breast glandular tissue [16,17]. After a persistence of 12 months or longer, GM is likely to have reached the fibrotic status, in which conservative treatment is not effective.

The aim of this study was to analyze the surgical strategies in GM grade I-II, their clinical outcome and, based on this data, the development of an algorithm for surgical treatment.

Patients and Methods

Between 2013 and 2018, we surgically treated 300 patients with GM.

All patients underwent pre surgical workup like a physical examination, and investigation and sometime ultrasound to breast. If any abnormalities we found so send the patient to MRI to breast and some time to abdomen or fine needle aspiration from the testis and other laboratory workup about hormonal assessment of the patient.

Surgical Technique

Subcutaneous fatty tissue area of the breast was infiltrated with normal saline 0.9% solution 500 cc with one ampule of adrenaline [18]. Under guide monitoring of anastatist for any arhythmia of change in cardiac condition [19]. One stab incisions in lateral side near anterior axillary line for infiltration then for liposuction the breast by veser or traditional method ,complete clear the area and also below the gland to be dissected easy without use cattery unibolar .

This procedure for all grade of gynecomastia .

After finishing the liposuction then sub areolar incision to excision the gland very gentle release of the gland with secure haemostasis without need for bipolar and routinely we put

corregate drain from the side of liposuction cannula for about 6-8 hours.

The size of liposuction cannula its about 4 -6 mm.

For grade 4 GH we do small skin excision below the areola look like < > on both side of areola .

For grade 5 and 6 we do my method name HH method (Haider ,Husam) by which we do liposuction as usual then supra areolar incision look like inverted - U shape to elevate the areola up to 4 intercostal area; slightly lateral to mid clavicular line and also we put corregate drain from side of liposuction cannula then the wound closed by 3/0 PDS and drain was keep for about 8 hours to avoid any harmatoma .

In all procedure we advice the patient to wear chest corsea for about 4 to 8 weeks to avoid redundant skin appear and also to avoid any seroma.

Results

Clinical data from 300 patients all cases bilateral gynecomastia mean age was 34 years (rang from 14 to 55) and mean body mass index about 25 – 35% all of the patients under want liposuction and gland excision under general anaestasia for about one to one and half hour and discharge to home in the same day on in the next day after drain remove and sure no any collection of haematoma .

Postoperatively no pain only parastesia remain for about 3 to 8 weeks .

9 cases suffering from immediate haematoma after 2 -4 hours and immediate evacuation was done .

33 cases was suffered from seroma after 10 days and aspiration was done for one time only with covering antibiotic and compression of chest by coarsa.

Only one case develop areolar necrosis on one side only treated conservatively .

All gland after excision sent to histopathology no any case of malignant report

And no any case of wound infection

Discussion

Surgery is the best way to treatment of gynecomastia in man start from grad one to grad six the procedure include combination of liposuction and gland excision or subcutaneous mastectomy[20] the duration of operation about one hour and drain routinely was keep for a few hours follow by compression of breast to avoid any collection of fluid like blood or serous[21] the postoperative complication are rare as infected wound or bleeding or areolar necrosis and recurrent [22]some time asymmetrical of right and left breast occure postoperatively in 3 -4 weeks so need to simple liposuction under local anestathiasia or mesotherapy lipolysis injection it benefit[23].

The conservative treatment may be trail in early stage of GM combine with psychological support [24].some time we do operation to early stage of GM duo to aesthetic cousee [25].

The operation cost its not expensive it slightly depend on stage of GM.

Again we strongly recommended to do sub areolar gland excision to all stage of GM combine with liposuction.

Patient with drags that cause GM should be stop these drags or change to other type of medication [26] Nowadays with elevated the body awareness will raise the discussion and curve toward surgical treatment of GM and will be raise more in future .

References

1. Braunstein GD: Clinical practice. Gynecomastia. N Engl J Med 2007;357:1229-1237.

2. Rahmani S, Turton P, Shaaban A, Dall B: Overview of gynecomastia in the modern era and the Leeds Gynaecomastia Investigation algorithm. *Breast J* 2011;17:246-255.
3. Ley SJ: Cardiac surgery in an era of antiplatelet therapies: generating new evidence. *Reflect Nurs Leadersh* 2002;28:35.
4. Georgiadis E, Papandreou L, Evangelopoulou C, et al.: Incidence of gynaecomastia in 954 young males and its relationship to somatometric parameters. *Ann Hum Biol* 1994;21:579-587.
5. Nuttall FQ: Gynecomastia as a physical finding in normal men. *J Clin Endocrinol Metab* 1979;48:338-340.
6. Rosen H, Webb ML, DiVasta AD, Greene AK, Weldon CB, Kozakewich H, Perez-Atayde AR, Labow BI: Adolescent gynecomastia: not only an obesity issue. *Ann Plast Surg* 2010;64:688-690.
7. Schmidt-Voigt J: Brustdrüsenanschwellungen bei männlichen Jugendlichen des Pubertätsalters (Pubertätsmakromastie). *Z Kinderheilkd* 1941;62:590-606.
8. Moore DC, Schlaepfer LV, Paunier L, Sizonenko PC: Hormonal changes during puberty: V. Transient pubertal gynecomastia: abnormal androgen-estrogen ratios. *J Clin Endocrinol Metab* 1984;58:492-499.
9. Harlan WR, Grillo GP, Cornoni-Huntley J, Leaverton PE: Secondary sex characteristics of boys 12 to 17 years of age: the U.S. Health Examination Survey. *J Pediatr* 1979;95:293-297.
10. Lee PA: The relationship of concentration of serum hormones to pubertal gynecomastia. *J Pediatr* 1995;86:212-215.
11. Braunstein GD: Gynecomastia. *N Engl J Med* 1993;328:490-495.
12. Mathur R, Braunstein GD: Gynecomastia: pathomechanisms and treatment strategies. *Horm Res* 1997;48:95-102.
13. Nicolis GL, Modlinger RS, Gabrilove JL: A study of the histopathology of human gynecomastia. *J Clin Endocrinol Metab* 1971;32:173-178.
14. Bannayan GA, Hajdu SI: Gynecomastia: clinicopathologic study of 351 cases. *Am J Clin Pathol* 1972;57:431-437.
15. Simon BE, Hoffman S, Kahn S: Classification and surgical correction of gynecomastia. *Plast Reconstr Surg* 1973;51:48-52.
16. Gikas P, Mokbel K: Management of gynaecomastia: an update. *Int J Clin Pract* 2007;61:1209-1215.
17. Gruntmanis U, Braunstein GD: Treatment of gynecomastia. *Curr Opin Investig Drugs* 2001;2:643-649.
18. Venkataram J, Venkataram M: Liposuction and the cutaneous surgeon. *J Cutan Aesthet Surg* 2013;6:129-131.
19. Klein JA: Tumescence technique for regional anesthesia permits lidocaine doses of 35 mg/kg for liposuction. *J Dermatol Surg Oncol* 1990;16:248-263.
20. Samdal F, Kleppe G, Amland PF, Abyholm F: Surgical treatment of gynaecomastia. *Scand J Plast Reconstr Hand Surg* 1994;28:123-130.
21. Gasperoni C, Salgarello M, Gasperoni P: Technical refinements in the surgical treatment of gynaecomastia. *Ann Plast Surg* 2000;44:455-458.
22. Courtiss EH: Gynecomastia: analysis of 159 patients and current recommendations for treatment. *Plast Reconstr Surg* 1987;79:740-750.
23. Lewis CM: Lipoplasty: treatment for gynaecomastia. *Aesthetic Plast Surg* 1985;9:287-292.
24. Rosenberg GJ: Gynecomastia: suction lipectomy as a contemporary solution. *Plast Reconstr Surg* 1987;80:379-385.
25. Rosenberg GJ: A new cannula for suction removal of parenchymal tissue of gynaecomastia. *Plast Reconstr Surg* 1994;94:548-551.
26. Samdal F, Kleppe G, Abyholm F: A new suction-assisted device for removing glandular gynaecomastia. *Plast Reconstr Surg* 1991;87:383-384.

Note : This work is shortly presented at
International Conference on Gastroenterology

and Liver on March 18-19, 2020 at
Amsterdam, Netherlands