

Groin Pain Caused by L3 and L4 Radiculopathy

Manabu Sasaki^{1*}, Masanori Aoki², Katsumi Matsumoto¹, Koichiro Tsuruzono¹, Kazuo Yonenobu¹ and Toshiki Yoshimine³

¹Department of Neurosurgery and Spine Surgery, Iseikai Hospital, Osaka, Osaka, Japan

²Department of Neurosurgery, Yukioka Hospital, Osaka, Osaka, Japan

³Department of Neurosurgery, Osaka University Graduate School of Medicine, Suita, Osaka, Japan

*Corresponding author: Manabu Sasaki, Department of Neurosurgery and Spine Surgery, Iseikai Hospital, 6-2-25 Sugahara, Higashiyodogawa-ku, Osaka 533-0022, Japan, Tel: +81-6-6326-1121; Fax: +81-6-6329-6111; E-mail: mana-nsu@umin.net

Rec date: Apr 09, 2014; Acc date: May 29, 2014; Pub date: Jun 03, 2014

Copyright: © 2014 Sasaki M, et al. This is an open-access article distributed under the terms of the Creative Commons Attribution License, which permits unrestricted use, distribution, and reproduction in any medium, provided the original author and source are credited.

Abstract

Background: Previous reports have described patients with groin pain induced by lumbar radiculopathy below the L3 spinal level, but this type of groin pain has not been studied in detail. This retrospective clinical study investigated the possibility of groin pain caused by lumbar radiculopathy below the L3 spinal level.

Methods: We reviewed the clinical records of 210 consecutive patients who were surgically treated for single-level lumbar radiculopathy between June 2005 and September 2012. We examined the spinal level of the affected nerve root, clinical symptoms, and surgical outcomes based on the Japanese Orthopedic Association (JOA) score for lumbar diseases and a visual analog scale (VAS) for leg pain.

Results: The 210 patients underwent surgery for single-level lumbar radiculopathy due to L3 radiculopathy (7 patients), L4 radiculopathy (20), L5 radiculopathy (127), or S1 radiculopathy (56). Groin pain was experienced by 8 patients (3 patients with L3 and 5 with L4 radiculopathy). Most of these 8 patients also experienced pain in the anterior thigh (6 patients) or knee (5 patients) regions. The pain experienced by these patients was relieved by surgical decompression of the affected nerve roots. The JOA and VAS scores showed significant improvement postoperatively. The mean postoperative follow-up period was 19.6 months (range, 6–40 months), during which time none of the patients required additional treatment for groin pain.

Conclusions: L3 or L4 radiculopathy should be considered during the examination of patients with groin pain and radicular leg pain.

Keywords: Groin; Radicular pain; Referred pain; Lumbar radiculopathy; Spinal nerve

Introduction

Groin pain accompanies diseases of local anatomical structures such as hip joints, tendons, or funiculus spermaticus. However, groin pain may also be induced by lumbar radiculopathy. A previous report described patients with groin pain that was initially diagnosed as being associated with a hip joint disorder, but was later determined to be caused by lumbar radiculopathy [1]. Although the groin area corresponds to the L1 or L2 dermatomes [2], the pain may be induced by lumbar radiculopathy occurring below the L3 spinal level [1,3]. In this retrospective clinical study, we investigated the contribution of lumbar radiculopathy below the L3 spinal level to groin pain and elucidated its clinical significance.

Materials and Methods

Subjects

We reviewed the clinical records of 210 consecutive patients who had been surgically treated for single-level lumbar radiculopathy between June 2005 and September 2012.

The affected nerve root was identified in each patient based upon the distribution of leg pain, neurological findings, MRI, and CT findings. Selective nerve root blocks (SNRBs) were performed in 4 patients (Cases 1–3, and 7) to identify the nerve root responsible for the groin pain (Table 1). For the SNRB, a 22-gauge needle was inserted into the outer aspect of the pars interarticularis under fluoroscopic guidance, until leg and groin pain was provoked, following which, lidocaine (2 mL) and betamethasone (4 mg) were administered. The affected nerve root was confirmed by pain provocation during the needle insertion and pain relief after the SNRB.

Surgical Procedures

Affected nerve roots were decompressed using two surgical methods (Table 2). First, interlaminar decompressions (ILD) were performed utilizing an interlaminar laminotomy technique, with or without disc removal. Second, lateral fenestrations (LF) were performed which required resection of the lateral aspect of the pars interarticularis in order to decompress the exiting nerve root in the vertebral foramen.

Case	Age (yr)	Gender	Diagnosis	Affected Nerve Root	SNRB	Pain Distribution				Preoperative duration of pain (mo)	
						Low Back	Knee	Thigh	Lower Leg	Groin	Low back
											or Leg
1	43	M	L2/3 LDH	L3	NP	+	–	Anterior	–	1	3
2	79	F	L3/4 LFS	L3	+	–	+	Anterior	–	1	7
3	71	F	L3/4 LDH, LFS	L3	NP	+	+	Anterior	Anterior	4	4
4	62	F	L3/4 LCS	L4	+	–	+	Anterior	–	16	16
5	74	F	L3/4 LCS	L4	NP	+	+	Lateral	–	1	6
6	70	M	L3/4 LDH	L4	NP	+	–	–	–	2	2
7	62	M	L4/5 LDH, LFS	L4	+	+	–	Anterior	–	4	4
8	80	M	L4/5 LFS	L4	+	–	+	Anterior	–	6	8

Table 1: Characteristics of the eight patients with groin pain.

SNRB: Selective Nerve Root Block; **NP:** Not Performed; **LDH:** Lumbar Disc Herniation; **LFS:** Lumbar Foraminal Stenosis;

*Interval between symptoms: the period between the occurrence of the groin pain and the development of other symptoms.

LCS: Lumbar Canal Stenosis

Case	Surgical Method	Decompressed Nerve Root	Follow-up Period (mo)	JOA score		VAS Score	
				Pre-Op	Post-Op	Pre-Op	Post-Op
1	ILD	L3	12	9	26	75	0
2	LF	L3	40	24	29	50	0
3	LF	L3	25	12	22	95	8
4	ILD	L4	12	10	19	72	0
5	ILD	L4	12	18	22	43	0
6	ILD	L4	6	4	20	100	0
7	LF	L4	14	11	18	55	25
8	LF	L4	36	7	20	73	48

Table 2: Surgical outcomes of the eight patients with groin pain.

JOA: Japanese Orthopedic Association; **VAS:** Visual Analog Scale; **LF:** Lateral Fenestration; **ILD:** Interlaminar Decompression; **Pre-op:** Preoperative; **Post-op:** Post-operative

Statistical Analysis

The pre- and post-operative JOA and VAS scores were compared using the Wilcoxon signed-rank test; $P < 0.05$ was considered significant.

Outcomes

Surgical outcomes were evaluated using the Japanese Orthopedic Association (JOA) score (without bladder function, highest possible score = 29 points) and a visual analog scale (VAS; worst possible score = 100 points) for leg pain and groin pain. JOA and VAS scores were objectively recorded preoperatively and 1-month postoperatively by physical therapists.

Results

The 210 patients were surgically treated for single-level lumbar radiculopathy due to L3 radiculopathy (7 patients), L4 radiculopathy (20), L5 radiculopathy (127), or S1 radiculopathy (56); none had L1 or L2 radiculopathy. Notably, none of the patients with L5 or S1 radiculopathy reported preoperative groin pain. Only 8 patients (3

with L3 and 5 with L4 radiculopathy) experienced preoperative groin pain.

Preoperative Clinical Data of the 8 patients with Groin Pain (Table 1)

The 8 patients with groin pain averaged 67.6 years of age (range, 43–80 years), and included 4 females, and 4 males. All patients complained of lower back and/or leg pain. One patient (Case 6) complained of pain in the buttocks along with groin pain, but did not have leg pain. The other 7 patients reported leg pain; 6 involved the anterior thigh and 5 had knee pain. Four patients experienced groin pain at the onset of the radiculopathy, whereas the other 4 patients developed groin pain within 6 months from the onset. Pain had been present for an average preoperative period of 6.3 months (range, 2–16 months); the mean preoperative duration of groin pain was 4.7 months (range, 1–16 months). Seven of these patients had previously undergone hip joint examinations by orthopedic surgeons before initial examination in our department. All 8 patients had received conservative therapy for more than a month before surgery; 4 of them had received SNRB with palliation of their groin pain.

Surgical Procedures and Results (Table 2)

4 patients underwent ILD, while 4 had LF procedures. Postoperatively, all 8 patients reported postoperative pain relief of pain in both the groin and legs. The mean preoperative JOA score in these 8 patients with groin pain was 11.9 points (range, 4–24 points), which improved to 22.0 points (range, 18–29 points) postoperatively. The mean preoperative VAS score was 70.4 points (range, 43–100 points), which decreased to 10.1 points (range, 0–48 points) postoperatively. The Wilcoxon signed-rank test showed that the postoperative JOA and VAS scores improved significantly after the operation ($P < 0.05$). The mean postoperative follow-up period was 19.6 months (range, 6–40 months); none of these patients required additional treatment for groin pain during the follow-up period.

Discussion

Groin pain typically correlates with L1 and L2 dermatomal pathology. However, few patients exhibit significant lumbar degenerative disease involving the L1 and L2 levels. A few previous studies have also shown that groin pain may be induced by lower lumbar disc degenerations [4,5]. Oikawa et al. reported successful treatment of this “discogenic groin pain” by anterior lumbar interbody fusion, after confirming the affected spinal level by discography and disco block [4]. They considered the discogenic groin pain to be referred pain via the L2 spinal nerve that innervates the intervertebral discs in the lower lumbar spine. Since Oikawa’s study excluded patients who noted lower back pain or radicular leg pain, the subjects were quite different from those in the present study.

The present study demonstrated that groin pain could in fact be attributed to L3 and L4 radiculopathy; 4 of the 8 patients developed groin pain simultaneously with the onset of back pain and/or radicular leg pain. The affected nerve root for groin pain was confirmed by SNRB in half of the patients. In addition, all patients experienced groin pain relief after surgical decompression of the affected single-level nerve root, and none needed additional treatment for the next six months. Therefore, we concluded that the groin pain noted in these 8 patients was caused by L3 and L4 radiculopathy. Anterior thigh and knee pain seen in this study was similar to that associated with

obturator neuropathy, a known cause of groin pain [6,7]. Since the L3 and L4 spinal nerves are connected with the L2 spinal nerve through the obturator nerve [7], we suspect that the groin pain caused by L3 and L4 radiculopathy may be referred pain.

In light of the present results, we developed an algorithm to investigate patients with groin pain (Figure 1). Initially, we perform a physical examination for hip arthropathy or sacroiliac arthropathy, usually involving Patrick, Gaenslen, or Newton test. If these tests are negative, we investigate the lumbar spine using diagnostic imaging. During interpretation of radiographs or MRI scans of the lumbar spine, we examine not only the lumbar spine, but also the sacroiliac joint. When inflammatory changes of the sacroiliac joint are observed, we locally inject the sacroiliac joint to confirm that the groin pain is due to sacroiliac arthropathy. When lumbar degenerative disease is suspected of causing the groin pain, we check for entrapment of the L1, L2, L3, and L4 nerve roots using diagnostic imaging which focus on the spinal canal and the vertebral foramen. If groin pain is noted in patients with lumbar degenerative disease at the L4–5 level, L4 nerve root entrapment in the vertebral foramen or anomalous conjoined nerve root should be considered. Finally, an affected nerve root can be confirmed by an SNRB. Discogenic groin pain should be considered in patients with lumbar degenerative disease only at the L4–5 or the L5–S1 levels; it can be confirmed by local injection to the intervertebral disc. This algorithm may be helpful during the examination of patients with groin pain. Further, this study may provide the impetus for future research into a more complete overview of groin pain caused by lumbar radiculopathy.

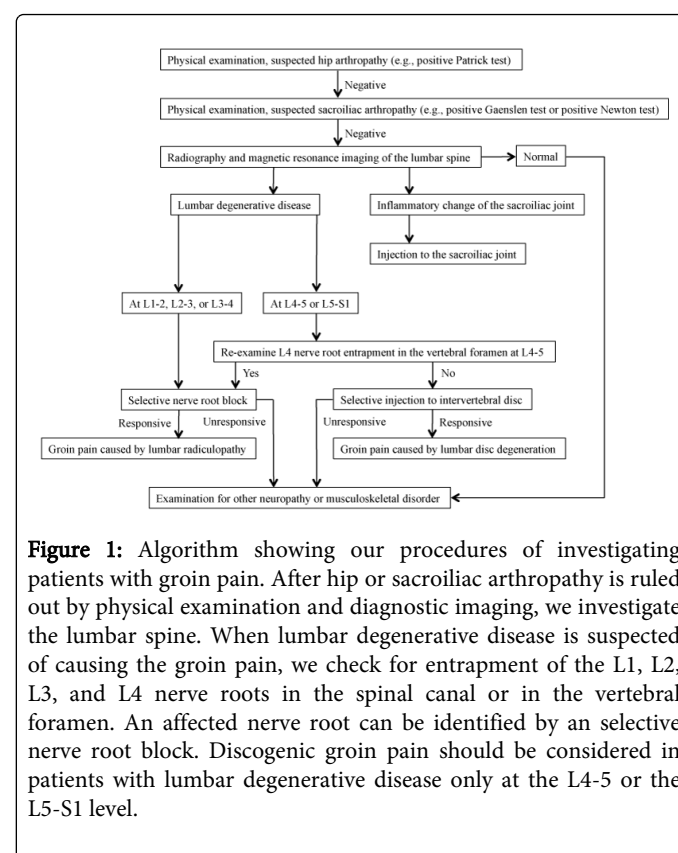


Figure 1: Algorithm showing our procedures of investigating patients with groin pain. After hip or sacroiliac arthropathy is ruled out by physical examination and diagnostic imaging, we investigate the lumbar spine. When lumbar degenerative disease is suspected of causing the groin pain, we check for entrapment of the L1, L2, L3, and L4 nerve roots in the spinal canal or in the vertebral foramen. An affected nerve root can be identified by an selective nerve root block. Discogenic groin pain should be considered in patients with lumbar degenerative disease only at the L4-5 or the L5-S1 level.

References

1. Austin RT (1990) Spinal lesions simulating hip joint disorders. Clin Rheumatol 9: 414-420.
2. Hazewinkel MH, Hinoul P, Roovers JP (2009) Persistent groin pain following a trans-obturator sling procedure for stress urinary incontinence: a diagnostic and therapeutic challenge. Int Urogynecol J Pelvic Floor Dysfunct 20: 363-365.
3. Hirabayashi H, Takahashi J, Hashidate H, Ogihara N, Tashiro A, et al. (2009) Characteristics of L3 nerve root radiculopathy. Surg Neurol 72: 36-40.
4. McCulloch JA, Transfeldt E, Macnab I (1997) Macnab's Backache. (3rd edn), Williams & Wilkins, Baltimore.
5. Oikawa Y, Ohtori S, Koshi T, Takaso M, Inoue G, et al. (2012) Lumbar disc degeneration induces persistent groin pain. Spine (Phila Pa 1976) 37: 114-118.
6. Tipton JS (2008) Obturator neuropathy. Curr Rev Musculoskelet Med 1: 234-237.
7. Yukawa Y, Kato F, Kajino G, Nakamura S, Nitta H (1997) Groin pain associated with lower lumbar disc herniation. Spine (Phila Pa 1976) 22: 1736-1739.