

## Gastrointestinal Stromal Tumor of the Rectum Diagnosed by Prostate Needle Biopsy: Report of a Case

Franc Jelenc\*

University Medical Center, Ljubljana, Slovenia

### Abstract

A 52-year-old man was referred to our institution with the presentation of rectal bleeding, and change in caliber of his stools. On rectal examination a solid mass was palpated in the prostate area. Transrectal needle biopsy and cytology showed a gastrointestinal stromal tumor. Subsequent rectal ultrasound demonstrated a hypoechogenic lesion that appeared to be growing out of the muscularis propria of the anterior rectal wall. Magnetic resonance imaging showed a well demarcated mass measuring 9 cm in diameter, which occupied the cavity of the lesser pelvis. A low anterior rectal resection with protective ileostomy was performed. The macroscopic findings showed the tumor measuring 9 cm, growing from the anterior wall of the rectum. Histological examination of the excised specimen revealed up to 5 mitoses per 50 high-power fields. The postoperative course was uneventful and ileostomy was closed after six weeks. Magnetic resonance imaging on follow-up five years postoperatively showed no signs of recurrence.

**Keywords:** Gastrointestinal stromal tumor; Rectum; Surgery

### Introduction

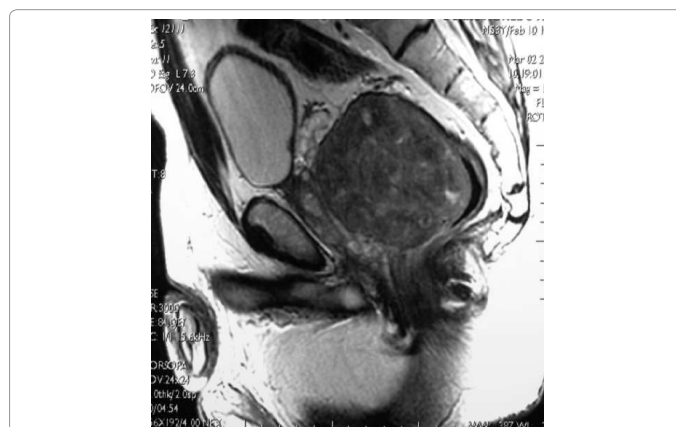
Gastrointestinal Stromal Tumors (GISTs) are the most common mesenchymal tumors in the digestive tract with the incidence of approximately 15 per million. GISTs account for only 0.1% to 3% of all gastrointestinal cancers. They typically arise in the stomach (50-60%), but can also be found in the small intestine (30-35%), rectum (5%), and uncommonly in the esophagus and omentum [1]. Hirota et al., investigated the molecular biology of these GISTs and demonstrated that the neoplastic GIST cells show ultrastructural features and express cell markers typical of the normal intestinal cell of Cajal. A mutation in the juxtamembrane domain of CD117 (c-kit) results in constitutive activation of the c-kit receptor tyrosin kinase. This mutation is present in 90% of GISTs, and one-third of GISTs lacking c-kit mutations have a mutation in a related tyrosine kinase, platelet-derived growth factor receptor  $\alpha$  (PDGFRA) [2]. In most GISTs, an activating mutation of c-kit leads to ligand-independent receptor dimerization and activation of KIT tyrosine kinase that promotes tumor survival and tumor growth [3]. Surgical resection remains the primary treatment of GISTs. Surgery is indicated for all GISTs that cause symptoms and those tumors suspected of being malignant or potentially malignant. Wide margins of resection do not appear to be necessary. In addition, lymphadenectomy does not need to be performed because lymph node metastases are rare in GISTs [4].

The complete removal of the tumor can be achieved in 95% of patients with non-metastatic disease and surgical resection is the initial therapy for patients with primary GIST who have no metastases and are considered resectable. Curative (R0) resection is possible in only a minority of patients presenting with recurrent or metastatic disease. Before the introduction of imatinib mesylate median survival in this patient group was only 12 months [5]. In 2001, the initial report of activity of the tyrosine kinase inhibitor (TKI) imatinib mesylate in a patient with chemotherapy-resistant metastatic GIST prompted clinicians to conduct a multicentre trial. This established the efficacy and safety of this drug for treating patients with advanced GISTs [6]. Tumor recurrence after surgical resection is common in this patient group. Recurrence presents locally with tumor involving the regional peritoneum or presents with liver metastases.

### Case Report

A 52-year-old man had a six-month history of anorexia, rectal bleeding, and change in caliber of his stools. On rectal examination a solid mass was palpated in the prostate area. The patient was first examined by urologist who performed trans-rectal needle biopsy.

Cytology showed a GIST. Subsequent rectal ultrasound demonstrated a hypoechogenic lesion that appeared to be growing out of the muscularis propria of the anterior rectal wall. Magnetic resonance imaging (MRI) showed a well demarcated mass in the pelvis, pushing the rectum to the right and narrowing its lumen. The mass was adjacent to the anterior rectal wall; however, it was clearly separated from the bladder, the prostate, and the seminal vesicles (Figures 1 and 2). Since the tumor was well demarcated with severe narrowing of the rectum we decided to proceed with surgery. At surgery, we found a tumor in the pelvis. Anteriorly, we separated the tumor from the bladder, the prostate, and the seminal vesicles. Posteriorly, due to adherence of the tumor to the anterior rectal wall, a low anterior rectal resection with protective ileostomy was made. The postoperative course was uneventful and ileostomy was closed after six weeks.



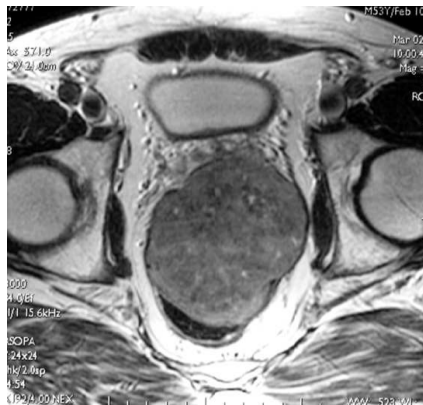**Figure 1:** Magnetic resonance imaging (MRI) showing a well demarcated mass in the pelvis adjacent to the anterior rectal wall.

\*Corresponding author: Franc Jelenc, University Medical Center, Ljubljana, Slovenia, Tel: +38615225050; E-mail: [franc.jelenc@kclj.si](mailto:franc.jelenc@kclj.si)

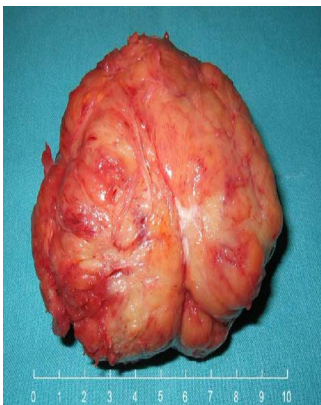
Received December 03, 2015; Accepted January 08, 2016; Published January 13, 2016

**Citation:** Jelenc F (2016) Gastrointestinal Stromal Tumor of the Rectum Diagnosed by Prostate Needle Biopsy: Report of a Case. J Clin Case Rep 6: 686. doi:10.4172/2165-7920.1000686

**Copyright:** © 2016 Jelenc F. This is an open-access article distributed under the terms of the Creative Commons Attribution License, which permits unrestricted use, distribution, and reproduction in any medium, provided the original author and source are credited.



**Figure 2:** Magnetic resonance imaging (MRI) showing a well demarcated mass in the pelvis adjacent to the anterior rectal wall.



**Figure 3:** Gastrointestinal stromal tumor with diameter of 9 cm.

The tumor weighed 257 g and had a diameter of 9 cm (Figure 3). Histology confirmed the diagnosis of GIST. The tumor cells were well differentiated with 5 mitoses per 50 high-power field and positive for c-kit (CD117). Regarding the size of the tumor and the number of mitoses, the tumor was classified as Stromal Tumor Of Unknown Malignant Potential (STUMP). The case was discussed with oncologists and it was decided that treatment with imatinib mesylate is not indicated since the time interval between surgery and final histology result was eight weeks. The patient was scheduled for regular follow-up. MRI imaging five years postoperatively showed no signs of recurrence. The patient is still alive and well ten years after surgery.

## Discussion

No definitive guidelines for treatment of rectal GISTs have been established because of small number of such patients; however, surgical resection is considered to be the primary treatment [7]. Patients usually present with nonspecific symptoms and signs and approximately 15% to 50% of GISTs show initial metastasis [4].

As rectal GIST does not metastasize through the lymphatics, total mesorectal excision, the preferred strategy for rectal carcinoma, has little, if any, benefit. In addition, the risk of damaging the autonomic nervous plexus and poor functional outcome after proctectomy must be considered, particularly in a young man. Transanal excision or excision using transanal minimal invasive surgery is an interesting alternative for small (under 3 cm) GISTs with a limited extrarectal component, which are usually incidental findings during endoscopy

[8,9]. Laparoscopic resection of GISTs has been described primarily in gastric tumors, but is also possible in rectal GISTs [10].

For larger (over 5 cm) tumors growing anteriorly towards prostate or vagina, or posteriorly towards the sacrum, this approach is inadequate. A posterior trans-sacral approach with wedge resection of the rectum has same benefits, including excellent exposure without the need for a major laparotomy, and avoiding the risk of urogenital dysfunction following total mesorectal excision [11]. GISTs located on the anterior wall of the lower rectum might benefit from a transvaginal approach [12]. GISTs with a large extrarectal component, when located in the male anterior rectal wall, can give the clinical impression of a prostatic lesion, and are diagnosed by prostate needle biopsy. C-kit and immunohistochemical panel are recommended to exclude GIST before establishing the diagnosis of prostate stromal tumor [13]. Neoadjuvant therapy with imatinib mesylate may play a role in downsizing large pelvic GISTs, especially when the tumor is in the vicinity of the anal sphincter, thereby making a more limited sphincter preserving procedure possible [14].

The recurrence rate after surgery in reported series ranged from 17% to 24%. Risk factors for recurrence were: large tumor size, higher mitotic figure, tumor rupture during surgery, multiple organ involvement, and incomplete tumor resection. In one study large tumor size ( $\geq 10$  cm) was the only significant predictor for recurrence [15]. The importance of meticulous surgical technique in the prevention of tumor rupture can not be overemphasized.

## References

1. Joensuu H, Hohenberger P, Corless CL (2013) Gastrointestinal stromal tumour. *Lancet* 382: 973-983.
2. Hirota S, Isozaki K, Nishida T, Kitamura Y (2000) Effects of loss-of-function and gain-of-function mutations of c-kit on the gastrointestinal tract. *J Gastroenterol* 35 Suppl 12: 75-79.
3. Sircar K, Hewlett BR, Huizinga JD, Chorneyko K, Berezin I, et al. (1999) Interstitial cells of Cajal as precursors of gastrointestinal stromal tumors. *Am J Surg Pathol* 23: 377-389.
4. DeMatteo RP, Lewis JJ, Leung D, Mudan SS, Woodruff JM, Brennan MR (2000) Two hundred gastrointestinal stromal tumors. Recurrence patterns and prognostic factors for survival. *Ann Surg* 231: 51-8.
5. Tran T, Davila JA, El-Serag HB (2005) The epidemiology of malignant gastrointestinal stromal tumors: an analysis of 1458 cases from 1992 to 2000. *Am J Gastroenterol* 100: 162-168.
6. Joensuu H, Roberts PJ, Sarlomo-Rikala M, Andersson LC, Tervahartala P, et al. (2001) Effect of the tyrosine kinase inhibitor STI571 in a patient with a metastatic gastrointestinal stromal tumor. *N Engl J Med* 344: 1052-1056.
7. Demetri GD, von Mehren M, Blanke CD, Van den Abbeele AD, Eisenberg B, et al. (2002) Efficacy and safety of imatinib mesylate in advanced gastrointestinal stromal tumors. *N Engl J Med* 347: 472-480.
8. Testroote M, Hoornweg M, Rhemrev S (2007) Rectal GIST presenting as a submucosal calculus. *Dig Dis Sci* 52: 1047-1049.
9. Aghayeva A, Bayraktar O, Atasoy D, Ozben V, Baca B (2015) Excision of a Rectal Gastrointestinal Stromal Tumor Using the Transanal Minimal Invasive Surgery Technique. *Dis Colon Rectum* 58: 1108.
10. Nakamura T, Ihara A, Mitomi H, Kokuba Y, Sato T, et al. (2007) Gastrointestinal stromal tumor of the rectum resected by laparoscopic surgery: report of a case. *Surg Today* 37: 1004-1008.
11. Gervaz P, Huber O, Bucher P, Sappino P, Morel P (2008) Transsacral (Kraske) approach for gastrointestinal stromal tumor of the lower rectum: old procedure for a new disease. *Colorectal disease* 10: 951-2.
12. Hellan M, Maker VK (2006) Transvaginal excision of a large rectal stromal tumor: an alternative. *Am J Surg* 191: 121-123.
13. Herawi M, Montgomery EA, Epstein JI (2006) Gastrointestinal stromal tumors

- 
- (GISTs) on prostate needle biopsy: A clinicopathologic study of 8 cases. Am J Surg Pathol 30: 1389-1395.
14. Wilkinson MJ, Fitzgerald JE, Strauss DC, Hayes AJ, Thomas JM, et al. (2015) Surgical treatment of gastrointestinal stromal tumour of the rectum in the era of imatinib. Br J Surg 102: 965-971.
15. Hsu KH, Yang TM, Shan YS, Lin PW (2007) Tumor size is a major determinant of recurrence in patients with resectable gastrointestinal stromal tumor. Am J Surg 194: 148-152.