

Fungal Spondylodiscitis: Unexpected Diagnosis, Case Report and Literature Review

Alqroom Y. Rami^{1*}, Michalitsis G. Sotirios², Leue Lukas², Hunger Frank³ and Franke Jorg³

¹Department of Neurosurgery, Royal Medical Services, King Hussein Medical Centre, Amman, Jordan

²Spine Center, Hospital Klinikum Dortmund, Dortmund, Germany

³Institute for Hospital Hygiene and Clinical Microbiology, Hospital Klinikum Dortmund, Dortmund, Germany

Abstract

Study design: Case report of a rare case of spondylodiscitis due to *Candida* species (*C. tropicalis*).

Objective: To report our case with this rare condition (Fungal spondylodiscitis due to *Candida tropicalis*) in a 75-year old female immune-competent patient presenting with low back pain and literature review.

Summary of background data: Spondylodiscitis or discitis is an infection in the intervertebral disc space and adjacent end plates, this disease accounts for 2–7% of all cases of pyogenic osteomyelitis, which affects different age groups. There is a wide spectrum of causative agents: pyogenic, granulomatous or parasitic. Nowadays incidence has increased the rise in the prevalence of immunosuppressed patients and intravenous drug abusers, and the increase in spinal surgeries. Nonetheless, the microbiological diagnosis of infectious spondylodiscitis is often difficult to establish and the disease requires prolonged antibiotic treatment in combination with surgical intervention are the cornerstone of management. *Candida* spondylodiscitis usually affects immunocompromised patients after haematogenous dissemination.

Methods: A 75-year-old female patient, who developed low back pain, pain radiated intermittently to both lower limbs, not associated with any sensorimotor deficit. Imaging of the thoraco-lumbosacral spine at the same day (X-ray, CT and MRI) showed alteration of the inter-vertebral disc in Th11/12 and L1/L2. The patient was treated surgically under general anaesthesia and fluoroscopy control.

Results: We successfully treated this patient with spondylodiscitis due to fungal infection. By surgical debridement, fusion and pharmaceutical agents: amphotericin and/or fluconazole. Thoraco-lumbosacral CT, 12 weeks after surgery showed decreased oedema of the vertebra, disc space and pre-spinal soft tissues, the patient was symptom less.

Conclusion: Candidal spondylodiscitis is a rare fungal infection should be suspected in immunocompromised patients and elderly with chronic diseases. Without treatment, the disease is progressive and leads to vertebral destruction and spinal cord and neural Preservation of the structure and function of the spine and pain alleviation. Established pharmaceutical agents are amphotericin and/or fluconazole for a minimum of 3 months and surgical debridement of the disc with instrumented fusion is highly recommended.

Keywords: Spondylodiscitis; *Candida tropicalis*; *Candida* species

Introduction

Spondylodiscitis or discitis is an infection in the intervertebral disc space and adjacent end plates, a rare disease accounting for 2–7% of all cases of pyogenic osteomyelitis, that affects different age groups, which affects spontaneously children under 8 years of age [1,2]. There is debate regarding the cause; spondylodiscitis can be pyogenic, granulomatous (tuberculosis, brucellosis, fungal infection), or parasitic. Its' incidence has increased recently as a result of the higher life expectancy of older patients with chronic diseases, the rise in the prevalence of immunosuppressed patients and intravenous drug abusers, and the increase in spinal surgeries [3-5]. The most common route of infection remains haematogenous seeding, followed by external inoculation or direct spread of the offending organism from contiguous tissues. It is important to differentiate spontaneous discitis- which is usually due to haematological spread from urinary or respiratory infection- from a post-operative complication which usually involves skin flora such as *S. aureus*. Nonetheless, direct inoculation is most commonly iatrogenic following spinal surgery, lumbar puncture or epidural procedures and accounts for up to 25–30% of cases in some spondylodiscitis series [6]. The cause may be aseptic in some special conditions [7]. The microbiological diagnosis of infectious spondylodiscitis is often difficult to establish and the disease requires prolonged antibiotic treatment. Surgical or needle biopsy specimens from the affected vertebral body or adjacent tissues are the cornerstone of diagnosis. The importance of isolation of the aetiological agent is underscored by

the fact that treatment regimens for pyogenic bacteria, mycobacteria and fungi are completely different. Thus, narrow-spectrum treatment options should be preferred to ameliorate the resistance problems related to the long treatments required. No more than 5% of the cases of spondylodiscitis are caused by fungi; of these, *Candida* species are the most frequent agents [1,8]. *Candida* spondylodiscitis usually affects immunocompromised patients after haematogenous dissemination [9]. We report a case of spondylodiscitis caused by *Candida tropicalis* in an immune-competent patient.

Case Report

A 75-year old female patient with a medical history of mild nephropathy, mitral valve insufficiency, bipolar disorder and bilateral total knee replacement, was under home nursing care when she started to complain about back pain. Two days later she developed tachypnea

***Corresponding author:** Rami Alqroom, MD, Spine surgeon, Department of Neurosurgery, Royal Medical Services, King Hussein Medical Center, Amman, Jordan, Tel: 00962797017870; Fax: 004923195321020; E-mail: dr.alqroomrami@gmail.com

Received June 03, 2016; **Accepted** June 20, 2016; **Published** June 22, 2016

Citation: Rami AY, Sotirios MG, Lukas L, Frank H, Jorg F (2016) Fungal Spondylodiscitis: Unexpected Diagnosis, Case Report and Literature Review. J Spine 5: 313. doi:10.4172/2165-7939.1000313

Copyright: © 2016 Rami AY, et al. This is an open-access article distributed under the terms of the Creative Commons Attribution License, which permits unrestricted use, distribution, and reproduction in any medium, provided the original author and source are credited.

and has been admitted to a territorial hospital where investigations started to figure out the cause of the respiratory distress. Being between different departments, she developed nosocomial pneumonia and fever. Although treated with an empiric antibiotic regimen (cefuroxime), her condition worsened, was intubated and has been admitted to intensive care unit. During her 9-days ICU stay; she has been treated with a beta-lactamase inhibitor (tazobactame).

In the ward due to exacerbation of her formal condition of depression in addition to the new comorbidity, her alimentary intake was reduced and a percutaneous endoscopic gastrostomy (PEG) has been performed. Two weeks later the patient recovered, discharged and remained under home nursing care.

Three weeks after her discharge, as the pain escalated and became consistent; the patient was readmitted with severe lumbar pain, the pain radiated intermittently to both lower limbs, not

	2 nd day	3 rd day	4 th day	8 th day	28 th day
Urine CX	Negative	Negative	-	Negative	-
MRSA	Negative	-	Negative	-	-
BLD CX	Negative	-	-	-	Negative
Disc CX Bacterial	Negative	-	-	-	-
Disc CX Mycobacterium	Negative	-	-	-	-
Disc CX Fungal	Positive	-	-	-	-

Table 1: Culture's results of body tissues and fluids.

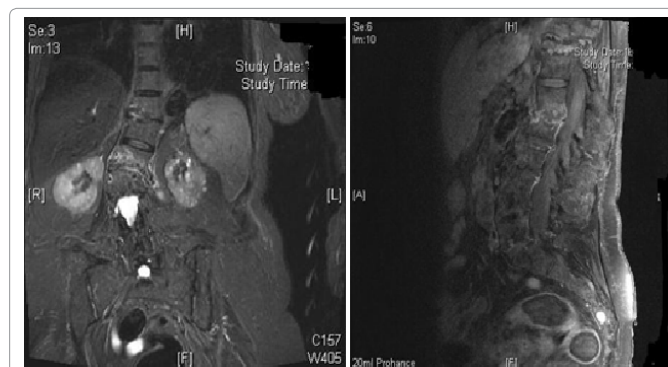


Figure 2: MRI Images at admission. Showing high signal of disc space and adjacent tissues, suggestive of spondylodiscitis in the Thoracic spine between D11/D12 and lumbar spine at L1/L2 disc space with bone oedema, blurry edges of the endplates of the mentioned discs and a compromised spinal canal along with degenerative scoliosis.

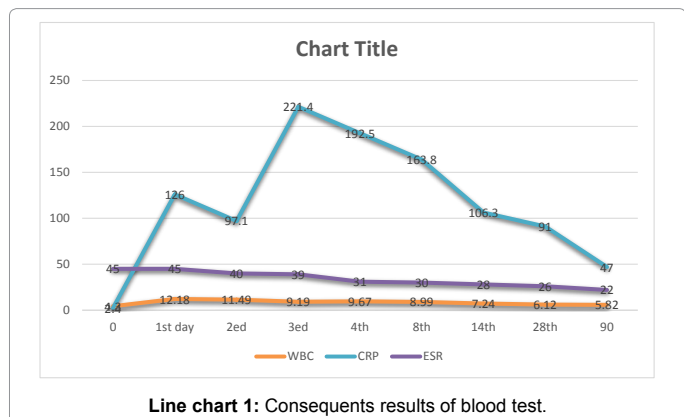
associated with any sensori-motor deficit. Imaging of the thoracolumbosacral spine at the same day (X-ray, CT & MRI), showed alteration of the inter-vertebral disc in Th11/12 and L1/L2 (Figure 1). This finding raised a suspicion of an infectious process and the patient was referred to our clinic.

On admission (day 0) the erythrocyte sedimentation rate (ESR) was 45 mm/h, the C-reactive protein (CRP) 126 mg/l and the leukocytes $8.59 \times 10^9/l$. (chart 1). The blood cultures obtained in day 0 (two pairs under strictly aseptic conditions) revealed no pathogens (Table 1). Magnetic resonance imaging (MRI) of the spine showed spondylodiscitis in the Th 11/12 and L1/L2 disc space with bone oedema, blurry edges of the endplates of the mentioned discs and a compromised spinal canal along with degenerative scoliosis (Figure 2). On day 3 the patient was prepared for operation under general anaesthesia. After biopsy samples for bacterial, fungal and mycobacterial cultures had been harvested, our patient underwent a debridement of the disc spaces Th9/10 and L1/L2 and consequent TLIF with a tantalum cage in both segments as instrumentation, correction of scoliosis and posterolateral fusion from Th7 to L4 (Figure 3). An empirical intravenous treatment regimen (cefuroxime 500 three times daily) was introduced. Bacterial cultures of the biopsy specimen turned out negative as well as all other culture specimens. Remarkably, a fungal culture of the biopsy specimen grew *Candida* species. *Candida tropicalis* was detected in both swab and bioptic tissue taken during lumbar laminectomy Th11 and L1. The organism was cultured on Columbia sheep blood agar and was identified by matrix-assisted laser desorption/ionization time-of-flight (MALDI-TOF) mass spectrometry (MALDI Biotyper, Bruker). Fluconazole susceptibility testing was performed by Etest method and the minimum inhibitory concentration (MIC) was determined susceptible at 0.5 mg/l using EUCAST clinical breakpoints.

The empirical antibacterial treatment was stopped due to negative cultures and intravenous fluconazole of 0.6 mg/kg was started. Two weeks later intravenous fluconazole was discontinued and the patient was put on oral fluconazole 400 mg once daily. One month after

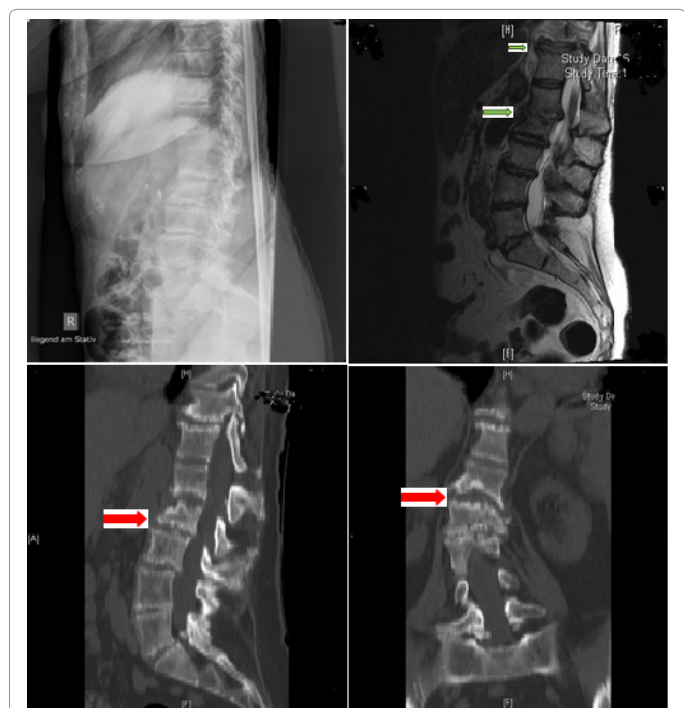

Figure 1: Radiological Images at admission; X-ray: showing disc space narrowing and irregularity. MRI: showing, high signal in disc space (fluid) and adjacent endplates (bone marrow oedema) associated with loss of low signal cortex at endplates CT: destructive or ill-definition of the vertebral endplates can be seen, also bony sclerosis begin to appear.



antifungal therapy was initiated; the dose was reduced to 200 mg/day. Thoraco-lumbosacral CT, 12 weeks after surgery showed decreased oedema of the vertebra, disc space and prespinal soft tissues, the patient was symptom less and ESR was 22 mm/h and CRP 47 mg/l.

Discussion

Spondylodiscitis, although rare, is still considered a serious medical condition that may lead to severe deformity and neurological complications. Regarding the age distribution, two peaks, at age <20 years and between 50–70 years, though all ages are susceptible [10,11]. Spondylodiscitis has a male preponderance, with a male-to-female ratio of 1.5–2:1 [11,12]. The symptoms of spondylodiscitis are non-specific. Back or neck pain is very common, but up to 15% of patients may be pain-free. Fever is less commonly experienced and occurs in only about half of patients [11,13–15].

Pathogens invade the spine via three routes: by haematogenous spread, by direct external inoculation, or by spread from contiguous tissues [16]. Blood culture is a simple and cost-effective method for identifying bacterial agents of spondylodiscitis, as the infection is mostly mono-microbial and often has a haematogenous source [17]. Direct inoculation is most commonly iatrogenic, following spinal surgery, lumbar puncture or epidural procedures and accounts for up to 25–30% of cases in some spondylodiscitis series [6,16]. The most common organism causing a pyogenic spondylodiscitis is *Staphylococcus aureus* [8]. The range described in different studies varies from 20% to 84% [14,16]. Gram-negative bacteria are causative agents in 7%–33% of pyogenic Spondylodiscitis cases. The most frequent species are Enterobacteriaceae – *Escherichia coli*, *Proteus* spp., *Klebsiella* spp., *Enterobacter* spp., and *Pseudomonas aeruginosa*. These microorganisms are often associated with urinary or gastrointestinal tract infections, older age, immune suppression and diabetes [3,16,18] Brucellosis, the

commonest zoonosis in endemic areas, can account for 21%–48% of spinal infections, representing the predominant cause in some series from the Mediterranean basin and the Middle East [3,4]. Tuberculosis is the commonest cause of spinal infection worldwide, and accounts for 9%–46% of cases in developed countries [14,16,19–21].

Fungal spondylodiscitis is uncommon even in large series (0, 5–1, 6% usually, up to 6, 9% in one report) [16]. It is strongly associated with immunosuppression, including steroid use, neutropenia and chronic granulomatous disease. *Candida* spp., *Aspergillus* spp. and *Cryptococcus neoformans* occur worldwide and the commonest reported *Candida* species in the literature is *Candida albicans*. Among patients with documented candidemia, the use of broad-spectrum antibiotics, central intravascular catheterization and major surgery, such as parenteral nutrition were the commonest risk factors [22].

Candida discitis is a rare complication of systemic candidemia and is thought to spread haematogenously [22,23]. *Candida* osteomyelitis was first mentioned in the literature in 1970 [24]. Gathe et al. study showed that approximately 60% of cases of *Candida* osteomyelitis occur in the spine [25]. To date, less than 100 such cases are reported. Invasive *Candida* infections have increased significantly over the past two decades [26] and are commonly seen in immunosuppressed patients and intravenous drug users. The lack of typical inflammatory response and insidious course of the disease can make the diagnosis difficult. The ideal duration for treatment of fungal discitis has not yet been established and current practice is to continue therapy until clinical symptoms and inflammatory markers have normalised and/or imaging shows resolution of inflammation. Other treatment options include surgical intervention especially in cases of neurological compromise [22,27,28].

Our patient underwent a debridement of the disc spaces Th9/10 and L1/2. Cultures from the intervertebral discs were reported as positive for fungi, which eventually grew *Candida tropicalis* and systematic fluconazole therapy was initiated (Figure 3).

Candida tropicalis has been identified as the most prevalent pathogenic yeast species of the *Candida-non-albicans* group, causing human disease in tropical countries; the frequency of invasive disease varies by geography causing 3–66% of candidemia. Since 1990, *non-albicans Candida* species have been responsible for the majority of bloodstream infections, whereas before the 90's *Candida albicans* was responsible for nearly 80% of all case of candidemia [29,30]. *C. tropicalis* is taxonomically close to *C. albicans* and shares many pathogenic traits. *C. tropicalis* is virulent in neutropenic hosts commonly with haematogenous seeding to peripheral organs [31].

ESR and CRP are sensitive markers for infection but lacks specificity [32]. Spondylodiscitis was more evenly distributed among lumbar, thoracic, although the lumbar disc spaces were still the most frequently involved [22,26]. Spondylodiscitis is often found as a complication of psoas abscess and epidural abscess [5,33]. Of all spondylodiscitis cases, 25% are associated with epidural abscesses [34].

This case shows that it is important to consider fungal discitis in patients even without evidence of immune-suppression. Colonisation by *Candida* spp. is the leading risk factor for infection. The prior of concomitant administration of antibiotics has also been considered a major risk factor for candidiasis [33]. Fluconazole might be a useful agent in treating *Candida* discitis.

As fungal infection has been rarely suggested as a cause of vertebral osteomyelitis [22], we conducted an evidence-based literature review (Table 2) [34–46] with the keywords: 'fungal spondylodiscitis', '*Candida*

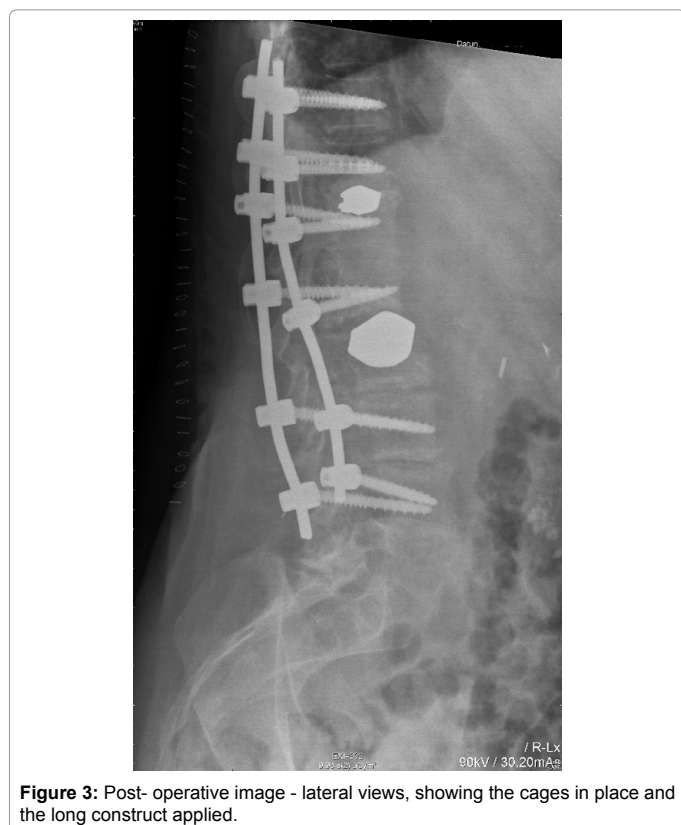

Figure 3: Post-operative image - lateral views, showing the cages in place and the long construct applied.

Author & Year	Age, Gender	Vertebral Region Involved	Blood Culture Positive	Risk Factor	Treatment	Outcome
Hayes, 1984 [35]	67, M	L1/2	Yes	Antibiotic therapy, CVC, malignancy	NR	NR
Pennisi, 1985 [36]	77, M	Th9/10	Yes	Antibiotic therapy, CVC	AmB, surgery, prosthetic supports	cured
Pennisi, 1985 [36]	79, M	L3/4	No	Antibiotic therapy, CVC, malignancy, chemotherapy	AmB/5-FC, surgery	cured
Bruns, 1986 [37]	63, F	Th7/8	Yes	Antibiotic therapy	AmB/5-FC, Ket, surgery	cured
Kashimoto, 1986 [38]	50, M	Th7/8	NR	GI surgery	surgery	Resolved/3 months
Friedmann, 1987 [39]	77, M	Th9/10	No	Antibiotic therapy, GI surgery	AmB	Resolved/5 months
Herzog, 1989 [40,41]	88, M	L4/5	NR	CVC, malignancy, chemotherapy	AmB, Ket	cured
Sugar, 1990 [42]	70, M	Th12/L1	Yes	GI surgery	AmB, Flu, surgery,	Resolved/3 months
Ferra, 1994 [43]	40, F	Th10	Yes	Antibiotic therapy, CVC, malignancy, chemotherapy, BMT	AmB	Resolved/2 months
Ferra, 1994 [43]	42, M	C4/5, TH10-L3	Yes	Antibiotic therapy, CVC, malignancy, chemotherapy, BMT	AmB/5-FC, surgery	died
Eisen, 2000 [12]	73, M	TH8/9	Yes	Antibiotic therapy, CVC, GI surgery	Lipid AmB/5-FC, ltr, surgery, prosthetic supports	cured
Sebastiani, 2001 [44]		Th6/9	No	Ulcerative colitis, GI surgery, CVC	Flu	cured
Hendrickx, 2001 [22]	39, F		Yes	None	Surgical debridement Flu, Amp B, Intr	Resolved/12 months
Hendrickx, 2001 [22]	73, M		Yes	None	Surgical debridement, Flu, AmpB	Resolved/6 months
Garbino, 2003 [45]	43, M		No	Leukemia	Amp B, Flu, Intr	Resolved/7 months
Cone, 2004 [46]	76, M		NA	None	Amp B, surgery	Resolved/6 weeks
Shaikh, 2005 [33]	67, F	L1/2	Yes	None	Surgery, Amp B, Flu	
Our case	75, F	Th11/12, L1/2	No	Intubation, PEG, Antibiotics	Surgical debridement, Flu	Resolved/3 months

Table 2: Review of literature.

tropicalis', and 'non-*Candida albicans* species'. Miller and Mejicano in 2001 reviewed the cases of *Candida* vertebral osteomyelitis from 1966 to 2000 and the research revealed eleven cases of osteomyelitis/spondylodiscitis due to *Candida tropicalis* [27]. In seven patients' blood cultures were positive for *Candida* species, 2 of them had negative cultures and there were no data for two cases. The main risk factor appeared to be the antibiotic therapy, whilst 8 of the patients had a central venous catheter and 4 of them underwent a gastrointestinal tract surgery. Regarding the treatment regimen, the existing data in ten of the cases showed that amphotericin B has been the dominant pharmaceutical agent; in four of the patients in a combination with flucytocine, two patients were treated with a combination of amphotericin and ketoconazole/fluconazole and in 3 of the cases a triple combination of amphotericin B flucytocine and cetoconazole/intraconazole was applied. One individual has been treated with surgery only. In conclusion, only 3 of the cases were treated with antimycotica only, while the rest seven with a combined surgical and pharmaceutical regimen. Of the 3 cases treated conservatively, two died, yet with a concomitant malignancy and chemotherapy. In the review of *Candida tropicalis* cases from Miller et al. 4-6 weeks of intravenous amphotericin B at 0.5-1.0 mg/kg/d is suggested, followed by 2-6 months of treatment with oral azoles when susceptible organisms are isolated [27]. The total length of therapy should be determined empirically, but a continuation is recommended until normalisation of ESR, clinical and radiological resolution of the inflammatory changes.

In reports published later than 2000, the six-patient case series from Hendrickx et al. revealed two patients with *Candida tropicalis*

spondylodiscitis, with possible risk factors the parenteral nutrition and previous by-pass operation with neutropenia respectively [22]. In both cases, both fluconazole and amphotericin B were administrated (nevertheless not simultaneously) for 16 and 20 weeks respectively and led to biochemical and radiological healing.

Torres-Ramos et al. published a case of *Candida tropicalis* spondylodiscitis of the thoracic spine in a presumed immune-competent patient, which was uneventfully healed with surgical debridement and amphotericin B plus vancomycin therapy for 12 weeks [15].

The review osteomyelitis cases due to *Candida tropicalis* from Shaikh et al. [33] added 3 more cases of spondylodiscitis to the existing literature. Their case regarded a spondylodiscitis in L1/L2 with an epidural abscess in an immune-competent female patient. Therapy included the drainage of the abscess and a six-week treatment with liposomal amphotericin B, followed by oral fluconazole for 6 months.

The choice of pharmaceutical agents for the treatment depends on the clinical status of the patient and on the physician's knowledge of the species and antifungal susceptibility of the isolate. Historically, amphotericin B was the most frequently used agent, followed by pyrimidine (flucytosine). Now, with the availability of newer agents with *in vitro* activity against *Candida* species, more options are available. These include azoles (ketoconazole, fluconazole, itraconazole, and variconazole), lipid-associated formulations of amphotericin B (amphotericin B lipid complex, amphotericin B colloidal dispersion, and liposomal amphotericin B) and candidas (casposfungin) [33].

According to the guidelines of the Infectious Diseases Society of America for the treatment of candidiasis, *Candida tropicalis* in patients with no recent use of azoles may be treated with surgical debridement and amphotericin B at 0.6 mg/kg/d followed by fluconazole at 6 mg/kg/d for 6-12 months [26]. Fluconazole at 12 mg/kg/d (800 mg/d in a 70 kg patient) may also be suitable, particularly in less critically ill patients. In the review of Eggimann et al. for the management of candidiasis, fluconazole is considered to be equal to amphotericin B in the treatment of candidemia [47]. It's high oral bioavailability, excellent tolerability and limited drug interactions rapidly made fluconazole the first-choice agent for almost all candidiasis in immune-competent hosts.

In our case, intravenous fluconazole was administrated at 400 mg daily in a single dose for 2 weeks and consequently for another 6 weeks with an oral dose of 400 mg once daily, which was reduced at 200 mg daily for 4 weeks to conclude a 12 weeks therapy.

The trend in the treatment of vertebral pyogenic osteomyelitis is mainly conservative, in terms of causative antibiotic therapy and bracing, largely depending on the patient's immune status. For cases where either emergency or elective surgery is required, indications are well established; epidural abscess, progressive neurologic deficit, structural failure or segmental kyphosis, septic pseudarthrosis, severe pain and failure of conservative therapy, are factors may lead to the decision for surgical debridement of the disc and adjacent bony structures with instrumented fusion and reconstruction of one or both columns [40,47-50]. Which in return confirm the diagnosis; decrease the antimicrobial treatment duration, as well as all the complications related to the prolonged hospital stay. The tendency seems to be equal regarding the treatment of *Candida tropicalis* vertebral osteomyelitis. Long-term antifungal therapy is usually combined with surgical debridement (11 cases of the current literature); one case has been treated with surgery only and 5 cases with an antifungal combination or monotherapy.

Conclusion

Although candidal spondylodiscitis is rare, fungal infection should be suspected as a causative pathogen in immunocompromised patients and elderly with chronic diseases. Without adequate treatment, the disease is progressive and leads to vertebral destruction and spinal cord and neural compression. Early recognition of fungal infection may be difficult until the patient either develops severe back pain with symptoms of impending cord compression or develops various grades of neurological deficits. The aim of treatment should be the eradication of infection, restoration and preservation of the structure and function of the spine and pain alleviation. Established pharmaceutical agents are amphotericin and/or fluconazole for a minimum of 3 months and surgical debridement of the disc with instrumented fusion is highly recommended.

Declaration of Conflicting Interests

The authors declared no conflicts of interest with respect to the authorship and/or publication of this article.

Funding

The authors received no financial support for the research and/or authorship of this article.

References

1. Aagaard T, Roed C, Dragsted C, Skinhøj P (2013) Microbiological and therapeutic challenges in infectious spondylodiscitis: a cohort study of 100 cases, 2006-2011. Scand J Infect Dis 45: 417-424.
2. Zimmerli W (2010) Clinical practice. Vertebral osteomyelitis. N Engl J Med 362: 1022-1029.
3. Cottle L, Riordan T (2008) Infectious spondylodiscitis. J Infect 56: 401-412.
4. Fantoni M, Treccarichi EM, Rossi B, Mazzotta V, Di Giacomo G, et al. (2012) Epidemiological and clinical features of pyogenic spondylodiscitis. Eur Rev Med Pharmacol Sci 16: 2-7.
5. O'Daly BJ, Morris SF, O'Rourke SK (2008) Long-term functional outcome in pyogenic spinal infection. Spine (Phila Pa 1976) 33: E246-253.
6. Jimenez-Mejias ME, de Dios Colmenero J, Sanchez-Lora FJ, Palomino-Nicas J, Reguera JM, et al. (1999) Postoperative Spondylodiscitis: Etiology, clinical findings, prognosis, and comparison with nonoperative pyogenic spondylodiscitis. Clin Infect Dis 29: 339-345.
7. Langlois S, Cedoz JP, Lohse A, Toussiot E, Wendling D (2005) Aseptic discitis in patients with ankylosing spondylitis: A retrospective study of 14 cases. Joint Bone Spine 72: 248-253.
8. Torda AJ, Gottlieb T, Bradbury R (1995) Pyogenic vertebral osteomyelitis: Analysis of 20 cases and review. Clin Infect Dis 20: 320-328.
9. Skaf GS, Kanafani ZA, Araj GF, Kanj SS (2010) Non-pyogenic infections of the spine. Int J Antimicrob Agents 36: 99-105.
10. Digby JM, Kersley JB (1979) Pyogenic non-tuberculous spinal infection: an analysis of thirty cases. J Bone Joint Surg Br 61: 47-55.
11. Sapico FL, Montgomerie JZ (1979) Pyogenic vertebral osteomyelitis: Report of nine cases and review of the literature. Rev Infect Dis 1: 754-776.
12. Eisen DP, MacGinley R, Christensson B, Larsson L, Woods ML (2000) *Candida tropicalis* vertebral osteomyelitis complicating epidural catheterisation with disease paralleled by elevated d-Arabinitol/l-Arabinitol ratios. Eur J Clin Microbiol Infect Dis 19: 61-63.
13. Cebrían Parra JL, Saez-Arenillas Martín A, Urda Martínez-Aedo AL, Soler Ivañez I, Agreda E, et al. (2012) Management of infectious discitis. Outcome in one hundred and eight patients in a University Hospital. Int Orthop 36: 239-244.
14. Sakkas LI, Davas EM, Kapsalaki E, Boulbou M, Makaritsis K, et al. (2009) Hematogenous spinal infection in Central Greece. Spine (Phila Pa 1976) 34: E513-518.
15. Torres-Ramos FM, Botwin K, Shah CP (2004) *Candida* Spondylodiscitis: An unusual case of thoracolumbar pain with review of imaging findings and description of the clinical condition. Pain Physician 7: 257-260.
16. Gouliouris T, Aliyu SH, Brown NM (2010) Spondylodiscitis: Update on diagnosis and management. J Antimicrob Chemother 65 Suppl 3: iii11-24.
17. Yang SC, Fu TS, Chen LH, Chen WJ, Tu YK (2008) Identifying pathogens of spondylodiscitis: Percutaneous endoscopy or CT-guided biopsy. Clin Orthop Relat Res 466: 3086-3092.
18. D'Agostino C, Scorzoloni L, Massetti AP, Carnevalini M, d'Ettorre G, et al. (2010) A seven-year prospective study on spondylodiscitis: Epidemiological and microbiological features. Infection 38: 102-107.
19. Colmenero JD, Jiménez-Mejías ME, Sánchez-Lora FJ, Reguera JM, Palomino-Nicas J, et al. (1997) Pyogenic, tuberculous, and brucellar vertebral osteomyelitis: A descriptive and comparative study of 219 Cases. Ann Rheum Dis 56: 709-715.
20. Kaya S, Ercan S, Kaya S, Aktas U, Kamasak K, et al. (2014) Spondylodiscitis: Evaluation of patients in a tertiary hospital. J Infect Dev Ctries 8: 1272-1276.
21. Turunc T, Demiroglu YZ, Uncu H, Colakoglu S, Arslan H (2007) A comparative analysis of tuberculous, brucellar and pyogenic spontaneous spondylodiscitis patients. J Infect 55: 158-163.
22. Hendrickx L, Van Wijngaerden E, Samson I, Peetermans WE (2001) Candidal vertebral osteomyelitis: report of 6 patients, a review. Clin Infect Dis 32: 527-533.
23. Munk PL, Lee MJ, Poon PY, O'Connell JX, Coupland DB, et al. (1997) *Candida* osteomyelitis and disc space infection of the lumbar spine. Skeletal Radiol 26: 42-46.
24. Waldvogel FA, Medoff G, Swartz MN (1970) Osteomyelitis: A review of clinical features, therapeutic considerations and unusual aspects and osteomyelitis associated with vascular insufficiency. N Engl J Med 28: 316-322.
25. Gathe JC Jr, Harris RL, Garland B, Bradshaw MW, Williams TW Jr (1987) *Candida* osteomyelitis. Report of five cases and review of the literature. Am J Med 82: 927-937.

26. Pappas PG, Rex JH, Sobel JD, Filler SG, Dismukes WE, et al. (2004) Guidelines for treatment of candidiasis. *Clin Infect Dis* 38: 161-189.
27. Miller DJ, Mejicano GC (2001) Vertebral osteomyelitis due to *Candida* species: Case report and literature review. *Clin Infect Dis* 33: 523-530.
28. Ugarriza LF, Cabezudo JM, Lorenzana LM, Rodríguez-Sánchez JA (2004) *Candida albicans* spondylodiscitis. *Br J Neurosurg* 18: 189-192.
29. Fraser VJ, Jones M, Dunkel J, Storfer S, Medoff G, et al. (1992) Candidemia in a tertiary care hospital: epidemiology, risk factors, and predictors of mortality. *Clin Infect Dis* 15: 414-421.
30. Wenzel RP (1995) Nosocomial candidemia: Risk factors and attributable mortality. *Clin Infect Dis* 20: 1531-1534.
31. Chai LY, Denning DW, Warn P (2010) *Candida tropicalis* in human disease. *Crit Rev Microbiol* 36: 282-298.
32. Euba G, Narváez JA, Nolla JM, Murillo O, Narváez J, et al. (2008) Long-term clinical and radiological magnetic resonance imaging outcome of abscess-associated spontaneous pyogenic vertebral osteomyelitis under conservative management. *Semin Arthritis Rheum* 38: 28-40.
33. Shaikh Z, Shaikh S, Pujol F, Trauber D, Sam M (2005) *Candida tropicalis* osteomyelitis: Case report and review of literature. *Am J Med* 118: 795-798.
34. Yasar K, Pehlivanoglu F, Cicek G, Sengoz G (2012) The evaluation of the clinical, laboratory and the radiological findings of the fifty-five cases diagnosed with tuberculous, brucellar and pyogenic spondylodiscitis. 3: 17-20.
35. Hayes WS, Berg RA, Dorfman HD, Freedman MT (1984) Case report 291. Diagnosis: *Candida* discitis and vertebral osteomyelitis at L1-L2 from Hematogenous spread. *Skeletal Radiol* 1: 284-287.
36. Pennisi AK, Davis DO, Wiesel S, Moskovitz P (1985) CT appearance of *Candida* diskitis. *J Comput Assist Tomogr* 9: 1050-1054.
37. Bruns J, Hemker T, Dahmen G (1986) Fungal spondylitis. A case of *Torulopsis glabrata* and *Candida tropicalis* infection. *Acta Orthop Scand* 57: 563-565.
38. Kashimoto T, Kitagawa H, Kachi H (1986) *Candida tropicalis* vertebral osteomyelitis and discitis. A case report and discussion on the diagnosis and treatment. *Spine (Phila Pa 1976)* 11: 57-61.
39. Friedman BC, Simon GL (1987) *Candida* vertebral osteomyelitis: Report of three cases and a review of the literature. *Diagn Microbiol Infect Dis* 8: 31-36.
40. Swanson AN, Pappou IP, Cammisa FP, Girardi FP (2006) Chronic infections of the spine: surgical indications and treatments. *Clin Orthop Relat Res* 444: 100-106.
41. Herzog W, Perfect J, Roberts L (1989) Intervertebral diskitis due to *Candida tropicalis*. *South Med J* 82: 270-273.
42. Sugar AM, Saunders C, Diamond RD (1990) Successful treatment of *Candida* osteomyelitis with fluconazole. A non-comparative study of two patients. *Diagn Microbiol Infect Dis* 13: 517-520.
43. Ferra C, Doebbeling BN, Hollis RJ, Pfaller MA, Lee CK, et al. (1994) *Candida tropicalis* vertebral osteomyelitis: a late sequela of fungemia. *Clin Infect Dis* 19: 697-703.
44. Sebastiani GD, Galas F (2001) Spondylodiscitis due to *Candida tropicalis* as a cause of inflammatory back pain. *Clin Rheumatol* 20: 435-437.
45. Garbino J, Schnyder I, Lew D, Bouchuiguir-Wafa K, Rohner P (2003) An unusual cause of vertebral osteomyelitis: *Candida* species. *Scand J Infect Dis* 35: 288-291.
46. Cone LA, Byrd RG, Potts BE, Wuesthoff M (2004) Diagnosis and treatment of *Candida* vertebral osteomyelitis: Clinical experience with a short course therapy of amphotericin B lipid complex. *Surg Neurol* 6: 234-237.
47. Eggimann P, Garbino J, Pittet D (2003) Management of *Candida* species infections in critically ill patients. *Lancet Infect Dis* 3: 772-785.
48. Dimar JR, Carreon LY, Glassman SD, Campbell MJ, Hartman MJ, et al. (2004) Treatment of pyogenic vertebral osteomyelitis with anterior debridement and fusion followed by delayed posterior spinal fusion. *Spine*: 326-332.
49. Gorenssek M, Kosak R, Travnik L, Vengust R (2013) Posterior instrumentation, anterior column reconstruction with single posterior approach for treatment of pyogenic osteomyelitis of thoracic and lumbar spine. *Eur Spine J* 2: 633-641.
50. Titlic M, Josipovic-Jelic Z (2008) Spondylodiscitis. *Bratisl Lek Listy* 109: 345-347.

Citation: Rami AY, Sotirios MG, Lukas L, Frank H, Jorg F (2016) Fungal Spondylodiscitis: Unexpected Diagnosis, Case Report and Literature Review. *J Spine* 5: 313. doi:[10.4172/2165-7939.1000313](https://doi.org/10.4172/2165-7939.1000313)

OMICS International: Publication Benefits & Features

Unique features:

- Increased global visibility of articles through worldwide distribution and indexing
- Showcasing recent research output in a timely and updated manner
- Special issues on the current trends of scientific research

Special features:

- 700+ Open Access Journals
- 50,000+ editorial team
- Rapid review process
- Quality and quick editorial, review and publication processing
- Indexing at major indexing services
- Sharing Option: Social Networking Enabled
- Authors, Reviewers and Editors rewarded with online Scientific Credits
- Better discount for your subsequent articles

Submit your manuscript at: <http://www.omicsonline.org/submit/>