

Functional Shaping of the Maxillary Denture Base in Oral Rehabilitation Patient: A Case Report

Istvan Lampe^{1*}, Pal Redl¹, Dora Horvath², Tunde Radics¹ and Csaba Hegedus¹

¹Faculty of Dentistry, Department of Prosthetic Dentistry, University of Debrecen, Debrecen, Hungary

²Faculty of Dentistry, Department of Oral and Maxillofacial Surgery, University of Debrecen, Debrecen, Hungary

*Corresponding author: Istvan Lampe, MD, LDS Assistant Professor, University of Debrecen, Faculty of Dentistry, Department of Prosthetic Dentistry, Debrecen, Nagyerdei krt. 98, Hungary, Tel/Fax: +36-52-254-349, E-mail: lampe.istvan@dental.unideb.hu

Rec date: June 04 2016; Acc date: June 23, 2016; Pub date: June 28, 2016

Copyright: © 2016 Lampe I, et al. This is an open-access article distributed under the terms of the Creative Commons Attribution License, which permits unrestricted use, distribution, and reproduction in any medium, provided the original author and source are credited.

Abstract

Aim: The restoration of phonation and swallowing for oral rehabilitation patients is a challenging part of the rehabilitation process. The final configuration of the oral surface of the maxillary denture base can be difficult and time consuming. Special impression technique of the oral cavity has been carried out in a patient with partially resected tongue to create the replica of the necessary shape of the palatal region of the denture. The aim of this report is to present the technique and the advantages of the use of irreversible hydrocolloid impression material during the rehabilitation process of a surgically treated patient with oral cancer.

Method: A small amount of irreversible hydrocolloid impression material placed on the oral surface of the maxillary record base makes it possible to determine the preliminary configuration of the surface. Then the final surface is created by replacing the impression material by wax, and by modifying the configuration according to functional tests carried out during trial placement.

Results: The patient presented in this paper reported improved swallowing function and phonation six weeks after denture placement. The functional x-ray examination made three months after denture delivery showed apparent improvement of the swallowing function. The current article demonstrates how easy it was to apply irreversible hydrocolloid impression material in this specific case.

Keywords: Irreversible hydrocolloid; Oral; Denture base; Swallowing, Functional shaping

Introduction

During the rehabilitation process of patients with oral cancer, the proper reconstruction of occlusion, articulation, phonation and swallowing offers the patient a better quality of life. The anatomical and functional situation following the resection of soft and hard tissues poses a challenge for constructing a well-functioning prosthesis. The removal of just a small amount of the hard and soft tissues of the oral cavity or the base of the tongue can lead to decreased swallowing function [1,2] or aspiration [3]. These aspects must be considered when planning the rehabilitation treatment.

Speech and swallowing can be aided by augmenting the palatal surface of the denture. Palatal augmentation prostheses can be manufactured in several ways. After obtaining a cast, a temporary acrylic resin template can be made, gradually modified and incorporated into the denture base [4]. Dawis extended inferiorly the palatal part of the prosthesis with red wax, which was subsequently replaced with auto-polymerizing acrylic and modified for several weeks until final shape was achieved [5]. Jacob suggests augmentation on the palate with baseplate wax that is modified with the help of pressure indicator paste or tissue conditioners, and finally replaced by acrylic [6]. Diagnostic resin augmentation prosthesis can also be made, once the appropriate palatal contour has been determined, a definitive prosthesis can be constructed [7].

There has been no mention made in the literature concerning the use of irreversible hydrocolloid impression material for the functional registration of the space and range of movements of the resected tongue as yet.

In this case report the application of a speech and swallowing aid prosthesis was decided because the patient reported difficulties when swallowing or speaking after the resection of the tongue. The aim of this report was to show the technique and the advantages of the use of irreversible hydrocolloid impression material during the rehabilitation process of a surgically treated patient with oral cancer.

Case Report

A 56 year old Caucasian male was treated surgically because of a malignant tumor on the floor of his mouth. Resection of the left side of the mandible and the floor of the oral cavity was carried out, including the removal of the left side of the tongue as well. Clinical examination of the oral cavity one year after the operation revealed that the edentulous patient could perform only limited tongue movements. Contact of the tongue and the palate could be detected only when the distance between the alveolar ridges was 10 mm. The patient could hardly swallow even liquids. A preliminary irreversible hydrocolloid impression (Alginate Plus; Henry Schein Inc., Melville, NY, USA) was made using stock trays (ASA Dental S.p.A., Bozzano, Italy). The impression was checked for integrity and poured using dental stone (Begostone; Bego, Bremen, Germany). The preliminary cast was used to manufacture a custom impression tray for the special anatomical

situation of the patient's oral cavity. The tray was checked and trimmed, and a final impression was made using the mucostatic impression technique (Impression Compound; Kerr Italia S.p.A., Salerno, Italy and S.S. White Impression Paste; S.S. White Group, Gloucester, England). Occlusal rims were made and trimmed according to the centric maxillomandibular relation. Trial dentures were manufactured. A small amount of irreversible hydrocolloid impression material (Alginate plus; Henry Schein Inc., Melville, NY, USA) was placed onto the oral surface of the maxillary record base, and with both trial dentures in the mouth and in centric maxillomandibular position the patient was asked to do full range of movements of the tongue, to move alternatively the tip and the dorsum of the tongue against the impression material as wide as he could. Furthermore the patient was asked to move the tip of his tongue against the incisive papilla and to keep this extended position, then he was requested to make circular movements, the dorsum of the tongue had to be elevated several times against the central part of the palate until the irreversible hydrocolloid had set (Figure 1).

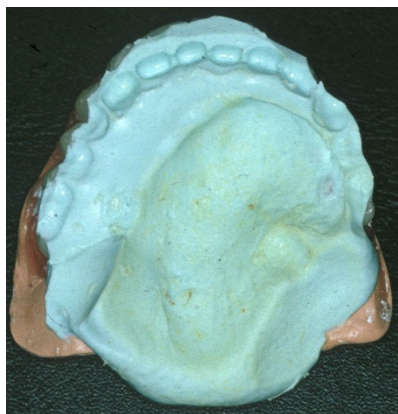


Figure 1: Set irreversible hydrocolloid impression material on trial record base; the contours are shaped by tongue movements.

Following the setting of the irreversible hydrocolloid the trial dentures were transferred to the dental technician and the irreversible hydrocolloid was replaced by wax (Bredent modellierwachs; Bredent, Senden, Germany) (Figure 2a and 2b).



Figure 2a: Changing the irreversible hydrocolloid to wax in the lab.

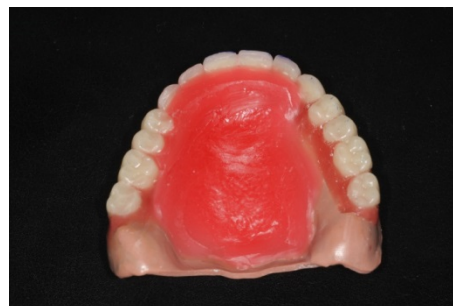

Figure 2b: The preliminary wax pattern of the palate.

During the trial placement procedure functional tests of phonation and swallowing were carried through. First the patient was asked to check if contact in between denture base and tongue could be carried out. Then the patient was asked to pronounce the three basic types of vocal sounds several times, which was followed by the swallowing of a small amount of water. The wax pattern of the palate was modified according to the needs determined by the functional tests. Wax was removed from and added to certain places until good speaking and swallowing functions were achieved. When forming vocal sounds the sufficient air-flow space between the tongue and the surface of the artificial palate could be detected, while checking labial sounds the contact between the lips and the artificial teeth could be controlled. Proper pronunciation of dentoalveolar and alveopalatal sounds was achieved by controlling the contact between the tip of the tongue and the frontal area of the palate of the trial denture, while the quality of palatovelar sounds was affected by the contact of the dorsum of the tongue and the artificial palate. When swallowing and speaking were comfortably and easily carried out by the patient, the functional shaping of the palate was completed. The denture was processed and delivered (Figure 3).

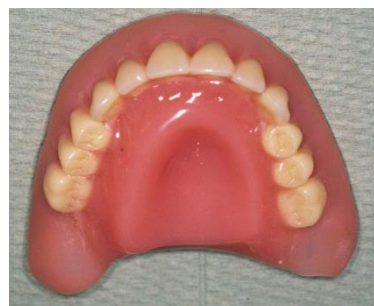

Figure 3: Completed maxillary denture showing palatal augmentation for speech and swallowing aid.

Two Osseo integrated implants with ball retention abutments (DenTi, Denti-System, Hungary) were used to obtain good stability and retention for the lower over denture. Function was checked, the denture was evaluated and the necessary corrections were made. The patient was recalled for check-ups on a regular basis and necessary corrections of the denture were made. After a six-week accommodation period, the patient reported good swallowing function even when eating solid food, while phonation and speaking had noticeably improved. Three months after denture delivery a real

time X-ray was made. With the denture in place the mechanism of swallowing seemed much more functional and easier, while without the device obvious efforts were visible during bolus formation, since the bolus did not reach the distal wall of the pharynx, which got into the esophagus rather passively than as a result of an active process, and a great amount of air was also swallowed. The radiological findings correlated well with the patient's reports on improved function (Figure 4a and 4b).

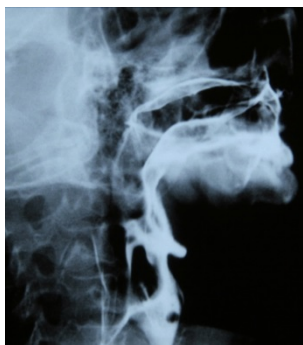

Figure 4a: Swallowing without the device: the bolus does not reach the distal wall of the pharynx; it gets into the esophagus more passively than as a result of an active process, great amount of air is visible in the esophagus.

For evaluating the improvement of swallowing, chewing and speech we used the questions of the University of Washington Quality of Life Questionnaire (UW-QOL v4).

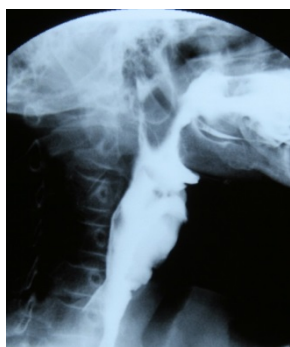

Figure 4b: Swallowing with device in position: easy and functional swallowing.

Before rehabilitation the patient could only swallow liquid food, sometimes "it went the wrong way", he could not chew as he had no teeth, and only his family could understand his speech. Three months after delivery he could swallow as well as ever, he could eat soft solids, but could not chew certain foods; moreover, his speech could be understood over the phone though he had some difficulties saying some words.

Discussion

The surgical treatment of intraoral malignant tumors frequently involves partial resection of the tongue. In the rehabilitation phase it is

absolutely essential to establish adequate contact and seal between the resected tongue and the palate to improve swallowing and phonation function for a better quality of life for the patient. The current case report describes the advantages of the use of irreversible hydrocolloid impression material to configure the preliminary shape of the maxillary denture base of an edentulous patient with resected tongue.

Studies of the physiology of swallowing show that the swallowed bolus is pushed by a continuous peristaltic drive of the tongue and palate into the pharynx [8], which occurs during the maximal intercuspation phase of the masticatory cycle [9]. The tongue executes peristaltic-like movement and transfers the bolus into the pharynx. The involuntary pharyngeal phase of swallowing begins at this point [10].

Good swallowing function needs adequate pressure loaded onto the palate and continuous contact and seal between the tongue and the palate during the oral phase. In most of the cases the resected tongue cannot even touch the palate because of limited mobility. Pressure up to 10 kPa in the midline of the tongue can be generated more efficiently by bringing the teeth into centric occlusion and developing a lip seal by the contraction of the orbicularis oris. The main muscle which is involved in generating the tongue pressure is the mylohyoid muscle [11]. Logemann [12] stated the necessity of reshaping/lowering the palate of the denture in patients who had undergone resection. The contact of certain parts of the tongue and palate is also necessary for forming various sounds, which is needed for good intelligible speech. An adequate shape of the oral surface of the maxillary denture base and sufficient pressure and contact between the tongue and the denture base are essential for a good swallowing function

Placement of irreversible hydrocolloid impression material on the maxillary record base during the trial procedure can be used to register the space of movements of the resected tongue. The application of this material is easy, the setting time is long enough to give adequate time for functional movements of the tongue. Furthermore the registration procedure is easy to repeat in case of failure. The viscosity of the material is just excellent for the procedure. Type I viscosity impression materials would be too viscous and hard to be shaped by the movements of the tongue, while type II and III are excessively flowable for registering the space covered during functional movements of the tongue. In the laboratory phase the irreversible hydrocolloid impression material can easily be replaced by wax and the final wax pattern of the palate of the denture can be determined by modifying the contour while adding or removing wax according to the result of functional swallowing and phonation tests. The use of the irreversible hydrocolloid impression material shortens the configuration phase since the movements of the tongue dissipate the impression material on the palatal surface of the maxillary trial denture according to the desired shape determining the preliminary bulk and configuration, only slight modifications are needed, fabrication of a temporary acrylic template is not necessary. The modification process is easy and flexible as the whole artificial palate is made up of wax.

Functional shaping of the maxillary denture base has already been used in five patients now; all of them have reported improvements of all functions considering the results of the UW-QOL v4. As the number of patients treated increases detailed QOL assessment is planned for statistical analysis.

Acknowledgement

X-ray examination was done by Dr. Judit Decsy, Department of Radiology, University of Debrecen

References

1. McConnel FM, Logemann JA, Rademaker AW (1994) Surgical variables affecting postoperative swallowing efficiency in oral cancer patients: a pilot study. *Laryngoscope* 104: 87-90.
2. Zuydam AC, Rogers SN, Brown JS, Vaughan ED, Magennis P (2000) Swallowing rehabilitation after oro-pharyngeal resection for squamous cell carcinoma. *Br J Oral Maxillofac Surg* 38: 513-518.
3. Logemann JA (1994) Aspiration in head and neck surgical patients. *Ann Otol Rhinol Laryngol* 94: 373-376.
4. Beumer J, Marunick MT, Curtis TA, Roumanas E (1996) Acquired Defects of the mandible. In: Beumer J (Ed). *Maxillofacial Rehabilitation: Prosthodontic and Surgical Considerations*. Ishiyaku Euro America, Inc.: St.Louis, Tokyo 182.
5. Dawis JW, Cathy Lazarus MA, Logemann J, Hurst PS (1987) Effect of a maxillary glossectomy prosthesis on articulation and swallowing. *J Prost Dent* 57: 715-719.
6. Jacob RF (2004) Maxillofacial prosthodontics for the Edentulous Patient. In: Zarb GA, Bolender CL (Eds). *Prosthodontic Treatment for Edentulous Patients* (12th edn). Mosby, St. Louis, MO 461.
7. Removable Partial Denture Considerations in Maxillofacial Prosthetics. In: Carr AB, McGivney PG, Brown DT (2005) *McCracken's Removable Partial Prosthodontics* (11th edn). Mosby, St. Louis, Missouri 413.
8. Curtis DJ, Cruess DF, Dachman AH (1985) Normal erect swallowing. Normal function and incidence of variations. *Invest Radiol* 20: 717-726.
9. Palmer JB, Rudin NJ, Lara G, Crompton AW (1992) Coordination of mastication and swallowing. *Dysphagia* 7: 187-200.
10. Jansen van Rensburg BG (1995) *Oral Biology* (1st edn). Quintessence, Chicago 505-509.
11. Ferguson DB (1999) *Oral Bioscience*. (1st edn). Churchill Livingstone, London 273-278.
12. Logemann JA, Kahrilas PJ, Hurst P, Davis J, Krugler C (1989) Effects of intraoral prosthetics on swallowing in patient with oral cancer. *Dysphagia* 4: 118-120.