

Focal Epithelial Hyperplasia Prevalence in an Endemic Population, Molecular Association of HPV-13 to Asymptomatic Patients and Comparison Between Three Elementary Schools of Different Income Levels

Abraham Zavala-Garcia^{1*}, Roberto Briceño-Mena¹, Lesly Romero-Beltran¹, Giorgio Alberto Franyuti Kelly², Jose Ceron-Espinosa³ and Maria R Gonzalez-Losa¹

¹Virology Laboratory, Regional Research Center, Autonomous University of Yucatan, Mérida, Yucatán, Mexico

²Medical IMPACT, Infectious Diseases Department, Mexico City, Mexico

³Dermatology Center of Yucatan, Yucatan, Yucatan Health Services (SSY), Mérida, Yucatán, Mexico

*Corresponding author: Abraham Zavala-García, Residence of Gynecology and obstetrics, Service of Gynecology and Obstetrics, Hospital Ángeles Pedregal, Mexican Faculty of Medicine La Salle University, Road to Santa Teresa #1055, Col. Héroes de Padierna, CP 10700, Mexico City, Tel: 55 7609-1384; E-mail: abrahamzavala60@hotmail.com

Received date: September 08, 2017; Accepted date: October 26, 2017; Published date: October 30, 2017

Copyright: ©2017 Zavala-García A, et al. This is an open-access article distributed under the terms of the Creative Commons Attribution License, which permits unrestricted use, distribution, and reproduction in any medium, provided the original author and source are credited.

Abstract

Heck's disease, or Focal Epithelial Hyperplasia (FEH), caused by Human Papilloma Virus (HPV) subtypes 13 and mainly 32, is a rare and benign pathology of the oral mucosa; diagnosis is confirmed by PCR analysis.

This is a common disease in the Mayan and other Native-American populations, most frequently between 2-13 years. Risk factors include lower income class, poor hygiene and genetic predisposition.

This cross-sectional study aims to determine the prevalence of clinically compatible lesions of FEH in children from low, middle and high-income in 3 elementary schools in Yucatan, Mexico.

Clinical evaluation was conducted and documented for later analysis by a dermatologist familiar with FEH. Samples were taken and HPV-13 was identified by PCR.

The total of 186 subjects were analyzed from the low-income elementary school, with 41 subjects presenting FEH lesions and 76 presented HPV-13 upon PCR analysis. In the middle-income school, of the 144 subjects studied, 3 had FEH lesions and 8 presented HPV-13 upon PCR analysis. In the high-income elementary school, 96 students were studied, and none presented FEH lesions, however, 6 had HPV-13 positivity.

FEH and HPV-13 prevalence were inversely proportional to socioeconomic status. Lacking an association to a particular gender or difference in the age groups studied.

Keywords: Focal epithelial hyperplasia; Papillomavirus; Heck's disease; HPV-13

Introduction

Focal epithelial hyperplasia (FEH) or Heck's disease is a rare and benign pathology of the oral mucosa. Described formally in 1965 in Native-Americans by Heck [1], this pathology is frequent in populations of 2-13 years of age, and its incidence is unequally distributed worldwide, affecting Native-Americans and indigenous populations the most [1-6]. There is no concrete evidence of affection of a particular male or female gender, as this varies with previous studies [7]. These lesions are characterized by proliferative multiple hyperplastic lesions with very well defined limits, with a tendency to coalesce as they increase in diameter, adopting a cobblestone appearance. These lesions can be found in all of the extent of the oral mucosa epithelium, including lips, tongue and hard palate. The former being the most frequent site of lesions, specifically the lower lip [5]. Lesions tend to appear at an early age, usually before the age of five,

and persist until the early teenage years. There are however, rare cases in which lesions persist until adulthood. There are no longitudinal studies that can rule out a malignant transformation, however, a benign course is the usual natural history of disease. Histological characteristics include a squamous epithelium (oral mucosa) with parakeratosis, hyperkeratosis, acanthosis, verrucous proliferation, marked papillomatosis, hyperplasia of basal cells and isolated perinuclear cellular vacuolization (koilocytosis), cellular binucleation and nuclear irregularities [5].

Etiologically, the greatest risk factor for the development of FEH is the presence of Human Papillomavirus (HPV), generally HPV-13 [5]. Other subtypes have been implied, such as HPV-32. There seems to be a strong genetic factor predisposing certain populations to infection and proliferation of FEH. In case of the Mexican population, HLA-DR4 (DRB1*0404), an allele that prompts a strong susceptibility to HPV-13, is frequently present in Mayan populations located in southeastern Mexico [8].

This study took place in a rural Mayan community previously studied epidemiologically for the evidence of presence of Heck's disease [9]. The scope of the present study is to document the prevalence of Heck's disease in a rural community with an important indigenous population and compare it to an urban community with a more mestizo population. Also we seek to molecularly determine the presence of HPV-13 in patients with and without lesions clinically compatible with Heck's disease. Previously described risk factors also include indigenous ethnic heritage, lower economic status, family history of the disease, and malnutrition [9].

Materials and Methods

Study population

A cross-sectional study was conducted in Chemax and Merida, Yucatan, Mexico. Chemax is a rural community with a predominant Mayan population, endemic to Heck's disease, they subject to numerous epidemiological studies of Heck's disease, however to be best of our knowledge, this is the first time in which the epidemiology of prevalence of HPV-13 in asymptomatic patients is undertaken in this region in different socioeconomic levels and the largest population studies (n=426). Merida is the capital city of Yucatán, with a greater socioeconomic status and a lesser Mayan population. All participants were examined with informed consent during 2014. A total sample of 426 subjects were chosen at random, with an equal gender ratio, in children between the age of 6-14 y to determine the clinical and viral prevalence in elementary school from three communities: One from a low income (LI) elementary in Chemax, another one from a middle income (MI) section in Merida, and one from a middle-high income (HI) school in Merida. Population samples were taken from each school depending on the total population of each elementary, thus 186 students were studied in Chemax, 144 from the MI section in Merida, and lastly, 96 from the HI school in Merida. In the LI elementary, 16 boys and 16 girls from each of the six grades were analyzed. In the MI elementary, 12 boys and 12 girls from each of the six grades were analyzed. In the HI elementary, 8 boys and 8 girls from each of the six grades were analyzed.

Firstly, for the clinical prevalence determination, each subject from the population sample of each school was examined for FEH compatible lesions: Painless multiple or single verrucous-type lesions with well-defined limits. For statistical analysis, central tendency measures, Tukey's multiple comparison test and two-way ANOVA with a P value of <0.05 were used. Biostatistic program Prism graphpad V5 was used.

Secondly, for the HPV-13 prevalence, each subject from the population sample was swabbed with an oral brush, regardless of the presence or absence of lesions compatible with FEH.

Specimen collection

Cells from the oral cavity were collected by brushing. Cell samples were agitated in 5 ml of phosphate-buffered saline (PBS) with antibiotics (penicillin 500 U/ml, streptomycin 500 g/ml, gentamicin 4 mg/ml). All participants were asked to carry out oral hygiene procedures with purified water and then to provide a saliva sample in a sterile bottle. Both the cell and saliva samples were kept at 4°C during transportation to the virology laboratory at the Regional Research Center.

Clinical data was obtained through physical examination by an experienced healthcare professional and direct interview with patients or, in the case of child subjects, their mothers were carried out by an experienced social worker.

Oral brushing cells and saliva were pelleted by centrifugation and re-suspended in 1 ml of PBS and stored at 70°C until further analysis. Cell suspensions were heated at 95°C for 10 min prior to PCR cycling.

Detection of FEH compatible lesions

All children in this study were analyzed by a team of doctors familiar with FEH that used criteria of single or multiple fibrous, well-defined lesions like nodules and papules which frequently coalesce, with a size range from 0.1 cm to 1 cm in diameter. These lesions are usually painless and mainly found on the mucosa epithelia of the lower lip, upper lip, tongue and hard palate; as described by Cuberos et al. 2006. Photographic evidence was taken and then later analyzed by a dermatologist familiar with this condition in the region (Figure 1).

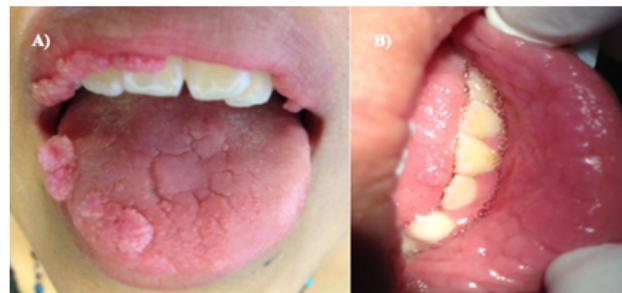

Figure 1: Typical FEH lesions, appearing in upper lip and tongue (panel A) and mucosa of bottom lip with the characteristic cobblestone pattern (panel B).

Detection of Human papillomavirus type 13

The presence of HPV 13 DNA in the cells was determined by PCR with specific primers that amplified a 240-bp fragment of L1 gene. The PCR was performed in 25 µl reaction mix containing 1X PCR buffer, 3 mM MgCl₂, 200 mM dNTPs, 25 pmol of each primer, and 1.0 unit of Taq polymerase. Thermal cycling conditions were: 94°C for 1 min, followed by 38 cycles of 94°C for 45 s, 55°C for 45 s and 72°C for 45 s, and a final extension of 72°C for 10 min.

A sample previously typified as HPV 13 by restriction fragment length polymorphism was used as a positive control. A PCR mix with water in place of DNA was used as a negative control.

Results

A total of 426 samples were analyzed at random from the three elementary schools. The mean age of the population was 8.69 years. The mean age for the male population (213 subjects) was 8.72 years, while the female (213 subjects) mean age was of 8.66 years (non-significant difference). Information summarized in Table 1.

In the population of 186 students from the LI elementary, 41 subjects (22.04%) had lesions compatible with FEH, (23 male/18 female) a statistical significant amount when compared to the rest of the population (P<0.0001). Moreover, 76 (42.47%) had the presence of

HPV-13 DNA upon PCR analysis ($P < 0.0001$). The 41 subjects that presented FEH lesions were all HPV positive upon PCR analysis. The remaining 35 HPV positive subjects had no apparent FEH lesions. There was no statistically significant difference in gender HPV prevalence (Male 32/Female 44 subjects) as see in Figure 2.

Elementary School	N	FEH Lesions	%	HPV-13 Positive	%
LI	186	41	22.04	76	40.86
MI	144	3	2.08	8	5.55
HI	96	0	0	6	6.25
Total	426	44	10.32	90	21.12

Table 1: Subjects from all three elementary schools and data obtained.

Interestingly, while HPV prevalence remained constant through grades one through six, there was a tendency for clinical manifestations to be less frequent in children of older age.

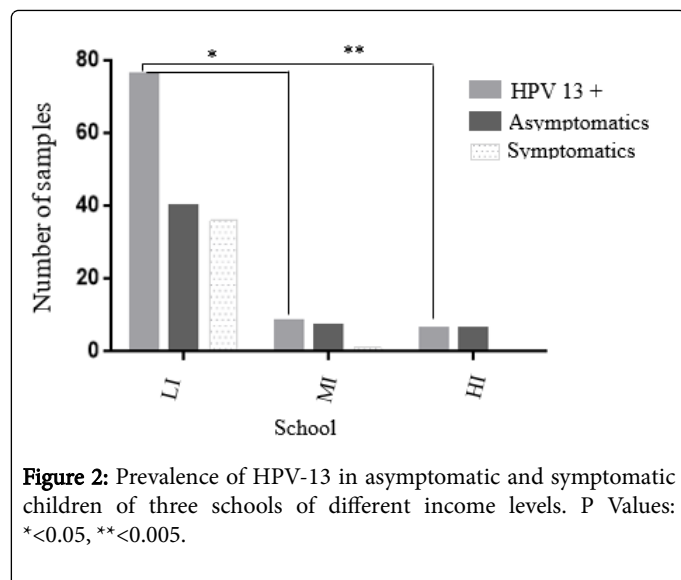


Figure 2: Prevalence of HPV-13 in asymptomatic and symptomatic children of three schools of different income levels. P Values: * < 0.05 , ** < 0.005 .

In the MI elementary, there were 3 cases compatible with clinical FEH lesions (3 male/0 female), with a mean age of 8.33 (8.33 male) years. However, of the 144 students, 8 (5.55%) had the presence of HPV-13 DNA upon PCR analysis (3 Male/5 Female), with a mean age of 8.87 years (9.20 Male/8.33 Female). Interestingly, of the 3 males with FEH clinically compatible lesions, one was not HPV-13 positive upon PCR analysis. This finding could be caused by another HPV genotype, albeit a less frequent genotype, such as HPV-32 (Figure 3).

In the HI elementary, there were no cases compatible with clinical FEH lesions. However, of the 96 students, 6 (6.25%) had the presence of HPV-13 DNA upon PCR analysis (0 Male/6 Female) with a mean age of 8.33 years.

In comparing the three communities, the LI community had a significantly higher prevalence of FEH lesions and HPV-13 prevalence when compared to the MI ($P < 0.001$) and HI ($P < 0.005$) communities. However, there was no statistically significant difference in HPV prevalence between the MI and HI communities. These results align to our hypothesis of a greater HPV prevalence, lower the income and the greater the Mayan population.

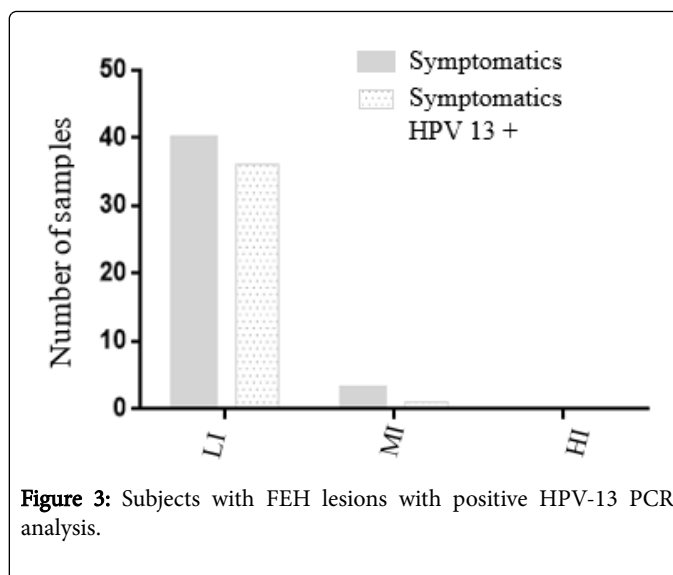


Figure 3: Subjects with FEH lesions with positive HPV-13 PCR analysis.

We found no difference in age distribution for HPV prevalence or for clinical manifestations of FEH. However, the age range was 6-14 years of age; perhaps on a larger range of ages there would be an apparent age group with a higher prevalence of FEH [9]. Also, we found no difference in gender prevalence (Figure 4).

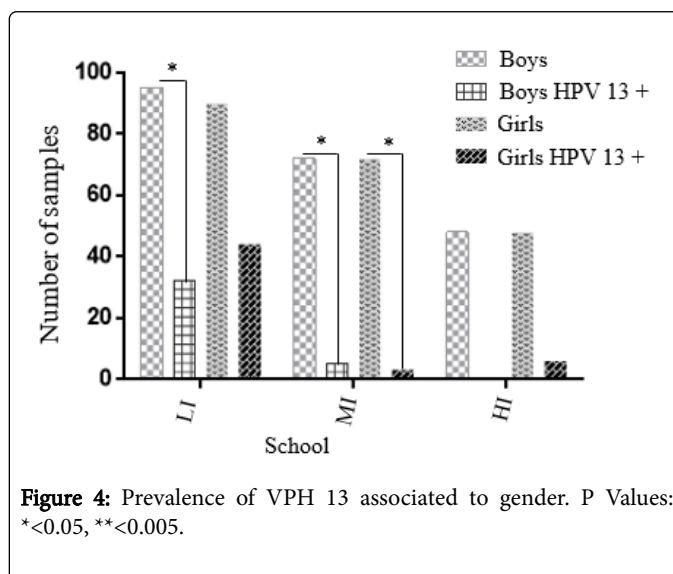


Figure 4: Prevalence of VPH 13 associated to gender. P Values: * < 0.05 , ** < 0.005 .

Discussion

Focal Epithelial Hyperplasia is a disease that does not receive much attention or funding because of its benign nature. However, no longitudinal studies have been conducted to discard the possibility of malignancy or other oral consequences, nor the psychological impact it may have on children growing up with FEH lesions.

Previous studies have shown greater prevalence according to gender and age. (However, for this study, no statistically significant difference could be reported between genders or age. Most studies reported a greater prevalence in the first two decades of life, which could explain our lack of age group with a greater prevalence of FEH lesions or HPV prevalence.

In this study, we found an obvious association between HPV-13 and FEH lesions. However, we did have a case in which FEH compatible lesions were not associated with HPV-13 upon PCR analysis. There have been other HPV subtypes reported to cause FEH lesions, such as HPV-32. In this study, we did not seek other HPV subtypes, so the subject who had FEH lesions could present HPV-32, or other subtypes previously reported in the literature [10-18].

Conducting this study, we also found that many of risk factors are not firmly established, although some, like poverty and hygiene have been widely suggested [19,20]. We found a clear relationship between a lower socioeconomic status when compared to middle and higher income communities. Also, in the region where we conducted this study, Mayan population was apparently greater in the rural community of Chemax compared to the city of Merida, where the middle and higher income were studied.

Further studies must be undertaken in order to establish the factors involved in the presence of HPV without clinical manifestation of the disease. In our study, many of the children in the lower income school with HPV-13 did not present the characteristic FEH lesions. This could hint further evidence presented by other studies such as the members of six generations of a Venezuelan family, all generations being from the same village [21] and the association of HLA-DR4 alleles (DRB10404) to HPV infection [22] as genetics being a greater factor at play, since the three greater risk factors (HPV-13 presence, Native American background and lower socioeconomic status) were met in all of the subject HPV-13 positive, without showing FEH lesions.

Both FEH clinically compatible lesions and HPV-13 presence in oral mucosa are more prevalent in the LI-elementary school. HPV has been previously isolated in saliva [9] of patients with FEH and even though all three schools are at risk of saliva transmission, the prevalence of HPV-13 positive samples were inversely proportional to the income level of the elementary schools, with a higher prevalence in the LI elementary.

All schools however, had a higher prevalence of HPV-13 positive samples than the clinically compatible lesions present within each school population. This may indicate that risk factors are important in determining the clinical presentation of this disease. Also, clinical manifestation of the disease tends to be more common in the LI elementary than in the HI elementary. Socioeconomic status, Mayan heritage and HPV-13 may be the most important risk factors for this disease, as previous studies have reported that risk factors such as toothbrush and spoon sharing, even relatives with the disease do not play a role as determining risk factors for the presentation of this disease [5].

Our conclusions are in line with our original hypothesis. We found that both FEH lesions and HPV-13 prevalence were inversely proportional to socioeconomic status. We also found a lack of association to a particular gender, and found no difference in the age groups studied. However, the age group of 6-14 years was chosen because of previously reported age groups with the highest prevalence of FEH. The major difference in this study in comparison to previous is that we used a very large population within an endemic area and thoroughly searched for HPV-13 in patients without FEH lesions and found that many of the children analyzed presented HPV-13 but did not show FEH compatible lesions, which hints at unknown factors at play in determining the clinical manifestation of FEH lesions, however, dental staff and healthcare professionals should be aware of the current

risk factors that may be involved in the disease to facilitate early diagnosis of the disease.

References

1. Archard HO, Heck JW, Stanley HR (1965) Focal epithelial hyperplasia: An unusual oral mucosal lesion found in Indian children. *Am Acad Oral Pathol* 20: 201-212.
2. Beaudenon S, Praetorius F, Kremsdorf D, Lutzner M, Worsaae N, et al. (1987) A new type of human papillomavirus associated with oral focal epithelial hyperplasia. *J Invest Dermatol* 88: 130-135.
3. Bennett KL, Hinshaw M (2009) Heck's disease: Diagnosis and susceptibility. *Pediatr Dermatol* 26: 87-89.
4. Cohen PR, Hebert AA, Adler-Storh K (1993) Focal epithelial hyperplasia: Heck's disease. *Pediatr Dermatol* 10: 245-251.
5. Cuberos V, Perez J, Lopez CJ, Castro F (2006) Molecular and serological evidence of the epidemiological association of HPV 13 with focal epithelial hyperplasia: A case-control study. *J of Clin Virol* 37: 21-26.
6. Garlick JA, Calderón S, Buchner A, Mitrani-Rosenbaum S (1989) Detection of human papillomavirus (HPV) DNA in focal epithelial hyperplasia. *J Oral Pathol Med* 18: 172-177.
7. González LV, Gaviria AM, Sanclemente G, Rady P, Tying SK, et al. (2005) Clinical, histopathological and virological findings in patients with focal epithelial hyperplasia from Colombia. *Int J Dermatol* 44: 274-279.
8. Leon L, Cubilla E, Guzman A, Mendoza G, Celias L, et al. (2012) Hyperplasia epithelial multifocal. *Reportes de dos casos relacionados con VPH-13. Dermatologia Cosmetica, Médica y Quirúrgica* 10: 4.
9. González-Losa MR, Suarez-Allén RE, Canul-Canche J, Conde-Ferráz L, Eljure-Lopez N (2011) Multifocal epithelial hyperplasia in a community in the Mayan area of Mexico. *Int J Dermatol* 50: 304-309.
10. Hashemipour MA, Shoryabi A, Adhami S, Mehrabzadeh Honarmand H (2010) Extensive focal epithelial hyperplasia. *Arch Iran Med* 13: 48-52.
11. Kallarakkal TG, Ramathan A, Rosna BZ (2013) Verrucous papillary lesions: Dilemmas in diagnosis and terminology. *Int J Dentistry* 2013: 1-6.
12. Lama-Gonzalez E, Conde-Ferraz L, Puerto-Solis M, Gonzalez-Losa MR (2012) Detección del papillomavirus 13 en pacientes con hiperplasia epitelial multifocal y sus familiares asintomáticos. *Rev Odontol* 4: 29-32.
13. Ledesma-Montes C, Vega-Memije E, Garcés-Ortiz M, Cardiel-Nieves M, Juárez-Luna C (2005) Multifocal epithelial hyperplasia. Report of nine cases. *Med Oral Patol Oral Cir Bucal* 10: 394-401.
14. Liu N, Wang J, Lei L, Li Y, Zhou M (2013) Human papilloma virus-32-associated focal epithelial hyperplasia accompanying hpv-16-positive-papilloma-like lesions in oral mucosa. *J Craneofac Surg* 24: 905-908.
15. Ozden B, Gunduz K, Gunhan O, Ozden FO (2011) A case report of focal epithelial hyperplasia (Heck's disease) with PCR detection of human papillomavirus. *J Maxillo Oral Surg* 10: 357-360.
16. Prabhu SR, Wilson DF (2013) Human papillomavirus an oral disease-emerging evidence: a review. *Aust Dent J* 58: 2-10.
17. Premoli-De-Percoco G, Cisternas JP, Ramírez JL, Galindo I (1993) Focal epithelial hyperplasia: Human-papillomavirus-induced disease with a genetic predisposition in a Venezuelan family. *Hum Genet* 91: 386-388.
18. Cordoba L, Jiménez C (2006) Hiperplasia epitelial multifocal, reporte familiar. Revisión de la literatura. *Rev Latinoam Ortodonc Odontopediatr* 2006.
19. Ledesma-Montes C, Garcés-Ortiz M, HernándezGuerrero JC (2007) Clinicopathological and immunocytochemical study of multifocal epithelial hyperplasia. *J Oral Maxillofac Surg* 65: 2211-2217.
20. Carlos R and Sedano HO (1994) Multifocal papilloma virus epithelial hyperplasia. *Oral Surg Oral Med Oral Pathol* 77: 631-635.
21. Premoli-De-Percoco G, Cisternas JP, Ramirez JL, Galindo I (1993) Focal epithelial hyperplasia: human-papillomavirus-induced disease with a genetic predisposition in a Venezuelan family. *Hum Genet* 91: 386-388.
22. García-Corona C, Vega-Memije E, Mosqueda-Taylor A, Yamamoto-Furusho JK, Rodríguez-Carreón AA, et al. (2004) Association of HLA-

Citation: Zavala-Garcia A, Briceño-Mena R, Romero-Beltran L, Kelly GAF, Ceron-Espinosa J, et al. (2017) Focal Epithelial Hyperplasia Prevalence in an Endemic Population, Molecular Association of HPV-13 to Asymptomatic Patients and Comparison Between Three Elementary Schools of Different Income Levels. *J Immuno Biol* 2: 133. doi:[10.4172/2476-1966.1000133](https://doi.org/10.4172/2476-1966.1000133)

DR4 (DRB1*0404) with human papillomavirus infection in patients with focal epithelial hyperplasia. *Arch Dermatol* 140: 1227-1231.