

Fluoroscopy-Guided Axillary Vein Puncture, a Reliable Method to Prevent Acute Complications Associated With Pacemaker, Defibrillator, and Cardiac Resynchronization Therapy Leads Insertion

E.M. Malitha S. Hettiarachchi, Camelia Arsene*, Salah Fares, Adriss Faraj, Erik Saulitis, Salvatory Losito and Mukarram Siddiqui
Department of Medicine, Sinai-Grace Hospital / Detroit Medical Center, MI, USA

Abstract

Introduction: The subclavian venous approach is a widely used method for venous access in device implantation and is associated with pneumothorax as a short term complication and lead fracture as a long term complication. The axillary vein approach is an alternate method for venous access, and this study evaluates the successfulness and immediate complications of fluoroscopy-guided axillary vein puncture compared to other venous approach methods.

Methods: This is a retrospective observational study on all patients who underwent pacemaker, defibrillator implant or lead change over 23 months. The fluoroscopy-guided modified Seldinger technique was used for axillary vein puncture and if failed, venography was performed.

Results: Out of 261 device implants or lead changes, 210 patients underwent fluoroscopy-guided axillary vein puncture. The mean age of the patients was 65.43 ± 15.7 years; 96.1% were African American; 57.6% were males. In 194 (92.3%) patients left or right axillary vein approaches were successful by either fluoroscopy or venography guidance. When anatomical abnormalities were excluded the success rate for axillary vein puncture was 97% and for fluoroscopy-guided axillary vein puncture was 94.5%. Multiple leads were placed without any resistance and none of the patients had pneumothorax, hemothorax or hematoma as immediate complications.

Conclusion: Based on this first study conducted in a relatively large consecutive United States patient population, we report that fluoroscopy-guided axillary vein puncture using the first rib as a landmark, is a safe and effective method for device implantation with single or multiple leads, without patients getting exposed to intravenous contrasts.

Keywords: Fluoroscopy guided; Axillary vein; Pacemaker; Defibrillator implant; Immediate complications

Introduction

Infraclavicular subclavian approach, cephalic vein cut down, and axillary vein puncture are accepted methods for implanting endocardial pacemaker and transvenous defibrillator leads. Even though the subclavian approach is a widely used method for lead placement in cardiac pacing, different acute complications like for example a 1-3% incidence of pneumothorax or hemothorax have been noted [1-4]. Furthermore, lead fracture due to the entrapment of the lead by the costoclavicular ligament and/or the subclavius muscle, has been presented as subclavian crush and is a major concern [5,6]. As an alternative method, cephalic cut down has been shown to be associated with a lower incidence of lead fracture but the cephalic venous approach requires skills in surgical cut-down technique and the vessel's smaller diameter makes insertion of multiple large diameter leads more technically demanding [7]. As a solution to problems associated with cephalic vein cut down, the axillary vein puncture has been tried. Experience with axillary vein approach is mainly clinical and limited, and immediate and long term complications over other methods are not well established in observational studies [8,9].

We present our single center experience in fluoroscopy-guided axillary vein puncture using the modified Seldinger technique. This study was approved by the Institutional Review Board.

Methods

Study methods

This is a retrospective observational study done on all patients who underwent a pacemaker, a defibrillator device implant or lead change

for a period of 23 months in our institution. Patient information was gathered by chart review, specifically from operative/procedure notes.

Axillary vein cannulation

Clinical anatomy: The axillary vein is a large vein that is a continuation of the basilic vein (Figure 1). It starts at the lower border of the teres major tendon and terminates immediately beneath the clavicle at the outer border of the first rib, where it becomes the subclavian vein. It is anterior and medial to the axillary artery and brachial plexus and partially overlaps. At the level of the coracoid process, the axillary vein receives the lateral cephalic vein [10].

Procedure: We access the axillary vein under fluoroscopy. An incision is made just medial to the coracoid process in the middle of the deltopectoral groove and carried inferomedially in a direction perpendicular to the deltopectoral groove. The incision is carried down to the surface of the pectoralis major muscle. The image intensifier is

*Corresponding author: Camelia Arsene, Department of Medicine, Sinai-Grace Hospital/Detroit Medical Center, 6071 West Outer Drive, Detroit Medical Center, MI 48235, USA, Tel: 313-966-9014; Fax: 313-966-1738, E-mail: carsene@dmc.org

Received November 28, 2013; Accepted December 30, 2013; Published January 06, 2014

Citation: Hettiarachchi EMMS, Arsene C, Fares S, Faraj A, Saulitis E, et al. (2014) Fluoroscopy-Guided Axillary Vein Puncture, a Reliable Method to Prevent Acute Complications Associated With Pacemaker, Defibrillator, and Cardiac Resynchronization Therapy Leads Insertion. J Cardiovasc Dis Diagn 2: 136. doi:10.4172/2329-9517.1000136

Copyright: © 2014 Hettiarachchi EMMS, et al. This is an open-access article distributed under the terms of the Creative Commons Attribution License, which permits unrestricted use, distribution, and reproduction in any medium, provided the original author and source are credited.

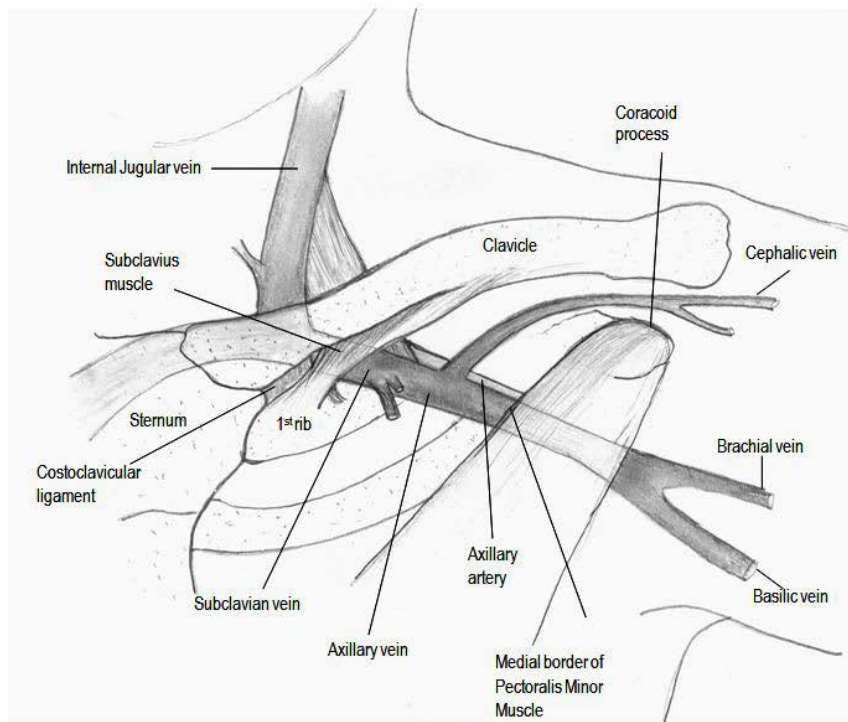


Figure 1: Anatomy of the axillary vein and superficial landmarks.

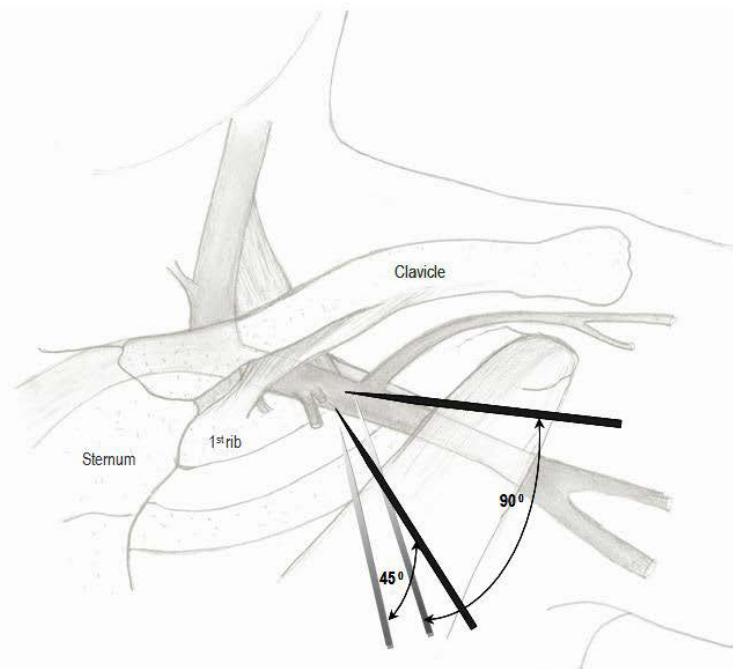


Figure 2: The angle of the needle in relationship to the first rib. Needle should be angled to 60 to 90 degrees as shallow angle runs the risk of entering the intercostal space, causing pneumothorax.

pulled over to the incision and the first rib is identified. An 18 gauge percutaneous needle and syringe is placed on pectoralis major muscle in the superior aspect of the incision. Using fluoroscopy the needle tip is placed in the middle of the first rib (Figure 2 and 3). The angle of the needle and syringe is advanced from 60° to 90° as needle is advanced

through the pectoral muscle. Needle advancement is continued until the first rib is struck. Once the first rib is touched, the needle and syringe are slowly withdrawn under suction until the vein is entered. If the first pass is unsuccessful the needle and syringe are moved either medially or laterally along the first rib, and the maneuver repeated until

Venous puncture site	Number of patients
Total left axillary attempted	210
Left axillary successful	190
Left axillary failed then, right axillary	20
subclavian	4
Cephalic cut down	9
Primarily other site	7
common femoral	51
subclavian-- left	1
subclavian --right	17
cephalic cut down	4
Total device/lead change	29
	261

Table 1: Type of venous access obtained for device implant or lead change during the study period.

Procedure/ Fluoroscopy time (seconds)	Mean	Median	Standard deviation	Minimum	Maximum
1-single chamber pacemaker	8.0	8.7	3.0	4.3	10.8
2-dual chamber pacemaker	6.2	5.8	3.1	1.1	15.9
3-single chamber ICD	6.7	4.6	7.4	0.8	35.1
4-dual chamber ICD	9.1	8.1	6.1	2.2	32.0
5-bivent CRTD	18.4	15.6	11.7	4.4	58.9
6-lead replace	9.4	6.9	7.2	2.1	30.0

Table 2: Fluoroscopy time for different procedures.

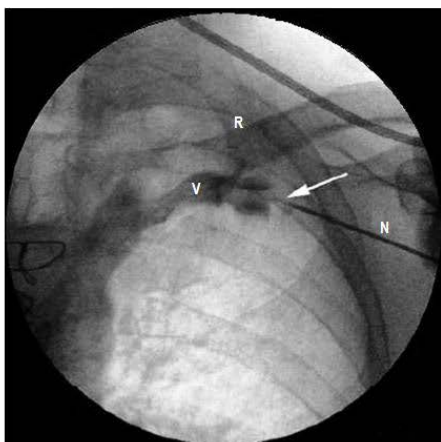


Figure 3: Fluoroscopic view of the axillary vein approach R-first rib, N-needle, V-axillary vein draining into subclavian vein.

the vein is entered. Once the vein is entered the guide wire is passed and the sheath applied per standard technique [10,11].

Multiple accesses are obtained if the patient requires dual chamber permanent pace maker/ defibrillator or biventricular implantable cardioverter defibrillator.

The method to fix the lead at the venous access site is the one described by Peter Belott [12].

Results

Two hundred and sixty-one patients underwent device implant or lead change during the study period (Table 1). In 210 patients fluoroscopy-guided left axillary vein approach was performed, and in 51 patients the subclavian or cephalic access was utilized.

The median fluoroscopy time was 6.8 seconds with a range of 0.1

to 58.9 seconds. Table 2 presents the fluoroscopy time data for different procedures.

The mean age of the patients who underwent axillary vein approach was 65.43 ± 15.78 years. The majority of them, 96.1%, were African American and 57.6% were males.

Out of 210 patients who had axillary vein approach attempted, in 194 patients (92.3%) left or right axillary vein approaches were successful by either fluoroscopic or venography guidance (Table 1 and Figure 4). In 16 (7.6%) patients axillary vein puncture was not successful and alternative sites were required.

The identified reasons for unsuccessful cannulation were anatomical variations/ abnormalities including persistence of left superior vena cava (then venous access was obtained in right axillary vein), venous obstruction, tortuosity of the axillary vein, and clavicular and rib abnormalities. Venous stenosis was also seen in two patients: a hemodialysis patient and an intravenous drug user. After the anatomical abnormalities were excluded, the success rate for axillary vein puncture (either fluoroscopy or venography guidance) was 97% and the success rate for fluoroscopy-guided axillary vein puncture was 94.5 % (Table 3).

Once the venous access was obtained, pacemaker leads or defibrillator leads were successfully placed via the axillary vein regardless of the number of leads, ranging from 1 to 3. Difficulty in placing introducer sheath or lead was not seen in any patients. The characteristics of the devices and the number of leads successfully placed are shown in Table 4. A total of 325 successful axillary vein punctures were performed. Lead removal and replacement were also done successfully in patients who had a preexisting device.

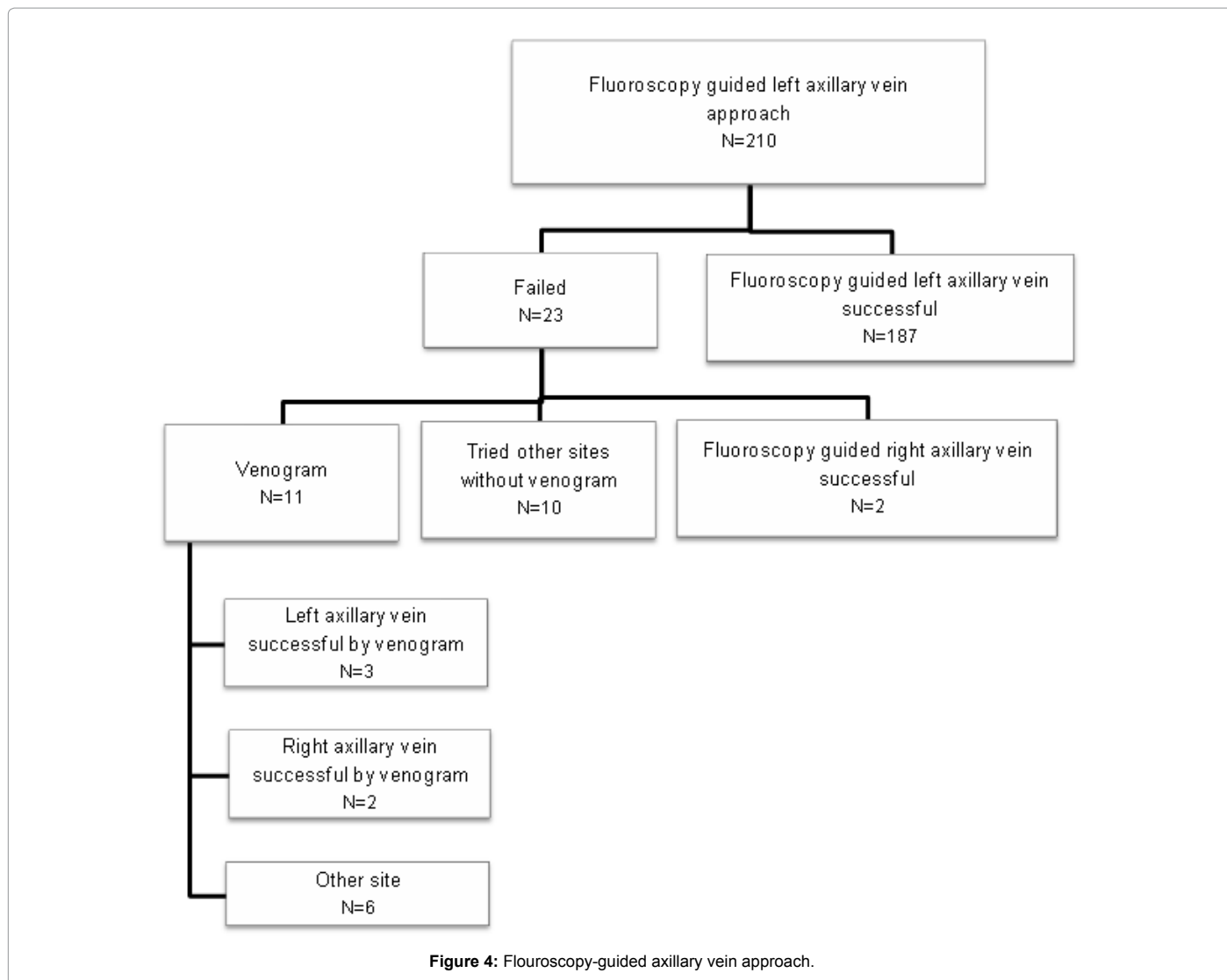The patients were watched for immediate complications clinically and radiographically: postero-anterior and lateral chests X-ray were performed and none of the patients had pneumothorax or hemothorax as immediate complications.

Discussion

Other operators have published different techniques to mark the position of the axillary vein, and for example the anterior side of the second rib was used as the guiding site for puncture site and direction (9). Our study used the first rib as landmark, not the second rib, and therefore this method prevented excessive bleeding at the puncture site and allowed for better and easier lead fixation. Although this could be considered as a technique sometimes used in the clinical practice, we have done a thorough literature review, and we found only one retrospective chart review published study conducted in a smaller patient population in Israel, that used the most lateral edge of the first rib as a fluoroscopic landmark [13].

Venous access is one of the most important steps in device implantation and the subclavian approach is a widely used method. The subclavian vein access is associated with short and long term complications: 1-3% of the incidence of pneumothorax or hemothorax as acute complications and subclavian crush phenomenon leading to lead fracture as a long term complication [5,6]. As shown in our study, axillary vein puncture is not associated with immediate complications [2-4].

Out of the small number of published data on axillary vein puncture most are non United States smaller scale studies that compare various methods, namely, the contrast venography-guided, the Doppler-guided, and the ultrasound-guided puncture methods except for a few studies done in Israel, Japan and India with fluoroscopy-guided



Success rate	Patients	
	Number	Percentage
Axillary vein puncture successful (by fluoroscopy or venogram)	194/210	92.3%
Axillary vein puncture not successful	16/210	7.6%
Failures due to anatomical variations	10/16	
Axillary vein puncture successful - after excluding anatomical variations	194/200	97%
Axillary vein puncture successful with fluoroscopy	189/210	90%
Axillary vein puncture successful with fluoroscopy - after excluding anatomical variations	189/200	94.5 %

Table 3: Success rate of right or left axillary vein puncture.

approach [9,11,13-15]. This study is a North-American experience with fluoroscopy-guided axillary vein puncture using the first rib as a landmark; it is done in a relatively large African-American population, and discusses the immediate complications of the procedure.

Our study shows that fluoroscopy-guided axillary vein puncture is a safe method with limited immediate complications. There was an overall 97% success in axillary vein puncture (either fluoroscopy-guided or venography-guided) after excluding failures due to anatomical abnormalities. Fluoroscopy-guided axillary vein puncture alone also had a success rate of 94.5 % after excluding failures due to anatomical abnormalities.

The main advantages of fluoroscopy-guided approach are that patients are not exposed to the hazards of intravenous contrasts as in venography-guided approach, and the reduced incidence of pneumothorax or hemothorax. While some literature mentions the difficulty in measuring the depth of the vessel with fluoroscopy guidance we did not recognize it as a major barrier [14]. Most importantly, multiple access could be obtained for multiple leads to be inserted without any failure. We did not experience any immediate complications such as pneumothorax or hemothorax, and this could be correlated with the advanced experience of the principal investigator. According to the published literature, leads placed with axillary vein

Device type	Patients		Number of punctures at axillary vein
	Number	Percentage	
1-single chamber pacemaker	10	5.3%	10
2-dual chamber pacemaker	42	22.2%	84
3-single chamber ICD	48	25.4%	48
4-dual chamber ICD	22	11.6%	44
5-bivent CRTD	36	19%	108
6- ICD upgrade to biventric CRTD	12	6.3%	12
7-lead replace	19	10%	19
Total	189		325
Number of leads inserted			
1	74	39.2%	
2	67	35.4%	
3	48	25.4%	
Pre-exciting leads			
present	32	16.9%	
absent	157	83.1%	

Table 4: Characteristics of the devices /leads placed successfully with fluoroscopy-guided left or right axillary vein approach.

approach have minimum risk for lead fracture [16]. To identify the long term complications including lead fracture, we will be following these patients for 12 to 24 months prospectively.

The main limitations of this study are the fact that this is a retrospective observational study, and also there is no direct comparison between fluoroscopy-guided axillary vein puncture and the traditional methods of vascular access, like venography-guided axillary vein puncture, cephalic vein cut down or subclavian vein puncture.

Conclusion

We report that fluoroscopy-guided axillary vein puncture using the modified Seldinger technique is a safe and effective method for the implantation of pacemaker or defibrillator device with single or multiple leads, and it has limited immediate complications.

References

- Byrd CL (1992) Safe introducer technique for pacemaker lead implantation. *Pacing Clin Electrophysiol* 15: 262-267.

- Aggarwal RK, Connelly DT, Ray SG, Ball J, Charles RG (1995) Early complications of permanent pacemaker implantation: no difference between dual and single chamber systems. *Br Heart J* 73: 571-575.
- Chauhan A, Grace AA, Newell SA, Stone DL, Shapiro LM, et al. (1994) Early complications after dual chamber versus single chamber pacemaker implantation. *Pacing Clin Electrophysiol* 17: 2012-2015.
- Parsonnet V, Bernstein AD, Lindsay B (1989) Pacemaker-implantation complication rates: an analysis of some contributing factors. *J Am Coll Cardiol* 13: 917-921.
- Magney JE, Flynn DM, Parsons JA, Staplin DH, Chin-Purcell MV, et al. (1993) Anatomical mechanisms explaining damage to pacemaker leads, defibrillator leads, and failure of central venous catheters adjacent to the sternoclavicular joint. *Pacing Clin Electrophysiol* 16: 445-457.
- Roelke M, O'Nunain SS, Osswald S, Garan H, Harthorne JW, et al. (1995) Subclavian crush syndrome complicating transvenous cardioverter defibrillator systems. *Pacing Clin Electrophysiol* 18: 973-979.
- Gallik DM, Ben-Zur UM, Gross JN, Furman S (1996) Lead fracture in cephalic versus subclavian approach with transvenous implantable cardioverter defibrillator systems. *Pacing Clin Electrophysiol* 19: 1089-1094.
- Hsu JC, Friday J, Lee BK, Azadani PN, Lee RJ, et al. (2011) Predictors of axillary vein location for vascular access during pacemaker and defibrillator lead implantation. *Pacing Clin Electrophysiol* 34: 1585-1592.
- Sharma G, Senguttuvan NB, Thachil A, Leong D, Naik N, et al. (2012) A comparison of lead placement through the subclavian vein technique with fluoroscopy-guided axillary vein technique for permanent pacemaker insertion. *Can J Cardiol* 28: 542-546.
- Belott P (2006) How to access the axillary vein. *Heart Rhythm* 3: 366-369.
- Nickalls RW (1987) A new percutaneous infraclavicular approach to the axillary vein. *Anaesthesia* 42: 151-154.
- Belott P (2001) Implantation techniques for single- and dual-chamber pacemakers. In Singer I, Eds, *Interventional Electrophysiology* (2nd Edn), Lippincott Williams & Wilkins, USA.
- Antonelli D, Feldman A, Freedberg NA, Turgeman Y (2013) Axillary vein puncture without contrast venography for pacemaker and defibrillator leads implantation. *Pacing Clin Electrophysiol* 36: 1107-1110.
- Kawakami T, Ichinose H (2004) Double target method (double marker-guided extrathoracic introducer insertion). *Pacing Clin Electrophysiol* 27: 818-820.
- Yadav R, Chandra S, Naik N (2006) Modified fluoroscopy-guided axillary vein puncture during pacemaker implantation: acute and mid-term results.
- Ramza BM, Rosenthal L, Hui R, Nsah E, Savader S, et al. (1997) Safety and effectiveness of placement of pacemaker and defibrillator leads in the axillary vein guided by contrast venography. *Am J Cardiol* 80: 892-896.