

## Case Report

## Open Access

# Extraskelatal Ewing Sarcoma in a Young Patient During Pregnancy

Friederika Fluck\*, L Menezes Falcão, Raquel Paixão and Isabel Pinheiro

Department of Internal Medicine, University Hospital of Lisbon, Santa Maria, Lisbon, Portugal

### Abstract

**Background:** Ewing's sarcoma is usually identified as a primary malignancy of the bone affecting children and young adults. It is associated with soft tissue extension in 90% of cases. Primarily extraskelatal Ewing's sarcoma is a rare subtype, and very few data are available concerning optimal treatment modalities.

**Case Presentation:** We report a case of an 18 year-old female from Cabo Verde in her 34th week of pregnancy presenting with a rapid growing cervical tumor. It had initially started as an indolent swelling at the left cervico-postero-lateral region. CT had shown involvement of both superficial and deep cervical fascia. At time of presentation, the histologic diagnosis of a peripheral Primitive Neuroectodermal Tumor/Extraskelatal Ewing's sarcoma had already been provided. To reduce risk of fetal metastasis, the child was delivered by caesarean section. A chest CT of the patient revealed pulmonary metastasis and compressive atelectasis of the left lung caused by the tumor. Three weeks post partum, she presented with loss of muscular function of the extremities as well as paresthesia and bladder dysfunction. A repeat CT confirmed medullar compression at the level of C5-C6, C6-C7 and C7-D1 by the tumor without signs of bone metastasis. 5 sessions of palliative radiotherapy were performed that led to parcial recovery of muscular function of the upper right extremity. Palliative chemotherapy was refused, so that the patient was released from hospital. No metastasis had been detected in the child so far.

**Conclusion:** Extraskelatal Ewing's sarcoma can manifest as a rapidly growing localized mass causing local compression symptoms. Palliative radiotherapy can achieve local tumorreduction and symptom relief.

## Introduction

Ewing's sarcoma (ES) of the bone is part of the Ewing sarcoma family of tumors (ESFTs), such as the Askin tumors of the chest wall, Primitive Neuroectodermal Tumors (PNET) of bone or soft tissues and Extraskelatal Ewing Sarcoma (EES)/peripheral Primitive Neuroectodermal Tumor (pPNET) [1].

ES is usually identified as a primary malignancy of the bone affecting children and young adults, constituting the second most frequent sarcoma of bone in these age groups [2]. It is associated with soft tissue extension in 90% of cases.

Primarily extraskelatal Ewing's sarcoma is a rare subtype, and was first described by Tefft et al. (1969), reporting four patients with paravertebral soft tissue tumors that histologically resembled ES [3]. Since then several cases of EES have been described. It occurs more frequently in the age range between age 20 and 30 and can develop in almost any soft tissue of the body [1,4]. The tumor usually evolves with a high incidence of local recurrence and distal metastasis.

Few data are available concerning optimal treatment modalities for EES. Some authors report that multimodal therapy used in patients with ES seems to be adequate for those with EES [5,6].

So far, only few cases of EES during pregnancy have been reported.

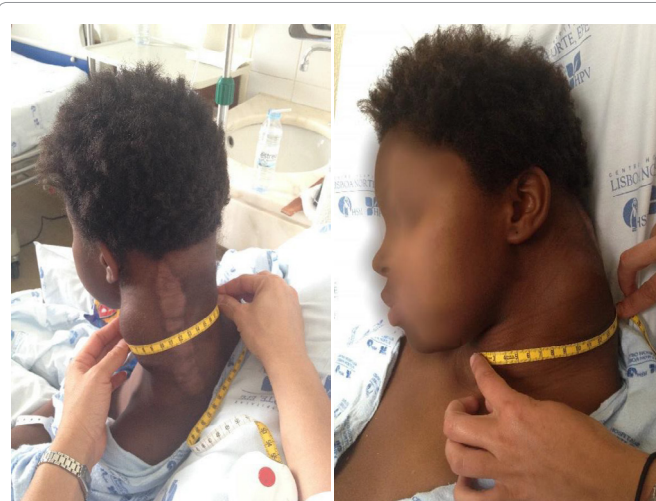## Case Presentation

We report a case of an 18 year-old female from Cabo Verde in her 34th week of pregnancy presenting with a rapid growing cervical tumor.

### Presentation

The tumor started as an indolent swelling on the left cervico-postero-lateral region (Figures 1 and 2). Surgical excision of the mass was done in her home country. It is unknown if histopathological examination has been performed.

The cervical tumor continued growing alarmingly fast, causing the patient to seek help in the neighbor country Senegal, where the tumor was excised again and histopathological and immunohistochemical examination was performed.



Figures 1 and 2: Indolent swelling at the left cervico-postero-lateral region.

## Histological examination

Histopathological examination revealed massive infiltration of connective and adipose tissue as well as infiltration of the striated muscle by an undifferentiated, round cell tumor. High cellular density was observed.

**\*Corresponding author:** Friederika Fluck, Department of Internal Medicine, University Hospital of Lisbon, Santa Maria, Lisbon, Portugal, Tel: 00351 919458259; E-mail: [friederika.fluck@gmail.com](mailto:friederika.fluck@gmail.com)

**Received** November 24, 2014; **Accepted** January 24, 2015; **Published** January 26, 2015

**Citation:** Fluck F, Falcão LM, Paixão R, Pinheiro I (2015) Extraskelatal Ewing Sarcoma in a Young Patient During Pregnancy. J Clin Case Rep 5: 485. doi:10.4172/2165-7920.1000485

**Copyright:** © 2015 Fluck F, et al. This is an open-access article distributed under the terms of the Creative Commons Attribution License, which permits unrestricted use, distribution, and reproduction in any medium, provided the original author and source are credited.

Cells appeared small and round with indistinct and fine granular cytoplasm. The nuclei were round to oval with indistinct cytoplasmic border and finely dotted chromatin, the nucleoli were rarely visible. Focal necrosis was detected with important hemorrhagic rearrangements.

### Immunohistochemical examination

Immunohistochemical examination showed that tumor cells stained positively for anti-CD99 and anti-vimentine. Some tumor cells stained also positively for anti-CD68 and anti-protein S100. Other markers, such as anti-CD56, anti-CD45, anti-CD20, anti-CD3, anti-desmine, anti-myogenine, anti-Bcl2 and anti-epithelial membrane antigen (EMA) were negative.

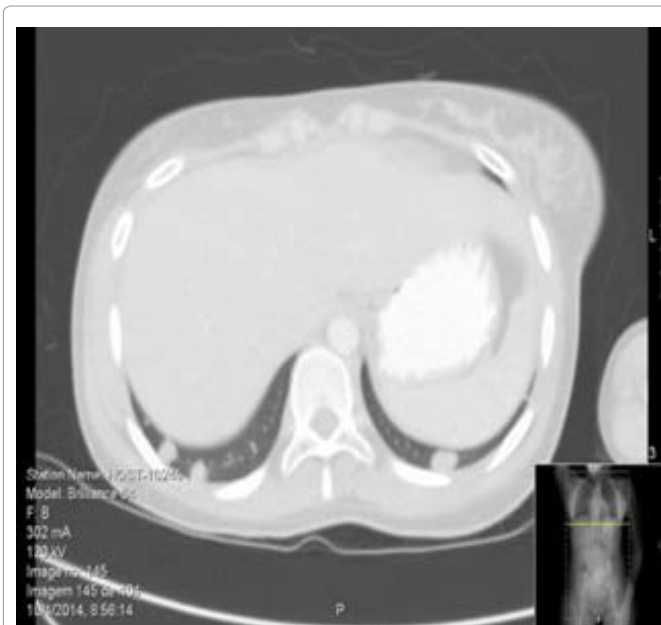
Based on these findings a peripheral Primitive Neuroectodermal Tumor/Extraskelatal Ewing's sarcoma was diagnosed.

### Clinical course

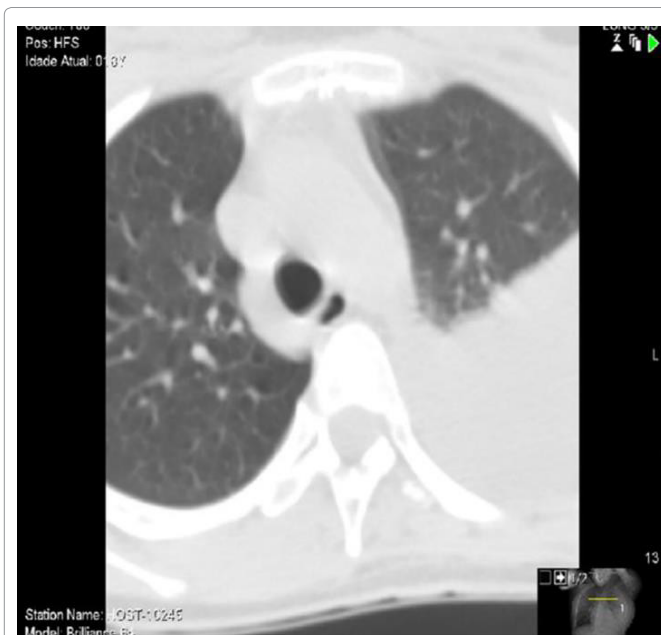
The patient was referred to oncologic treatment. She was in her 25th week of pregnancy and was evacuated to Portugal due to lack of local treatment options.

At Lisbon University Hospital, the child was delivered by cesarean section at her 34th week of pregnancy to reduce fetal metastasis. Computed tomography (CT) scan had shown involvement of both superficial and deep cervical fascia (Figure 3), pulmonary metastasis (Figure 4) and compressive atelectasis of the left lung by the tumor (Figure 5).

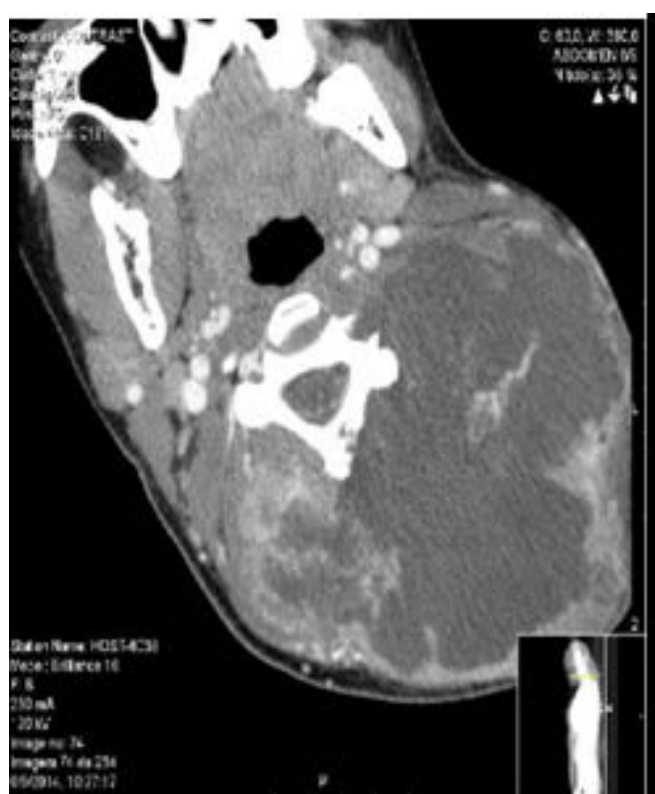Three weeks post-partum, she presented with loss of muscular function of the extremities as well as paresthesia and bladder dysfunction. A repeat CT confirmed medullar compression at the



**Figure 4:** CT scan showing pulmonary metastasis.



**Figure 5:** CT scan showing compressive atelectasis of the left lung caused by the tumor.



**Figure 3:** CT scan showing involvement of both superficial and deep cervical fascia.

level of C5-C6, C6-C7 and C7-D1 by the tumor without signs of bone metastasis.

In order not to impair postoperative wound healing after cesarean surgery, palliative chemotherapy could not be administered immediately. Later on, the patient refused palliative chemotherapy.

Due to aggravation of symptoms, five sessions of palliative radiotherapy were performed with a total dose of 20 Gy. A partial recovery of muscular function of the upper right extremity could be achieved.

The patient was discharged home with her newborn son according to her wishes. No metastasis had been detected in the child so far.

## Discussion

### Ewing family of tumors

Ewing's sarcoma (ES) and Primitive Neuroectodermal Tumor (PNET) are relatively rare and aggressive neoplasms that are both part of Ewing Family of Tumors (ESFTs). Ewing's sarcoma typically is an undifferentiated primary malignancy of the bone, while neoplasms of the spectrum of PNET demonstrate clear evidence of neural differentiation.

Mitotic figures, necrosis, endothelial hyperplasia and Homer-Wright rosettes are in favor of the diagnosis of PNET instead of Ewing's sarcoma [7].

Approximately 95% of patients with ESFT have a characteristic t (11; 22) (q24; q12) or t (21; 22) (q22; q12) chromosomal translocation identified by reverse transcription polymerase chain reaction (RT-PCR) [8,9]. The differential diagnosis includes central PNET, malign meningioma, rhabdomyosarcoma, neuroblastoma and lymphoma. ES predominantly involves the major bones, pelvis and ribs and is associated with soft tissue extension in 90% of cases.

### Extraskkeletal Ewing's sarcoma

Another member of ESFTs is the extraskkeletal Ewing's sarcoma (EES)/peripheral PNET, an uncommon neoplasm of uncharacterized mesenchymal cell origin that occurs most commonly in paravertebral and intercostal regions, such as chest wall, lower extremities and the retroperitoneum in 15% of the cases [10].

Histology typically shows small, round cells with round nucleoli, fine chromatin, scant cytoplasm, indistinct cell borders and necrosis [11]. It can easily be confused with other small round-cell tumors [12].

### Immunochemical characteristics

Most of the tumors within the Ewing's sarcoma family express surface antigens like CD99, 12E7, E2, 013 and HBA71, which are all products of the MIC2 gene. At first it was assumed to be highly specific and antibody staining for CD99 was used to confirm the diagnosis [12,13]. More recent findings show that, although its sensitivity ranges from 84% to 100% in ES/PNET, the specificity seems to be limited [11,14].

Tumor cells may also be positive for vimentin, friend leukemia integration 1 transcription facto (FLI). Reactivity for neuron-specific enolase (NSE), S-100, CD57, synaptophysin, cytokeratin and neurofilament, indicating neuroectodermal differentiation, may support the diagnosis of pPNET [7,10,14].

In our case the diagnosis was based on histopathological examination and imunohistochemical positivity of anti-CD99, anti-vimentin and anti-protein S-100.

## Clinical manifestation

EES/pPNET manifesting as a primary cervical tumor is uncommon [12,15,16]. According to Chao et al. (2000), there were only five out of 118 cases of extraskkeletal Ewing's sarcoma located in the head and neck region [17]. Nearly half of patients have metastatic disease [6,18-21]. EES/pPNET frequently invade adjacent organs and metastasize to the lung [15], as well as to the bone and lymph nodes [22].

In the present case involvement of both superficial and deep cervical fascia with tracheal deviation had occurred, accompanied by lymph node and pulmonary metastasis and compressive atelectasis of the left lung caused by the tumor.

### Pregnancy

There is a low incidence of cancer during pregnancy, with approximately 1 diagnosis in 1000 pregnant women [23]. The incidence of EES and ESFTs during pregnancy is extremely low and only a few cases have been reported so far.

In a recent review of the literature Verheeecke et al. reported a total of 12 cases with primary ES diagnosed during pregnancy including 3 cases of EES [23].

Overall most of these cases received chemotherapy, radiotherapy and/or surgery during and after pregnancy. The majority of cases included delivery by cesarean section and an overall good outcome for both mother and child could be observed [24-33].

The reported cases of EES during pregnancy manifested as retroperitoneal abdominal mass, as solid mass in the left thigh and in duodenum. A vaginal delivery, cesarean section and termination of pregnancy were described. Radiotherapy, surgery and chemotherapy after pregnancy and chemotherapy during and after pregnancy were the treatment modalities [34-36].

None of the described cases presented metastasis at diagnosis, there is no information about the risk of fetal metastasis so far (Table 1).

Vaginal delivery could not be offered to our patient because of the rapid progression of tumor size and the presence of multiple metastasis. Due to lack of information about the risk of fetal metastasis in cases of EES during pregnancy and because of the aggressiveness of the tumor with high incidence of local recurrence and distant metastasis, we decided to deliver the child by cesarean section in the 34th week of pregnancy.

No metastasis was clinically evident in the newborn until returning to Cabo Verde in his 6th week of life. Continuous monitoring of the child should be performed in order to early EES metastasis detection. No recommendations about follow-up time in this specific situation have been described yet.

Author and year	Tumor localization	Treatment	Outcome mother	Outcome infant
Blight and Puls (1981)	Retroperitoneal abdominal mass	Radiotherapy, surgery and chemotherapy (vincristine, cyclophosphamide, doxorubicin) after pregnancy	Died 8 months after treatment	Vaginal delivery, newborn without metastasis
Gennatas et al. (1987)	Left thigh	Chemotherapy (cyclophosphamide, vincristine, adriamycine, DTIC, actinomycin-D) during and after pregnancy	Complete remission	Cesarean section, newborn without metastasis
Adair et al. (2001)	Duodenum	Surgery and chemotherapy after pregnancy	No evidence of disease 10 months after treatment	Termination of pregnancy

Table 1: Overview of studies of EES during pregnancy.



During pregnancy no chemotherapy was administered due to the palliative situation of the patient, in order to avoid toxicity for the unborn. The tumor was unresectable, with invasion of adjacent structures and distant metastasis. We could not offer immediate postoperative chemotherapy which led to a faster deterioration of clinical situation with medullar compression symptoms, and only partial recovery with palliative radiotherapy. This situation may have discouraged the patient to accept palliative chemotherapy afterwards.

### Treatment options during pregnancy

Due to the small number of cases with ESFTs during pregnancy, little is known about optimal treatment options in this situation.

Patients with EES seem to benefit from the same combined modality treatment as established for patients with ESFTs [5,6]. Nearly every chemotherapy protocol for Ewing sarcoma has been based on four drugs: doxorubicin, cyclophosphamide, vincristine and dactinomycin, alternating with ifosfamide and etoposide [37]. Radiation for local control is recommended for unresectable tumors and when it is unlikely that adequate surgical margins can be achieved [22].

### Predictors

Tumor size (>8 cm), metastasis at presentation, high serum lactate dehydrogenase (LDH), poor histological response to chemotherapy, radiotherapy only as local treatment and positive surgical margin have been described as significant predictors of worse overall survival [6,4,18,20-22,38,39].

Unfortunately our patient met several of these criteria (tumor size>8 cm, metastasis at presentation, high serum LDH and radiotherapy was only administered as palliative local treatment).

Olmos et al. (2011) described that there is a tendency of these tumors to progress more rapidly in pregnancy [40]. Increased levels of oestrogens, progesterone and increased levels of IGF-1 expression on ES during pregnancy has been discussed [23,40].

Even if the patient had accepted palliative chemotherapy it is uncertain if a significant difference in quality of life and survival could have been achieved.

### Conclusion

Extraskelatal Ewing's sarcoma is a malignant tumor that can manifest as a rapidly growing localized mass causing local compression symptoms. It is an undifferentiated small round cell tumor and has a high recurrence rate and frequent distant metastasis.

This is the fourth case of EES described in a pregnant woman. Early delivery can minimize fetal metastasis. The newborn should be followed for early detection of metastasis. The best treatment modality has to be individualized for each case and according to the patient's wishes. Palliative radiotherapy can achieve local tumor reduction and symptom relief. Future studies should focus on treatment strategies for these tumors.

### References

1. Maheshwari AV, Cheng EY (2010) Ewing sarcoma family of tumors. J Am Acad Orthop Surg 18: 94-107.
2. Herzog CE (2005) Overview of sarcomas in the adolescent and young adult population. J Pediatr Hematol Oncol 27: 215-218.
3. Tefft M, Vawter GF, Mitus A (1969) Paravertebral "round cell" tumors in children. Radiology 92: 1501-1509.
4. Raney RB, Asmar L, Newton WA, Bagwell C, Breneman JC, et al. (1997)

Ewing's sarcoma of soft tissues in childhood: a report from the Intergroup Rhabdomyosarcoma Study, 1972 to 1991. J Clin Oncol 15: 574-582.

5. Gururangan S, Marina NM, Luo X, Parham DM, Tzen CY, et al. (1998) Treatment of children with peripheral primitive neuroectodermal tumour or extraosseous Ewing's tumour with Ewing's-directed therapy. J Pediatr Hematol Oncol 20: 55-61.
6. Orr WS, Denbo JW, Billups CA, Wu J, Navid F, et al. (2012) Analysis of prognostic factors in extraosseous Ewing sarcoma family of tumors: review of St. Jude Children's Research Hospital experience. Ann Surg Oncol 19: 3816-3822.
7. Cabral GA, Nunes CF, Melo JO Jr, Guimarães RD, Gonçalves MB, et al. (2012) Peripheral primitive neuroectodermal tumor of the cervical spine. Surg Neurol Int 3: 91.
8. Downing JR, Head DR, Parham DM, Douglass EC, Hulshof MG, et al (1993) Detection of the (11; 22) (q24;q12) translocation of Ewing's sarcoma and peripheral neuroectodermal tumour by reverse transcription polymerase chain reaction. Am J Pathol 143: 1294-1300.
9. Torchia EC, Jaishankar S, Baker SJ (2003) Ewing tumour fusion proteins block the differentiation of pluripotent marrow stromal cells. Cancer Res 63: 3464-3468.
10. Reali A, Mortellaro G, Allis S, Trevisiol E, Anglesio SM, et al. (2013) A case of primary mediastinal Ewing's sarcoma/primitive neuroectodermal tumor presenting with initial compression of superior vena cava. Ann Thorac Med 8: 121-123.
11. Grossniklaus HE, Shehata B, Sorensen P, Bergstrom C, Hubbard GB (2012) Primitive neuroectodermal tumor/Ewing sarcoma of the retina. Arch Pathol Lab Med 136: 829-831.
12. Cho SI, Park YH, Cho JH, Ryoo BY, Yang SH, et al. (2007) Extraskelatal Ewing's sarcoma of the head and neck presenting as blindness. Korean J Intern Med 22: 133-137.
13. Casella R, Moch H, Rochlitz C, Meier V, Seifert B, et al. (2001) Metastatic primitive neuroectodermal tumor of the kidney in adults. Eur Urol 39: 613-617.
14. Tasli F, Ozkök G, Aykas A, Postaci H, Uslu A (2014) An unusual tumor of the breast – extraskelatal ewing sarcoma. Curr Health Sci J 40: 75-77.
15. Somarouthu BS, Shinagare AB, Rosenthal MH, Tirumani H, Hornick JL (2014) Multimodality imaging features, metastatic pattern and clinical outcome in adult extraskelatal Ewing sarcoma: experience in 26 patients. Br J Radiol 87: 20140123.
16. Weinreb I, Goldstein D, Perez-Ordóñez B (2008) Primary extraskelatal Ewing family tumor with complex epithelial differentiation: a unique case arising in the lateral neck presenting with Horner syndrome. Am J Surg Pathol 32: 1742-1748.
17. Chao TK, Chang YL, Sheen TS (2000) Extraskelatal Ewing's sarcoma of the scalp. J Laryngol Otol 114: 73-75.
18. Rud NP, Reiman HM, Pritchard DJ, Frassica FJ, Smithson WA (1989) Extraosseous Ewing's sarcoma: a study of 42 cases. Cancer 64: 1548-1553.
19. Baldini EH, Demetri GD, Fletcher CD, Foran J, Marcus KC, et al. (1999) Adults with Ewing's sarcoma/primitive neuroectodermal tumour: adverse effect of older age and primary extraosseous disease on outcome. Ann Surg 230: 79-86.
20. El Weshi A, Allam A, Ajarim D, Al Dayel F, Pant R, et al. (2010) Extraskelatal Ewing's sarcoma family of tumours in adults: analysis of 57 patients from a single institute. Clin Oncol (R Coll Radiol) 22: 374-381.
21. Tural D, Molinas Mandel N, Dervisoglu S, Dincbas FO, Koca S, et al. (2012) Extraskelatal Ewing's sarcoma family of tumours in adults: prognostic factors and clinical outcome. Jpn J Clin Oncol 42: 420-426.
22. Tao HT, Hu Y, Wang JL, Cheng Y, Zhang X, et al. (2013) Extraskelatal Ewing sarcomas in late adolescence and adults: a study of 37 patients. Asian Pac J Cancer Prev 14: 2967-2971.
23. Verheeecke M, Salembier C, Vanderlinden S (2013) Delayed diagnosis of an Ewing sarcoma of the knee during pregnancy. Facts Views Vis Obgyn 5: 133-138.
24. Lysyj A, Bergquist JR (1963) Pregnancy complicated by sarcoma. Report of two cases. Obstet Gynecol 21: 506-509.
25. Greenberg P, Collins JD, Voet RL, Jarivala L (1982) Ewing's sarcoma metastatic to placenta. Placenta 3: 191-196.

26. Gililand J, Weinstein L (1983) The effects of cancer chemotherapeutic agents on the developing fetus. *Obstet Gynecol Surv* 38: 6-13.
27. Simon MA, Phillips WA, Bonfiglio M (1984) Pregnancy and aggressive or malignant primary bone tumors. *Cancer* 53: 2564-2569.
28. Haerr RW, Pratt AT (1985) Multiagent chemotherapy for sarcoma diagnosed during pregnancy. *Cancer* 56: 1028-1033.
29. Loguidice V, Tehranzadeh J, Jones E (1986) Ewing's sarcoma and pregnancy. A case report and review of the literature. *Clin Orthop Relat Res* : 132-136.
30. Dhillon MS, Singh DP, Gill SS, Sur R, Sarode VR, et al. (1993) Primary bone malignancies in pregnancy. A report of four cases. *Orthop Rev* 22: 931-937.
31. Merimsky O, Le Chevalier T, Missenard G, Lepechoux C, Cojean-Zelek I, et al. (1999) Management of cancer in pregnancy: a case of Ewing's sarcoma of the pelvis in the third trimester. *Ann Oncol* 10: 345-350.
32. Nakajima W, Ishida A, Takahashi M, Masashi H, Noriaki W, et al. (2004) Good outcome for infant of mother treated with chemotherapy for Ewing sarcoma at 25 to 30 weeks' gestation. *J Pediatr Hematol Oncol* 26: 308-311.
33. DuBois SG, Perez-Atayde AR, McLean TW, Grier HE (2008) Late recurrence of ewing sarcoma during pregnancy: a report of 2 cases. *J Pediatr Hematol Oncol* 30: 716-718.
34. Blight EM, Puls JR (1981) Collateral venous flow through uterus caused by retroperitoneal extraosseous Ewing's sarcomas. *Urology* 17: 386-389.
35. Gennatas CS, Carvounis E, Fotopoulos A, Politi HD (1987) Extraskkeletal Ewing's sarcoma in a pregnant woman: a case report. *Eur J Surg Oncol* 13: 163-165.
36. Adair A, Harris SA, Coppen MJ, Hurley PR (2001) Extraskkeletal Ewings sarcoma of the small bowel: case report and literature review. *J R Coll Surg Edinb* 46: 372-374.
37. Grier HE, Krailo MD, Tarbell NJ, Link MP, Fryer CJ, et al. (2003) Addition of ifosfamide and etoposide to standard chemotherapy for Ewing's sarcoma and primitive neuroectodermal tumor of bone. *N Engl J Med* 348: 694-701.
38. Eralp Y, Bavbek S, Basaran M, Esra K, Fulya Y, et al. (2002) Prognostic factors and survival in late adolescent and adult patients with small round cell tumours. *Am J Clin Oncol* 25: 418-424.
39. Applebaum MA, Worch J, Matthay KK, Goldsby R, Neuhaus J, et al. (2011) Clinical features and outcomes in patients with extraskkeletal Ewing sarcoma. *Cancer* 117: 3027-3032.
40. Olmos D, Martins AS, Jones RL, Alam S, Scurr M, et al. (2011) Targeting the Insulin-Like Growth Factor 1 Receptor in Ewing's Sarcoma: Reality and Expectations. *Sarcoma* 2011: 402508.