



EVALUATION OF THE PULMONARY ARTERY PRESSURE DURING PERCUTANEOUS TRANSVENOUS MITRAL COMMISSUROTOMY IN RHEUMATIC MITRAL STENOSIS

Dr. Ananda G.C
Chitwan Medical College, Bharatpur, Chitwan, Nepal

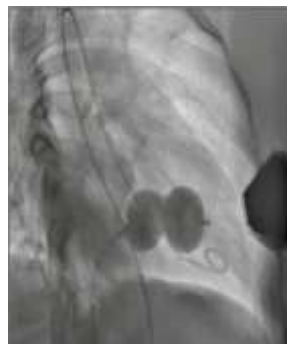

Abstract

Introduction:

Rheumatic heart disease is one of the most common heart diseases in developing country. One of the most common complications of Rheumatic Heart Disease is Mitral Stenosis which ultimately lead to pulmonary hypertension and heart failure and death. So, PTMC (Percutaneous Transluminal Mitral Commissurotomy) is a well-established simple, effective, and safe therapeutic intervention for mitral stenosis.

While many literatures reviewed till date have shown that it takes 3-6 months' time period for the reduction of pulmonary artery pressure after PTMC, this study is designed to see the result in pulmonary artery pressure immediately after procedure.

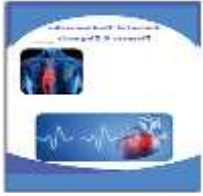

Method

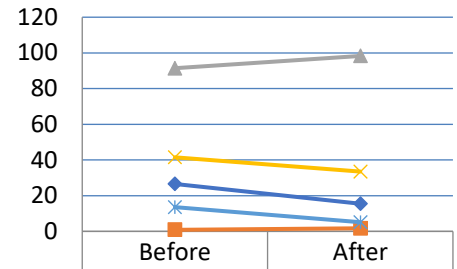
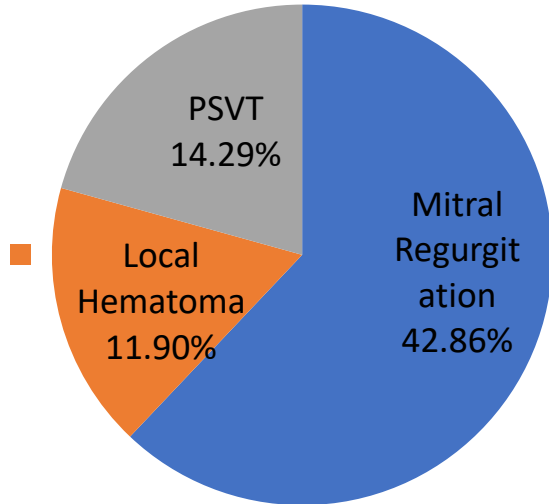
Total 42 patients with Rheumatic Mitral Stenosis in Cath Lab under Department of Cardiology of Chitwan Medical College from October 1 2018 to August 30 2019 were included in the study. Pulmonary artery pressure was assessed by Right heart catheterization by using multipurpose /pigtail catheter under conscious sedation.

Results

It is a prospective observational study on a total of 42 patients who underwent PTMC, 30 were female and 12 were male. Age ranged from 30 to 61 years with the mean age of 45.36 ± 10 years. The mean mitral valve area increased from 0.87 ± 0.2 cm² to 1.74 ± 0.17 cm² whereas Mean Pressure Gradient decreased from 13.59 ± 7.30 mmHg to 5.15 ± 3.0 mmHg. Mean Pulmonary Artery Pressure decreased from 41.50 ± 16.00 mmHg to 33.50 ± 12.00 mmHg. Similarly, the mean left atrial pressure decreased from 26.57 ± 8.62 mmHg to 15.50 ± 5.95 mmHg whereas, the mean Aortic Pressure increased from 91.43 ± 23.02 mmHg to 98.29 ± 24.92 mmHg. Eighteen (42.85%) patients had an increase in MR by 2 grades but there is no need of immediate mitral valve replacement. During procedure, paroxysmal PSVT was noted in six (14.285%) patients and also local hematoma was observed in five (11.90%) patients.



Complications



	Before	After
LA Pressure (in mmHg)	26.57142857	15.5
MVA (in cm ²)	0.871428571	1.742857143
AP (in mmHg)	91.42857143	98.28571429
PAP (in mmHg)	41.5	33.5
MVG Mean (in mmHg)	13.59285714	5.15

Conclusion

There is reduction in pulmonary artery pressure immediately post PTMC which is directly correlated with left atrial pressure without significant MR and tachycardia.

This study is limited in terms of single center with small sample size.



Biography:

Dr. Ananda G.C, Chitwan Medical College, Bharatpur, Chitwan, Nepal

[32nd Annual Cardiologists Conference, August 24-25, 2020.](https://cardiologists.insightconferences.com/abstract/2020/evaluation-of-the-pulmonary-artery-pressure-during-percutaneous-transvenous-mitral-commissurotomy-in-rheumatic-mitral-stenosis)

Abstract Citation:

Dr. Ananda G.C., Evaluation Of The Pulmonary Artery Pressure During Percutaneous Transvenous Mitral Commissurotomy In Rheumatic Mitral Stenosis

32nd Annual Cardiologists Conference, August 24-25, 2020 (<https://cardiologists.insightconferences.com/abstract/2020/evaluation-of-the-pulmonary-artery-pressure-during-percutaneous-transvenous-mitral-commissurotomy-in-rheumatic-mitral-stenosis>)