

Research Article

Open Access

Evaluation of the Management of Severe Trauma Kidney Injury and Long Term Renal Function in Children

Camille Overs*, Youssef Teklali, Bernard Boillot, Delphine Poncet, Pierre-Yves Rabattu, Yohan Robert and Christian Piolet

Pediatric Surgery Unit, Hospital Couple-Enfant, Grenoble Teaching Hospital, France

*Corresponding author: Camille Overs, Pediatric Surgery Unit, Hospital Couple-Enfant, Grenoble Teaching Hospital, France, Tel: +33 476767575; E-mail: covers@chu-grenoble.fr

Rec date: Jul 21, 2016; Acc date: Sep 24, 2016; Pub date: Sep 26, 2016

Copyright: © 2016 Overs C, et al. This is an open-access article distributed under the terms of the Creative Commons Attribution License, which permits unrestricted use, distribution, and reproduction in any medium, provided the original author and source are credited.

Abstract

Objective: To evaluate the management and long term renal function with DMSA scintigraphy in pediatric severe traumatic kidney injury (STKI) grade IV (STKI IV) and V (STKI V) at the trauma center of Grenoble teaching hospital.

Materials and methods: This is a single-center retrospective study between 2004 and 2014. All children under the age of 15 managed at the Grenoble teaching hospital for a STKI IV or V were included. The trauma grade was radiologically diagnosed on arrival at hospital, using the classification of the American association for surgery of trauma. The management followed the algorithm in effect in the establishment. The assessment of the renal function was performed by a DMSA scintigraphy after at least 6 months from the injury.

Results: 21 children were managed at the Grenoble teaching hospital for a severe traumatic kidney injury (16 STKI IV and 5 STKI V). The diagnosis was initially made by an ultrasonography (8 cases) or a CT-scan (13 cases). A child with STKI IV underwent a nephrectomy on day 6 of the trauma. Eleven children needed a therapeutic procedure (3 embolizations, 4 double J stents, 1 arterial stent, 1 peritoneal lavage for a splenic hemoperitoneum, 4 pleural drainages). A DMSA scintigraphy was performed in 15 patients to assess the function of the injured kidney: 11/16 STKI IV with an average of 39.4%, and 17% for the 4/5 STKI V analyzed.

Conclusion: Among the 21 children managed for a STKI IV (16 cases) or STKI V (5 cases), 11 required a therapeutic procedure, one of them a nephrectomy. The DMSA scintigraphy performed after at least 6 months from the trauma, found an injured renal function at 39.4% for the 11/16 STKI IV analyzed, and 17% for the 4/5 STKI V analyzed. There is therefore a significant long term recovery of the renal function in children with STKI (especially STKI IV), confirming the currently conservative management.

Keywords: Severe trauma kidney injury; Scintigraphy; Renal function; Endo urology; Trauma center; abdominal trauma; CT-scan; Splenic hemoperitoneum

Introduction

Pediatric severe traumatic kidney injuries (STKI) are commonly found in abdominal trauma, with a currently conservative management, when possible. The hemostasis nephrectomy in emergency is only performed when there is a hemodynamic instability with active bleeding. Other treatments, such as endoscopic treatments, do not follow any consensus. The Grenoble teaching hospital, by its geographical position, is used to manage many kidney injuries (because of mountain sports, skiing, paragliding). The hospital is part of a Rhonalpin coordination of different hospitals, with a rich technical platform (shock treatment room, pediatric anesthesia, interventional radiology, pediatric surgery, pediatric intensive care unit, and pediatric rehabilitation). This makes Grenoble teaching hospital a real trauma center. The functional prognosis of the injured kidney should be lately analyzed, at least after 6 months from the trauma, and can be performed with a DMSA scintigraphy. The objective of this study was to evaluate the management of STKI IV and V in children following the algorithm of the hospital, and assess the long term renal function with a DMSA scintigraphy.

Materials and Methods

This is a retrospective single-center study, with analysis of the medical records of all children aged less than 15 years-old and managed at the Grenoble teaching Hospital for a STKI IV and V between 2004 and 2014. The management followed the algorithm established in the institution (Figure 1). The grade of severity was diagnosed with a radiologic imaging, performed on arrival at the center (with a CT-scan), using the classification of the American association for surgery of trauma. The characteristics of the patients, the trauma, and the clinical presentation at the initial management and during the hospitalization were analyzed. A radiological reassessment with a CT-scan was systematically performed on day 5. The long term renal function assessment was performed with a DMSA scintigraphy after at least 6 months from the injury.

Results

Out of the 21 STKI managed at the Grenoble teaching hospital between 2004 and 2014, there were 16 STKI IV and 5 STKI V. There were 14 boys and 7 girls. Sixty-eight percent of the injuries happened during the winter, between December and April. The average age was 10.3 and 12.2 years for STKI IV and V respectively. In 15 cases, it was during mountain sports, in 2 cases school activities and in 5 cases road accidents.

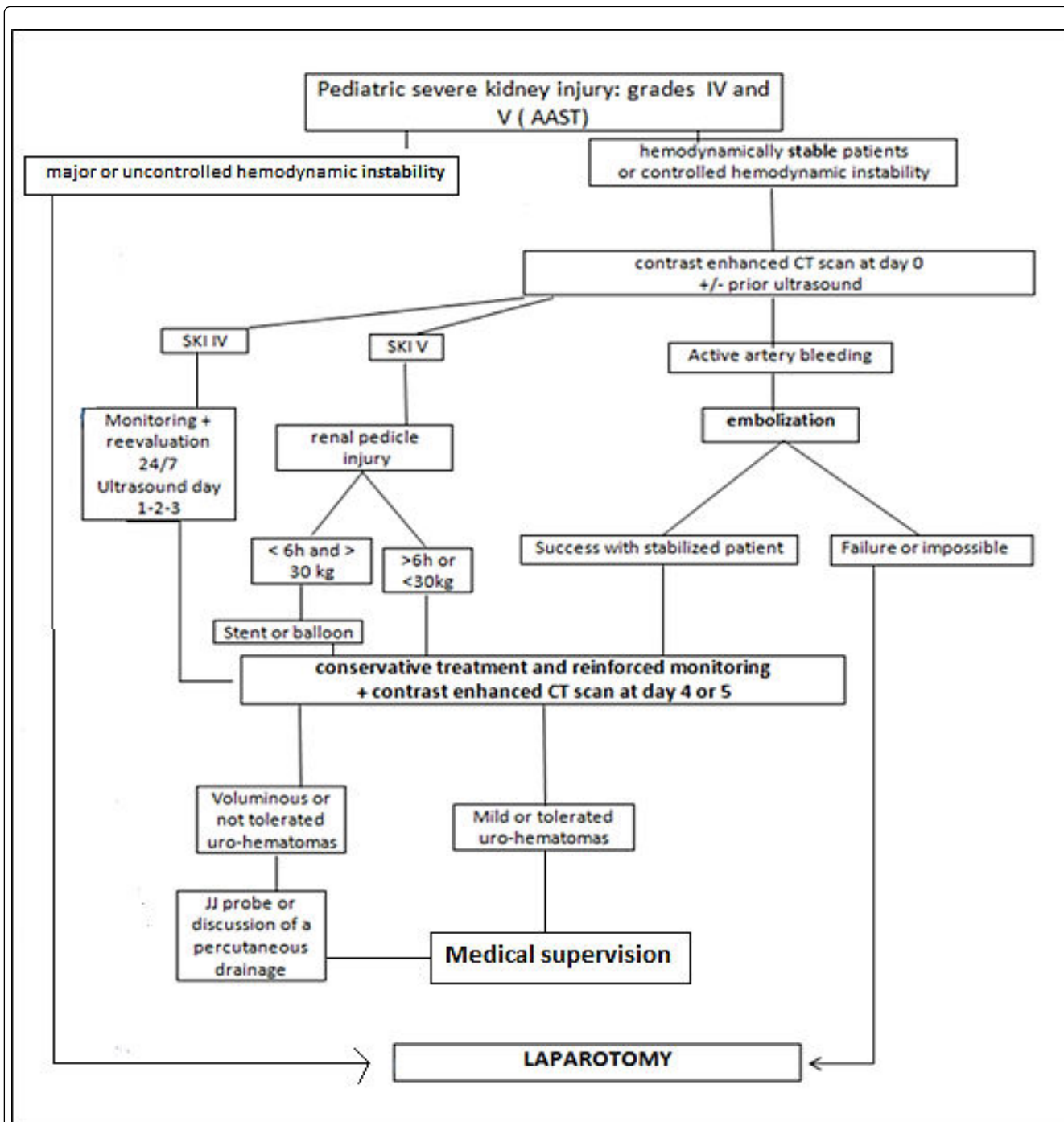


Figure 1: Algorithm of management of pediatric STKI at the Grenoble teaching hospital.

Four children came from a foreign country. The diagnosis of grade was made on arrival at the center. All the children except one had a CT-scan evaluation at day 0 (8 cases with an initial ultrasonography and 13 cases with only a CT-scan. One child only had an ultrasonography because of a SKI III initially diagnosed). Concerning the clinical presentation, 4 children were hemodynamically unstable on arrival (3 STKI IV and 1 STKI V), 8 required a blood transfusion (5 within the first 24 hours and then 3). There was a poly traumatism,

associated in particular with another intra-abdominal trauma, in 3 STKI IV, and 4 STKI V. A child with a STKI IV had a contralateral kidney lesion (grade II). A urinary catheter was systematically inserted on arrival. Three children had an isolated hematuria and 6 associated with abdominal pain. A child presented a gross hematuria with clots and required the change of the simple probe to double current probe (Ch18) enabling the urinary lavage.

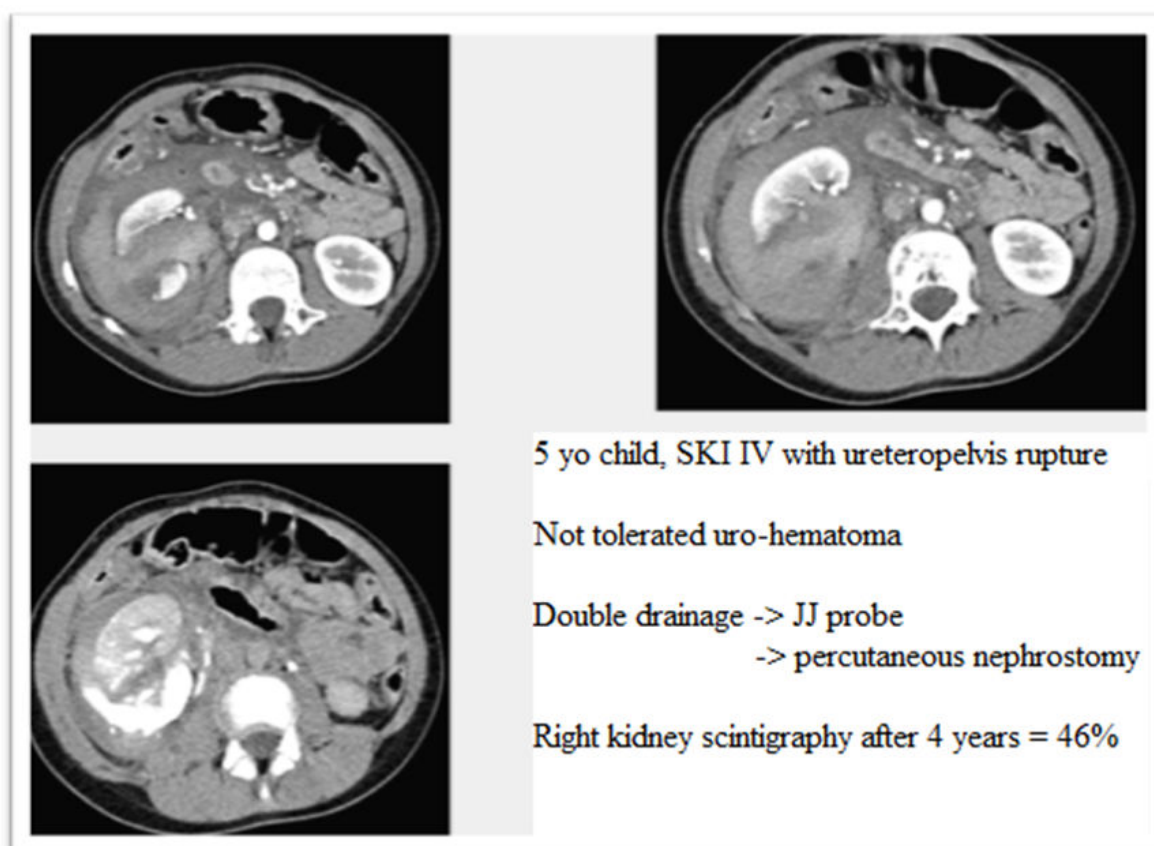


Figure 2: Example of an endo-urologic management: double J stent pose with percutaneous nephrostomy because of a symptomatic uro-hematoma, after ureteropelvic junction rupture.

All children had a CT-scan on day 4 or 5, for a radiological reassessment: 2 diagnoses were modified (grade IV initially considered as grade III), and 1 pelvic fracture and 1 renal revascularization (STKI V) were diagnosed. Regarding the complications, a pleural effusion was found in 5 STKI IV (3 were drained) and in 3 STKI V (1 was drained). Seven children with STKI IV and 2 STKI V had an occlusive syndrome. Among the STKI IV, 2 children had abdominal compartment syndrome (1 was operated), 1 child had an iatrogenic complication (transient lower ureteral stenosis) while one STKI V had a peritoneal lavage for a splenic hemoperitoneum.

Concerning the therapeutic management, 10 children did not benefited from any gesture. There were in the STKI IV, 1 secondary nephrectomy on day 6, 4 double J stent poses, 1 percutaneous nephrostomy (Figure 2), and 3 embolizations on day 0 (Figure 3). For the STKI V, there were 1 arterial stent pose and 1 laparoscopic peritoneal lavage. It was noticed that most of the children with STKI IV during the first 48 to 72 hours, had no particular symptom or complication. They appeared between day 3 to 5 (with discovery of a uro-hematoma on day 5 CT-scan).

The 1st getting up was on average on day 9.4 (range day 6 to 14). The average hospital stay was 16.4 days (range 10 to 24 days), with the school activities taken back on day 27.8 (range day 14 to 60). After at least 6 months from the trauma, an injured renal function assessed by a DMSA scintigraphy was performed in 11/16 STKI IV and 4/5 STKI

V, and was at 39.4% and 17% respectively (Figure 4). The overall follow-up is between 15 months to 10 years.

Discussion

Our series found that among the 21STKI, 11 children required a therapeutic procedure in which a secondary nephrectomy at day 6, 3 embolizations, 4 double J stent poses, 1 percutaneous nephrostomy, 1 laparoscopic peritoneal lavage for a splenic hemoperitoneum, 4 pleural drainages. These results highlight the importance of embolization and endo urologic approach, with the aim of a conservative renal management, as much as possible. In adults, according to Lanchon [1] with a series of 151 grade IV and V kidney injuries between January 2004 and March 2015, 124 didn't have any surgical exploration or a nephrectomy (regardless of embolization or endo urologic gesture).

The first 48 to 72 hours in STKI IV seem relatively "calm" with no symptom or complication. They appear between day 3 to 5, which brings to our mind the notion of "false-calm", and the need for a radiologic reassessment with a CT-scan on day 4 or 5. The prognosis of STKI V depends on the arrival delay at hospital and the child's age, allowing or not an attempt of vascular stenting. The overall prognosis of STKI V is linked to associated organ injuries. Regarding the injured renal function, it was assessed after at least 6 months from the trauma, and was at 39.4% for the 11/16 STKI IV analyzed, against 17% for the

4/5 STKI V analyzed. These results give an argument in favor of the currently conservative management of STKI in children [2-5], which is already universally accepted. Only a child with STKI V had an injured renal scintigraphy at 0%, and the nephrectomized child with SKI IV had latent renal failure.

Our scintigraphic follow-up rate (71%) can be explained by the fact that it was in many cases tourists, including 4 foreign children. MTEL-Sherniny had found in his center, a renal function assessed by DMSA

scintigraphy between 41% and 50% among the 13 children with severe kidney trauma but he included grades III to V [6]. Compared with adults, the renal pediatric recovery seems discreetly better. The renal function assessed by a DMSA scintigraphy was at 39% and 11% for the STKI IV and V respectively, according to Fiard [7]. It has more recently been estimated at 40% for the STKI IV and 0% for the STKI V, according to Lanchon [1].

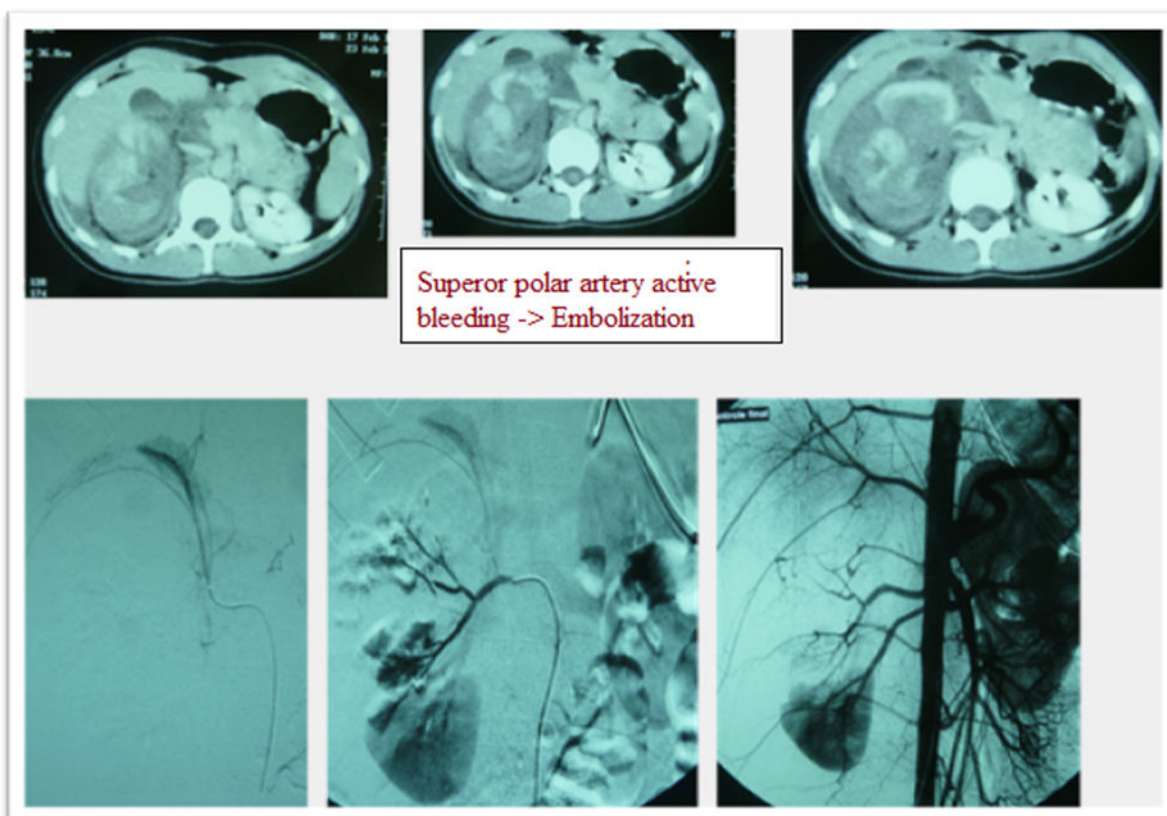


Figure 3: Example of a radio-interventional management: embolization of the right upper polar artery because of an active bleeding, in a hemodynamically stable child.

In severe forms, surgery is necessary, with the issue of the better timing (immediately or delayed surgery). The pedicle lesions have a poor functional prognosis, except for rare cases of possible vascularization, as in a child with a STKI V, who spontaneously revascularized his kidney (seen on day 5 CT-scan). Interventional radiology and endo urology find more and more importance in the management of these injuries, with an indication of arterial embolization when there is an active bleeding on the initial CT-scan, in a hemodynamically stable patient. The equipment of the technical platform and the experience of the radiologist are the key points for a radio-interventional management of these patients.

The classification of the American association for surgery of trauma is a validated tool for assessing the severity of the organ trauma and

prevents the clinical consequences [8]. However, in our series, a child with a trauma of the pedicle (STKI V) had a spontaneous revascularization with an injured renal scintigraphy after nine months at 38%. Despite the initial imaging recommendations with experienced radiologists at our center, day 5 CT-scan made it possible to readjust 2 diagnostics (grade IV initially considered as III) [9]. This reassessment is therefore essential to establish an exhaustive state of post-traumatic lesions, to help to guide the indication of performing an endoscopic procedure (double J stent pose in case of a large uro-hematoma), and to correct grade errors.

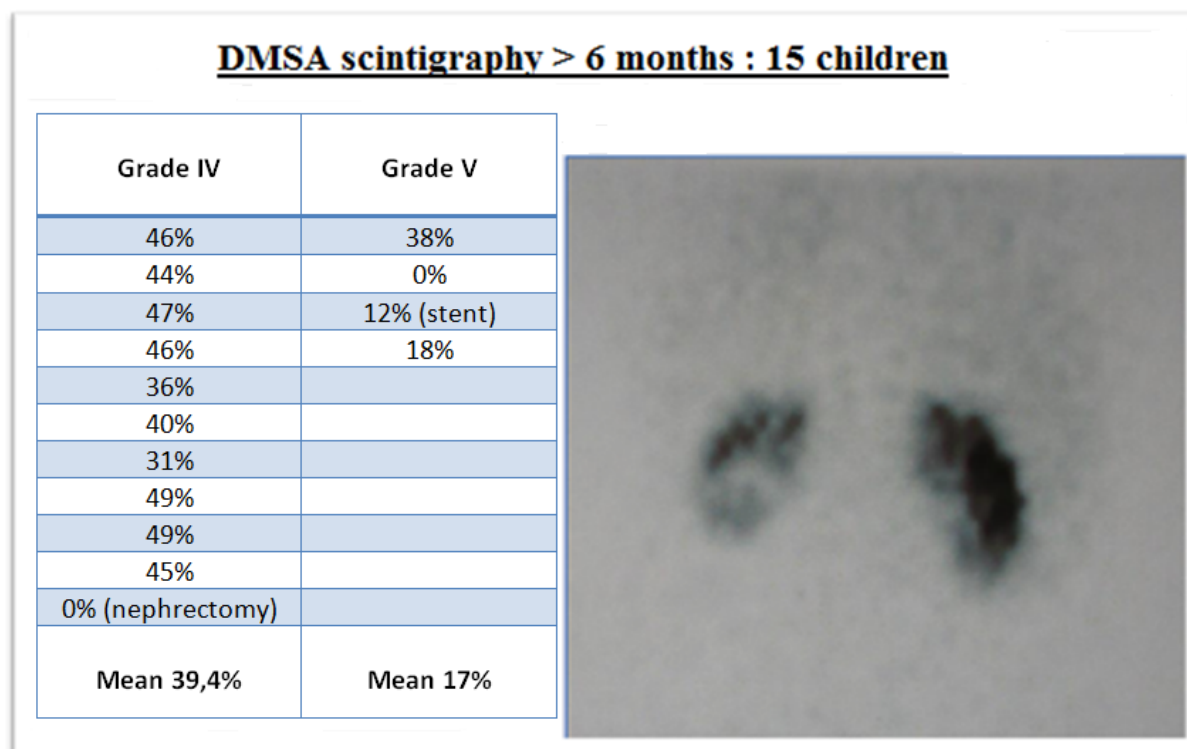


Figure 4: DMSA scintigraphy of the injured kidney after at least 6 months from the trauma.

Conclusion

In our study, therapeutic procedure was needed in 11/21 children with STKI. Endo urologic approach and interventional radiology with embolization enable a conservative management in 20/21 STKI (only one nephrectomy performed on day 6 in a child with STKI IV). Injured renal function after at least six months from the severe trauma in children assessed by a DMSA scintigraphy was at 39.4% for 11/16 STKI IV and 17% for 4/5 STKI V. Only one child STKI V had an injured renal function at 0%.

References

1. Lanchon C, Fiard G, Arnoux V, Descotes JL, Rambeaud JJ, et al. (2016) High Grade Blunt Renal Trauma: Predictors of Surgery and Long-Term Outcomes of Conservative Management. A Prospective Single Center Study. J Urol 195: 106-111.
2. Margenthaler JA, Weber TR, Keller MS (2002) Blunt renal trauma in children: experience with conservative management at a pediatric trauma center. J Trauma 52: 928-932.
3. Rogers CG, Knight V, MacUra KJ, Ziegfeld S, Paidas CN, et al. (2004) High-grade renal injuries in children--is conservative management possible? Urology 64: 574-579.
4. Broghammer JA, Langenburg SE, Smith SJ, Santucci RA (2006) Pediatric blunt renal trauma: its conservative management and patterns of associated injuries. Urology 67: 823-827.
5. Salem HK, Morsi HAA, Zakaria A (2007) Management of high-grade renal injuries in children after blunt abdominal trauma: experience of 40 cases. J Pediatr Urol 3: 223-229.
6. El-Sherbiny MT, Aboul-Ghar ME, Hafez AT, Hammad AA, Bazeed MA (2004) Late renal functional and morphological evaluation after non-operative treatment of high-grade renal injuries in children. BJU Int 93: 1053-1056.
7. Fiard G, Rambeaud JJ, Descotes JL, Boillot B, Terrier N, et al. (2012) Long-term renal function assessment with dimercapto-succinic acid scintigraphy after conservative treatment of major renal trauma. J Urol 187: 1306-1309.
8. Shariat SF, Roehrborn CG, Karakiewicz PI, Dhami G, Stage KH (2007) Evidence-based validation of the predictive value of the American Association for the Surgery of Trauma kidney injury scale. J Trauma 62: 933-939.
9. Lougué-Sorgho LC, Lambot K, Gorincour G, Chaumoitre K, Chapuy S, et al. (2006) Kidney trauma in children: state of the art medical imaging. J Radiol 87: 275-283.