

Erythema Dyschromicum Perstans: A Case Report

Koray Durmaz¹, İlkyay Özer¹, Siddika Fındık², Pembe Oltulu^{2*} and Arzu Ataseven¹

¹Department of Dermatology, Necmettin Erbakan University, Turkey

²Department of Pathology, Necmettin Erbakan University, Turkey

Abstract

Erythema dyschromicum perstans (EDP) or Ashy dermatosis is an uncommon pigmentary disorders which characterized with asymptomatic gray symmetric confluent macules over the body. It usually starts between first to three decades of the life and has a slow onset. This ailment can affect the palms, soles, scalp, nails and mucous membranes. Despite the definition of some etiological factors, the exact etiology of EDP is not clear. In this paper, we present a 24 years old patient with EDP.

Introduction

Ashy dermatosis is an uncommon dermatosis which has unknown etiology [1,2]. There is no accord on the description of EDP and some different terms like EDP, ashy dermatosis, lichen planus pigmentosus and idiopathic eruptive macular pigmentation have being used interchangeably in the literature for this dermatosis [3].

Case Report

A 24 year old woman with type III phototype complexion presented with numerous asymptomatic slate-grey macules on her trunk and back with a 6 year history. Firstly, the lesions had started right side of trunk and new lesions seemed increasingly to involve other areas of trunk and back (Figure 1). There were no identifiable triggers or associated family history. She had no known family history of skin or autoimmune disease either. At the physical examination we noticed brown-grey coloured pigmented macules and patches on the trunk and back. Some of the lesions appeared on her back were encircled by an erythematous halo and had a little elevated borders. The lesions were scaly and also she had mild pruritus on the lesional areas. Histopathological findings of biopsy specimen from trunk showed mild hyperkeratosis, melanocytic hyperplasia at the basement membrane and perivascular lymphocytic infiltrate with melanophages in dermis (Figure 2). Pityriasis rosea was ruled out by reason of spongiosis absence. The patient was diagnosed as EDP with clinical and histopathological findings. Routine laboratory tests including glucose, liver enzymes, thyroid hormones, complete blood count, were normal and Antinuclear antibody (ANA) test was negative. She was treated with narrowband ultraviolet B therapy three times a weekly for 12 weeks. Topical mometasone furoate and

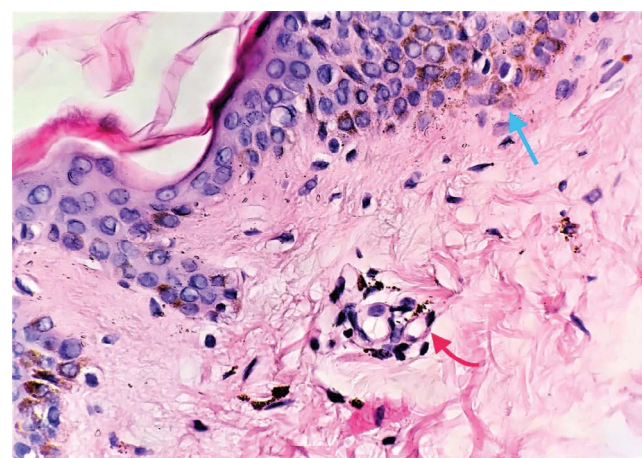


Figure 2: Basal hyperpigmentation (blue arrow), dermal perivascular lymphocytic infiltrate with melanophages (red arrow) (H&E stain, 400x magnification).

emollients were also added to the therapy. After this 12 weeks period, a betterment of the erythematous violaceous component of lesions was noticed.

Discussion

Erythema Dyschromicum Perstans (EDP) or Ashy dermatosis is an uncommon acquired and chronic dermatosis, characterized by asymptomatic and progressive hyperpigmented oval, polycyclic macules of various size on the trunk, face and extremities. These brown-grey macules sometimes show erythematous borders [4,5]. Although the etiology of EDP is unclear there are some probable genetic factors related by genes located in the major histocompatibility complex region [6]. There are also some predisposing triggers that have been proposed, such as drugs (antibiotics, benzodiazepines, pesticides), endocrinopathies or HIV and hepatitis like infectious

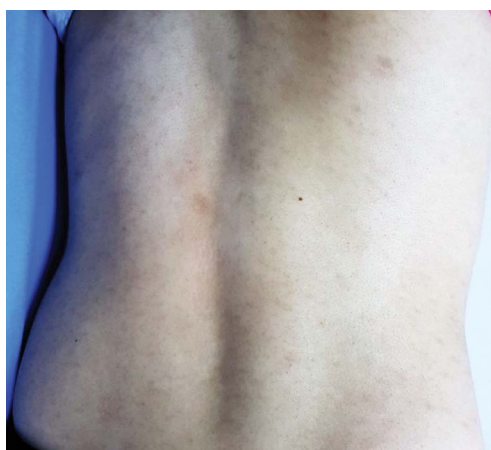

Figure 1: Slate-grey macules on trunk.

***Corresponding author:** Pembe Oltulu, Necmettin Erbakan Üniversitesi Meram Tıp Fakültesi Konya, Turkey, Tel: +903322236000; E-mail: drpembe@yahoo.com

Received July 12, 2017; **Accepted** September 13, 2017; **Published** September 20, 2017

Citation: Durmaz K, Özer İ, Fındık S, Oltulu P, Ataseven A (2017) Erythema Dyschromicum Perstans: A Case Report. Pigmentary Disorders 4: 266. doi:10.4172/2376-0427.1000266

Copyright: © 2016 Durmaz K, et al. This is an open-access article distributed under the terms of the Creative Commons Attribution License, which permits unrestricted use, distribution, and reproduction in any medium, provided the original author and source are credited.

conditions [7-9]. In this case there wasn't any triggers neither medical history nor laboratory findings [10]. The differential diagnosis includes pigmented lichen planus, idiopathic eruptive macular pigmentation, postinflammatory hyperpigmentation and Addison disease. Pigmented lichen planus is the main considered differential diagnosis of EDP. Lesions are usually characterized by bright violaceous-purple, flat, solid papules and often crossed by whitish lines (called as Wickham striae). Lichen planus often involves mucous membranes by some different types and is related with mild pruritus, neither symptoms were present in our patient. Idiopathic eruptive macular pigmentation would be another differential condition, however it presents typically with asymptomatic brownish nonconfluent lesions that involve the face, trunk and proximal extremities in children and adolescents [11]. We excluded postinflammatory hyperpigmentation and Addison disease as a result of examination findings and the anamnesis. Treatment of EDP include topical and systemic steroids, hydroquinone, dapson, retinoids, griseofulvin, ascorbic acid, chloroquine, estrogens, progesterone, chemical peels, phototherapy, laser therapy, keratolytics, clofazimine and nbUVB phototherapy [10,12].

In fact, nbUVB phototherapy decreases peripheral NK cell activity, lymphocyte proliferation, cytokine production as IL-2, IFN- γ and IL-10 [13,14]. NbUVB phototherapy stimulates pigment production and hides the dermal pigmentation [13,14]. In our case we used nbUVB phototherapy 3 times a weekly.

References

1. Keisham C, Sarkar R, Garg VK, Chugh S (2013) Ashy dermatosis in an 8 year old Indian child. *Indian Dermatol Online J* 4: 30-32.
2. Srivastava N, Solanki L, Chand S, Garbyal RS, Singh S (2008) Ashy dermatosis like pigmentation due to ethambutol. *Indian J Dermatol Venereol Leprol* 74: 281-282.
3. Zaynoun S, Rubeiz N, Kibbi AG (2008) Ashy dermatoses-a critical review of the literature and a proposed simplified clinical classification. *Int J Dermatol* 47: 542-544.
4. Osswald SS, Proffer LH, Sartori CR (2001) Erythema dyschromicum perstans: A case report and review. *Cutis* 68: 25-28.
5. Nieuweboer-Krobotova L (2013) Hyperpigmentation: types, diagnostics and targeted treatment options. *J Eur Acad Dermatol Venereol* 27: 2-4.
6. Correa MC, Memije EV, Vargas-Alarcón G, Guzmán RA, Rosetti F, et al. (2007) HLA-DR association with the genetic susceptibility to develop ashy dermatosis in Mexican Mestizo patients. *J Am Acad Dermatol* 56: 617-620.
7. Vázquez-Ochoa LA, Isaza-Guzmán DM, Orozco-Mora B, Restrepo-Molina R, Trujillo-Perez J, et al. (2006) Immunopathologic study of erythema dyschromicum perstans (ashy dermatosis). *Int J Dermatol* 45: 937-941.
8. Kontochristopoulos GJ, Aroni K, Anagnostopoulos G, Nakopoulou L, Tassopoulos NC (2001) Erythema dyschromicum perstans and hepatitis C virus infection. *Int J Dermatol* 40: 346-348.
9. Cherobin AC, Oliveira FO, Baeta IG, Vale EC (2012) Case for diagnosis. Ashy dermatosis. *An Bras Dermatol* 87: 151-152.
10. Novick NL, Phelps R, Tom C (1986) Erythema dyschromicum perstans. *Int J Dermatol* 25:322-323.
11. Oiso N, Tsuruta D, Imanishi H, Kobayashi H, Kawada A (2012) Erythema dyschromicum perstans in a Japanese child. *Pediatr Dermatol* 29:637-640.
12. (1997) An appraisal of narrow band (TL-01) UVB phototherapy. British Photodermatology Group Workshop Report (April 1996). *Br J Dermatol* 137: 327-330.
13. Fabbrocini G, Di Costanzo L (2012) *In vitro* UVA irradiation decreases both release ability and gene-expression of VEGF-A from mastcells. *Photodermatol Photoimmunol Photomed* 28: 165-168.
14. Fabbrocini G, Cacciapuoti S, Izzo R, Mascolo M, Staibano S, et al. (2015) Efficacy of narrowband UVB phototherapy in erythema dyschromicum perstans treatment: case reports. *Acta Dermatovenerol Croat* 23: 63-65.