

Epithelioid Osteosarcoma with Pseudo-Glandular Structures: A Case Report and Review of the Literature

Beibei Gao¹, Daiqiang Lia^{1*}, Jiaoyun Zheng², Xiao Fu¹, Linrong Tuo¹, Xia Wu¹ and Junming Luo^{2*}

¹Department of Pathology, the Second Affiliated Hospital, Xiangya Medical School, Central South University, 156 Renmin Rd, Changsha, Hunan 410011, P.R. China

²Department of Pathology, Qinghai Provincial People's Hospital, 2 Gonghe Rd, Xining, Qinghai, P.R. China

*Corresponding authors: Daiqiang Li MD and Junming Luo, Department of Pathology, the Second Affiliated Hospital, Xiangya Medical School, Central South University, 156 Renmin Rd, Changsha, Hunan 410011, P.R. China; Tel: +86-731-85292139; Fax: +86-731-85292139; E-mail: lidqx@163.com

Received: August 01, 2016; Accepted: October 17, 2016; Published: October 27, 2016

Copyright: © 2016 Gao B, et al. This is an open-access article distributed under the terms of the Creative Commons Attribution License, which permits unrestricted use, distribution, and reproduction in any medium, provided the original author and source are credited.

Abstract

Epithelioid osteosarcoma is an uncommon subtype of conventional osteosarcoma that comprised of both typical osteosarcoma component and epithelioid cells. It often occurs in adolescent and children. In here, we report a case of epithelioid osteosarcoma of a 12-year-old Chinese boy. Microscopically, the tumor contains large epithelioid cell with abundant cytoplasm and osteoid forming malignant cells, and partially, the tumor cells arranged in pseudo-glandular structures. To our knowledge, it is the first report of epithelioid osteosarcoma with pseudo-glandular structure. The epithelioid cells expressed vimentin and epithelial membrane antigen but did not expressed cytokeratin.

Introduction

Osteosarcoma is a primary high-grade malignant tumor of bone that is composed of proliferating cells that produce osteoid. It is the commonest primary bone malignant tumor with a high incidence in children and adolescents [1]. Osteosarcoma shows diverse histological types such as osteoblastic, telangiectatic, chondroblastic and so on. Epithelioid osteosarcoma is a rare variant of osteosarcoma that the tumor cells are differentiated too poorly to distinguish sarcoma from carcinoma [2]. These osteosarcomas have epithelioid cells and may express epithelial marks [3]. This report described the clinicopathological, immunohistochemical (IHC) and imaging features of a epithelioid osteosarcoma with pseudo-glandular structures occurred in tibia. To our knowledge, this is the first report of epithelioid osteosarcoma with pseudo-glandular structure.

Case Report

A 12-year-old Chinese boy had with a clinical history of a progressive pain on the right knee that had been lasting for three months after an accidental fall. The pain often begins insidiously, but persistent and gradually exacerbate. Physical examination showed a tenderness swelling with superficial erythema in the right proximal tibia. The swelling has higher skin temperature and an unclear boundary. Laboratory examination showed four to five times of ALP compared with normal condition (ALP 558U/L). The X-ray revealed a large, poorly defined high density shadow in the right upper tibia, along with soft tissue extension in which there are many high-density shadows. Periosteal reaction with a Codman's triangle of focal periosteal elevation as well as cortical destruction also showed in this case. MRI demonstrated a large osseous destructive region mixed with T1 and T2 weighted images in the right upper tibia. The maximum area of the mass was 51 mm × 64 mm and the involvement of cortex was unclear. Soft tissue component showed slightly long T1 and long T2 abnormal weighted images with heterogeneous enhancement. PET-CT showed bone destruction, soft tissue extension and abnormal

glucose metabolism in the right tibia. According to the clinical and imaging findings, a diagnosis of osteosarcoma has been taken into consideration. A biopsy was taken under local anesthesia. Microscopically, H&E staining sections showed sheets of tumor cells which have atypical nuclei, along with focal neoplastic bone formation and calcification. A diagnosis of osteosarcoma has been made by two independent pathologists. The patient was treated with chemotherapeutic regimens: HD-MTX+DDP+IFO+EPI (high-dose methotrexate, Cisplatin, Ifosfamide and epirubicin). After using up of 13 g HD-MTX and 160 mg DDP, several toxic effects appeared. The patient presented with serious nausea, vomit, mucositis and even bone marrow suppression. So the therapy had to be changed into surgery. A tumor resection+right knee arthroplasty had been performed under general anesthesia; the patient has recovered well after operation.

Grossly, the resection specimen showed an irregular mass of 4.5 cm×3 cm in the medullary canal. The tumor destructed the cortical bone and encroached the contiguous soft tissues. Histologically, the tumor cells were ovoid or polygonal with abundant eosinophilic cytoplasm that arranged in clusters, nests, trabeculae, cords or rosette-like structures. Focal osteoid formation, multinucleated giant cells and tumor cells embedded in a background of osteoid matrix were also present. In some area, tumor cells were aligned in palisade around small vascular structures presented a hemangiopericytomatous pattern.

A noteworthy finding was the presence of pseudo-glandular structures formed by the homogeneous large epithelioid cells with abundant eosinophilic cytoplasm, which extremely mimicking carcinoma.

A panel of immunohistochemical stains was performed. The tumor was positive for vimentin, CD99 and CD56. Epithelial membrane antigen stained positive only in the epithelioid cells. NSE, S-100, CK were negative. Ki-67 index was 10%, CD34 was positive in vasculum.

Based on the results of clinical manifestation, radiography, histopathology, and immunohistochemistry, the diagnosis of epithelioid osteosarcoma has been made definitively.

Two months later, the patient came to us again complaining a gradually increased mass in the right lower leg approximate to knee-joint. Physical examination showed a 5 cm × 5 cm firm, non-tenderness swelling with higher skin temperature and an unclear boundary in the right lower leg 5 cm away from the knee-joint. The venous on the surface of the swelling was obviously engorgement. The X-ray suggested a recurrence of osteosarcoma, tumor resection had been performed under general anesthesia. The histopathology features and diagnosis of the tumor consistent with last surgical pathology. The patient has recovered well after operation.

Discussion

Osteosarcoma is the eighth-most common cancer in children, accounting for 2.4% of all malignancies in pediatric patients, and 20% of all primary bone cancers [4]. It has a bimodal distribution, the peak incidence is in the second and third decades. At all ages, osteosarcoma occurs nearly twice as often in men than in women [5]. More than 75% osteosarcoma occurs in long bones, and the predilection site is metaphysis [6]. The 5-year survival ranges from 60 to 70% [7,8]. Epithelioid osteosarcoma is a rare histological subtype of osteosarcoma that characteristically comprised of both primary osteosarcoma tumor cells and a second type of cells which morphologically mimic the epithelium cells [9]. In 1975, Scranton reported the first osteosarcoma showing epithelioid features, followed by a few other reports [10]. According to these reports, patients' age ranged from 4½ to 50 years old and the average age was 18. It occurs predominately in long bones (20/26) and affects males (16/26) more often than females (10/26) which consistent with osteosarcoma [3,11-18].

Epithelioid osteosarcoma presents clinically and radiographically like a conventional osteosarcoma. The clinical symptoms of osteosarcomas are usually nonspecific. Many patients first complain of a dull, aching, persistent pain that may be exacerbated with activity or at night. The most common symptom is a firm and tender mass, with superficial erythema or venous distension [13]. All of these symptoms suggested the necessity of a further clinical examination.

Imaging plays a key role in the diagnosis of bone tumors such as osteosarcoma. Radiography will commonly demonstrate both lucent and sclerotic features as the tumors destroy normal bone and lay down osteoid. X-Ray may show subperiosteal bone formation, creating a triangle of subperiosteal bone, known as Codman's triangle. Since many osteosarcomas have destructed through the cortex at the time of diagnosis, there is often a large soft tissue mass [19]. This mass is usually mineralized, which is a characteristic of osteosarcoma.

The histopathological features of epithelioid osteosarcoma consist of epithelioid cells and a typical osteosarcoma with osteoid formation. The large, polygonal epithelioid cells with abundant eosinophilic cytoplasm may arrange in sheets, strands, glandular, trabeculae or rosettes structures [13]. They may even resemble some poorly differentiated carcinomas or aligned in palisade around small vascular structures presented a hemangiopericytomatous pattern [9]. Many other histological features as pleomorphic spindle cells, multinucleated giant cells, clear cells and necrosis also can be seen in epithelioid osteosarcoma [9]. Osteoid formation by adjacent malignant cell is also an important feature in the diagnosis of epithelioid osteosarcoma. In our case, we reported pseudo-glandular structures formed by the large

epithelioid cells with abundant eosinophilic cytoplasm, which haven't been described before.

Rosette-like structures, which refers to tumor cells arranged in rosette like structures with lacelike osteoid in the center were described in 5.7% of all types of osteosarcoma, were considered to have a poorer prognosis than other osteosarcoma [12,20]. In contrast to the over 70% ten-year survival rate of conventional osteosarcoma, the 5-year survival rate for patients with rosette-like structures is only 13.5% [17].

Currently, immunohistochemistry has a limited role in diagnosing osteosarcoma, and this tumor type is largely identified by its morphologic features [18]. Our case showed focal positivity for EMA and diffused positive for VIM, but negative for CK. It had to be recognized that epithelioid cell is only a morphological term, and the express of CK or EMA is not necessary [9]. Other studies also have reported negative results for EMA, CK, or both (Table 1).

Author	Age	Sex	Site	CK	EMA	VIM	CD99	CD34	S-100	Ki67 index
Kramer et al. [3]	13	M	lateral ankle	+	+	+	nd	nd	nd	nd
Hasegawa et al. [11]	49	M	lumbar vertebra	+	+	+	nd	nd	+	nd
Okada et al. [12]	15	F	Tibia	nd	-	nd	-	nd	nd	10
	21	M	Femur	nd	-	nd	-	nd	nd	20
	17	M	Tibia	nd	+	nd	+	nd	nd	40
	8	M	Femur	nd	+	nd	-	nd	nd	30
	12	M	Femur	nd	+	nd	-	nd	nd	35
	13	M	Femur	nd	+	nd	-	nd	nd	25
	14	M	Femur	nd	-	nd	-	nd	nd	75
	21	F	Femur	nd	+	nd	-	nd	nd	35
	14	M	Femur	nd	-	nd	+	nd	nd	40
	18	M	Femur	nd	+	nd	-	nd	nd	25
	11	F	Femur	nd	+	nd	-	nd	nd	30
	9	F	Femur	nd	+	nd	-	nd	nd	80
	13	F	Tibia	nd	-	nd	-	nd	nd	80
	13	M	Femur	nd	+	nd	-	nd	nd	75
	26	M	Femur	nd	+	nd	+	nd	nd	85
	19	M	Femur	nd	-	nd	-	nd	nd	70
Rinaggio et al. [13]	50	M	Maxillary	-	-	+	nd	nd	-	n
Carlos-Bregni et al. [9]	42	F	Mandible	-	-	-	-	-	-	18
Kaven et al.	4½	M	maxilla	+	+	nd	nd	nd	nd	nd
Layfield et al. [14]	33	F	Femur	+	nd	-	nd	nd	-	nd

Cozza et al. [16]	8	F	Jaw	-	+	+	-	-	nd	nd
Amanatullah et al. [17]	11	F	Tibia	-	-	+	+	nd	nd	nd
ALQahtani et al. [18]	22	F	Maxilla	-	+	+	-	nd	nd	nd
Current case	12	M	Tibia	-	+	+	+	+	-	10

Table 1: Clinicopathological and immunochemical profiles of Epithelioid osteosarcoma.

Fore (40%) of the ten cases showed staining for cytokeratin (CK), seven(78%) of nine cases showed positive stain for VIM, epithelial membrane antigen (EMA) reactivity was present in the cell membrane of 16 tumors (64%), the positive rate for CD99, CD34, S-100 were 19%, 33% and 20%, respectively. The Ki-67 index varied from 10% to 85% (mean, 44%) [3,11-18]. Immunohistochemical pattern maybe just a supplementary factor for diagnosis of epithelioid osteosarcoma, but not the critical factor.

In differential diagnosis of epithelioid osteosarcoma, melanoma,metastatic carcinoma,tumor of mesenchymal tissue such as angiosarcoma, fibrosarcoma, or epithelioid sarcoma should be excluded, even though melanomas rarely metastasize to bone [16,21]. If the histopathology features of tumors like these are found in the bones of young patients, the diagnosis of epithelioid osteosarcoma should be our first concern. However, in older patients, we must firstly ruled out poorly differentiated metastatic carcinoma by more clinical or imaging examinations [1]. When the diagnosis of osteosarcoma come upon your mind, a thorough, careful investigate for osteoid matrix must be carried on, especially in young patients. When there are areas of obvious osteoid matrix formation, which suggesting the typical osteosarcoma, the diagnosis of osteosarcoma will be made easily. Immunohistochemistry may also be helpful in the differential diagnosis between epithelioid osteosarcoma and metastatic carcinoma. Immunohistochemically, metastatic carcinoma usually stained much stronger both for CK and EMA than epithelioid osteosarcoma.

Treatment of EOS concordant with osteosarcoma, comprised of radical surgery, radiation therapy and chemotherapy. Neoadjuvant and adjuvant radiation therapy usually be given before operation. Local recurrence and distant metastasis are common. Lung is the primary sites for metastasis, while involvement of nodal is rare [22].

Many hypotheses are supposed to explain the pathogenesis of these biomorphic differentiation malignancies. The most popular one is an uncommitted, multi potential stem cell, which means during the progression of tumor cells, some of the differentiating mesenchymal cells can get morphological characteristic of epithelial cell and express epithelial markers [3]. The cell types most commonly include squamous, transitional, or adenocarcinoma combined with rhabdomyosarcoma, leiomyosarcoma, chondrosarcoma, or osteosarcoma [3]. Derek et al. presents a case of epithelioid osteosarcoma where the epithelial and mesenchymal cells had differential responses to chemotherapy, the epithelial component was more aggressive than the cells of mesenchymal origin resulting in metastasis at last. The patients have local recurrence and metastasis, and the predominant cell type in the areas of recurrence and metastasis were of the epithelioid type, not the osteoid-producing cells of osteosarcoma [17].

In summary, we reported a case of epithelioid osteosarcoma in the tibia because of its specific histopathology feature, low incidence and invasive clinical behavior. In our case, we noticed the presence of pseudo-glandular structures formed by the large epithelioid cells, which is really rare in epithelioid osteosarcoma. Cause osteosarcoma with epithelioid component has been considered to be more aggressive, we believed that it is necessary to distinguish epithelioid osteosarcoma from conventional osteosarcomas (Figure 1).

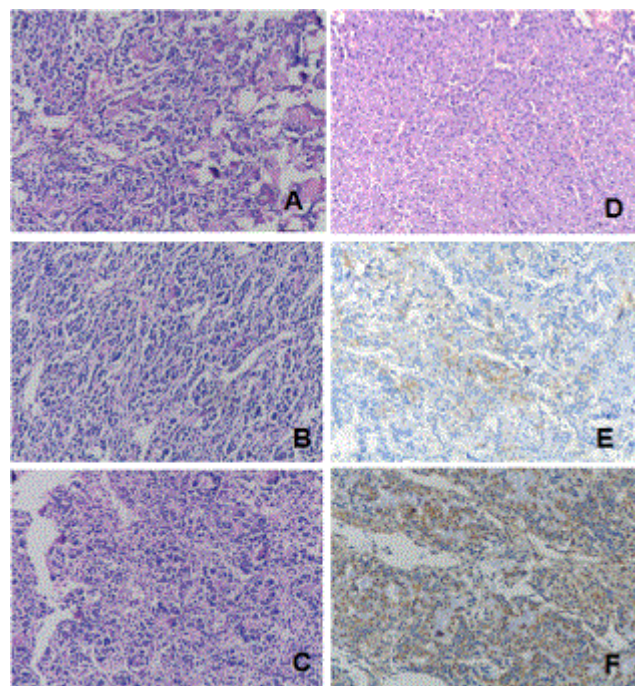


Figure 1: The morphology and immunohistochemical expression pattern of this case. A shows tumor cells producing osteoid matrix resemble a typical osteosarcoma (HEX100); B shows Tumor cells with ovoid or polygonal with eosinophilic cytoplasm arranged in pseudo-glandular structures. (HEX100); C shows tumor cells arranged in rosettelike structures with lacelike osteoid in the center, (HE X100); D shows tumor cells arranged in nests showing epithelioid cell features HE X100; E Shows Epithelioid cells stain positive for EMA (X200); F shows tumor cells stain positive for VIM (X200).

References

1. Klein MJ, Siegal GP (2006) Osteosarcoma: anatomic and histologic variants. *Am J Clin Pathol* 125: 555-558.
2. Unni KK (1998) Osteosarcoma of bone. *J Orthop Sci* 3: 287-294
3. Kramer K, Hicks DG, Palis J, Rosier RN, Oppenheimer J, et al. (1993) Epithelioid osteosarcoma of bone. Immunocytochemical evidence suggesting divergent epithelial and mesenchymal differentiation in a primary osseous neoplasm. *Cancer* 71: 2977-2982.
4. Ottaviani G, Jaffe N (2009) The epidemiology of osteosarcoma. *Cancer Treat Res* 152: 3-13
5. Okada K, Hasegawa T, Yokoyama R, Beppu Y, Itoi E (2003) Osteosarcoma with cytokeratin expression: a clinicopathological study of six cases with an emphasis on differential diagnosis from metastatic cancer. *J Clin Pathol* 56: 742-746.

6. Sim FH, Frassica FJ, Unni KK (1995) Osteosarcoma of the diaphysis of long bones: clinicopathologic features and treatment of 51 cases. *Orthopedics* 18: 18-23.
7. Ferrari S, Mercuri M, Bacci G (2002) Comment on "prognostic factors in high-grade osteosarcoma of the extremities or trunk: an analysis of 1,702 patients treated on neoadjuvant cooperative osteosarcoma study group protocols". *J Clin Oncol*.
8. Bacci G, Longhi A, Versari M, Mercuri M, Briccoli A (2006) Prognostic factors for osteosarcoma of the extremity treated with neoadjuvant chemotherapy: 15-year experience in 789 patients treated at a single institution. *Cancer* 106: 1154-1161.
9. Carlos-Bregni R, Contreras E, Hiraki KR, Vargas PA, León JE (2008) Epithelioid osteosarcoma of the mandible: a rare case with unusual immunoprofile. *Oral Surg Oral Med Oral Pathol Oral Radiol Endod* 105: e47-52.
10. Scranton PE Jr, DeCicco FA, Totten RS, Yunis EJ (1975) Prognostic factors in osteosarcoma. A review of 20 year's experience at the University of Pittsburgh Health Center Hospitals. *Cancer* 36: 2179-2191.
11. Hasegawa T, Shibata T, Hirose T, Seki K, Hizawa K (1993) Osteosarcoma with epithelioid features. An immunohistochemical study. *Arch Pathol Lab Med* 1993; 117: 295-8.
12. Okada K, Hasegawa T, Yokoyama R (2001) Rosette-forming epithelioid osteosarcoma: a histologic subtype with highly aggressive clinical behavior. *Hum Pathol* 32: 726-733.
13. Rinaggio J, Kewitt GF, McGuff HS (2007) Epithelioid osteosarcoma presenting as a rapidly expanding maxillary mass. *Head Neck* 29: 705-709.
14. Layfield LJ, Emerson L, Crim JR, Randall L (2008) Squamous differentiation and cytokeratin expression in an osteosarcoma: a case report and review of the literature. *Clin Med Pathol* 1: 55-59.
15. Kaveri H, Rekha K, Punnya VA (2009) Epithelioid osteosarcoma of the maxilla: report of an unusual case. *Br J Oral Maxillofac Surg* 47: 143-5.
16. Cozza R, Devito R, De Ioris MA, Zama M, Boldrini R, et al. (2009) Epithelioid osteosarcoma of the jaw. *Pediatr Blood Cancer* 52: 877-879.
17. Amanatullah DF, Ngann KK, Borys D, Tamurian RM (2010) Progression of aggressive metastatic carcinosarcoma after treatment of epithelioid osteosarcoma. *Orthopedics* 33: 445.
18. ALQahtani D, AlSheddi M, Al-Sadhan R (2015) Epithelioid Osteosarcoma of the Maxilla: A Case Report and Review of the Literature. *Int J Surg Pathol* 23: 495-499
19. Peabody T (2014) *Orthopaedic Oncology .Primary and Metastatic Tumors of the Skeletal System*. Cancer Treatment and Research.
20. Okada K, Hasegawa T, Yokoyama R, Beppu Y, Itoi E (2003) Prognostic relevance of rosette-like features in osteosarcoma. *J Clin Pathol* 56: 831-834.
21. Hasegawa T (1997) Histological and immunohistochemical diversities, and proliferative activity and grading in osteosarcomas. *Cancer Detect Prev* 21: 280-287.
22. Delgado R, Maafs E, Alfeiran A, Mohar A, Barrera JL, et al. (1994) Osteosarcoma of the jaw. *Head Neck* 16: 246-252.