

Epithelial Malignancies Arising in Ovarian Mature Cystic Teratoma: A Series of 26 Cases

Ud Din N^{1*}, Minhas K¹, Arshad S² and Kayani N¹

¹Assistant Professor, Department of Pathology and Laboratory Medicine, Aga Khan University Hospital, Karachi, Pakistan

²Resident and Instructor, Department of Histopathology, Aga Khan University Hospital, Karachi, Pakistan

Abstract

Objective: To report a series of epithelial malignancies arising within ovarian teratomas along with clinical follow-up. Some previously unreported combinations of malignant component with MCT are also being reported.

Material and Methods: Clinico-pathological details and clinical follow up of twenty six cases reported during January 2000 to March 2014 in the Section of Histopathology, of a tertiary care hospital of Pakistan are included.

Results: Total 1418 cases of MCTs were reported, 26 (1.8%) of them showed epithelial malignancies. The mean age at presentation was 42.5 years (range; 15-70 years). Commonest clinical presentation was with abdominal pain and mass. All the patients underwent surgery as first line treatment. Malignant transformation in form of Squamous cell carcinoma was seen in 20 cases. In one case, in addition to squamous cell carcinoma, atypical proliferative serous tumor and high grade sarcomatous component was also present. Adenosquamous carcinoma, Poorly differentiated carcinoma, Endometrioid adenocarcinoma and Adenocarcinoma with mucinous differentiation represented malignant components in additional 4 cases respectively. Cases demonstrating endometrioid features and atypical proliferative serous tumor represent collision tumors. Two of the cases had papillary carcinoma (follicular variant) of thyroid arising within monodermal teratoma (struma ovarii). Clinical follow up was available in 13 cases and it is noted that patients with squamous cell carcinoma had a worse outcome.

Conclusions: Malignancy occurring in a MCT is an extremely rare occurrence. It is very challenging to diagnose this malignant transformation clinically.

Keywords: Mature cystic teratoma; Malignant transformation; Squamous cell carcinoma; Collision tumors

Introduction

Germ cell tumors comprise approximately 20% of all ovarian tumors, majority (95%) being mature cystic teratoma (MCT). It is also the most common ovarian neoplasm in patients under 20 years [1]. Mature cystic teratoma is a benign tumor and usually presents as a multiloculated cyst containing keratinous material with hair. It may undergo malignant transformation but the incidence is less than 2% [2-4]. Squamous cell carcinoma being the commonest (80%), followed by adenocarcinoma [5]. The frequency of malignant transformation is most commonly seen in the fifth and sixth decades of life and the finding is incidental in nearly all cases [6].

Due to low incidence of malignant transformation, preoperative risk assessment of malignancy is very challenging and debatable but it is of great importance for optimal treatment planning and management, as the overall prognosis for these tumors is poor [7]. We herein report a series of 26 cases of epithelial malignancies arising in mature cystic teratoma with clinical follow up.

Materials and Methods

Surgical pathology record of section of histopathology, department of Pathology and Laboratory Medicine, Aga Khan University Hospital, Karachi Pakistan was looked at and total cases of teratomas reported during a period of 14 years were noted. Clinical details of all the cases of teratomas with malignant transformation were collected and the follow up was obtained by telephonic communication with the patient after taking an informed consent.

Results

Over a period of 14 years, 1418 cases of MCTs were diagnosed.

Malignant epithelial transformations were noted in 26(1.8%) of the MCT's. The mean age was 42.5 years (range; 15-70 years). The commonest clinical presentation was abdominal pain and mass. All these patients underwent surgery as first line treatment. Details of surgery, extent of involvement, type of malignant epithelial component within mature cystic teratoma along post-surgical treatment and follow up are summarized in Table 1. Six cases were consultation cases out of which in five cases representative blocks and slides were received. In one case (case 20), previously grossed specimen was also received in addition to the slides and blocks. Out of 26 cases pathological stage could not be determined in ten cases (six were received for consultation). Nine cases were classified as Stage IA, four as stage IC and three as stage IIIC. Two had bilateral MCT but malignant epithelial component was present in one ovary. Mean size of ovarian tumors was 12.6 cm (range 7-21 cm). Apart from five consultation cases for which macroscopic features were not known, most tumors were predominantly cystic (10 out of 19 cases). Others were solid cum cystic. Cystic areas had sebaceous material, hairs and Rokitansky's protuberances. Microscopically, mature teratomatous component included skin with adnexal structures, gastric and respiratory type mucosa, skeletal

***Corresponding author:** Ud Din N, Assistant Professor, Department of Pathology and Laboratory Medicine, Aga Khan University Hospital, Karachi, Pakistan, Tel: +922134930051; E-mail: nd176@yahoo.com

Received October 15, 2015; **Accepted** January 28, 2016; **Published** January 30, 2016

Citation: Ud Din N, Minhas K, Arshad S, Kayani N (2016) Epithelial Malignancies Arising in Ovarian Mature Cystic Teratoma: A Series of 26 Cases. J Cytol Histol S5: 001. doi:[10.4172/2157-7099.S5-001](https://doi.org/10.4172/2157-7099.S5-001)

Copyright: © 2016 Ud Din N, et al. This is an open-access article distributed under the terms of the Creative Commons Attribution License, which permits unrestricted use, distribution, and reproduction in any medium, provided the original author and source are credited.

Cases	Age (years)	Initial treatment	Organ(s) involved	Stage	Size of teratoma (greatest dimension)	Histology	Follow up data	Status and length of follow up
1 (CC)	38	Oophorectomy	Not known	-	Not known	SCC	Lost to follow up	-
2	35	Left salpingo-oophorectomy	Left ovary	-	14 cm	SCC	Lost to follow up	-
3	50	Left salpingo-oophorectomy	Left ovary	IA	19 cm	SCC	Lost to follow up	-
4	50	Salpingo-oophorectomy	Ovary	IA	12.5 cm	SCC	Lost to follow up	-
5	15	Right oophorectomy	Right ovary	IA	9.5 cm	SCC (Occasional foci)	Chemotherapy	NED, 7 yrs. and 3 mo.
6	70	TAH with BSO and omentectomy	Left ovary and omentum	IIIC	12 cm	SCC	Lost to follow up	-
7	29	Left oophorectomy	Left ovary	IC	9 cm	SCC+ APST + high grade sarcomatous component	Lost to follow up	-
8	35	TAH with BSO and segmental intestinal resection	Left ovary, left fallopian tube, terminal ileum and sigmoid colon.	IIIC	9 cm	SCC	Lost to follow up	-
9 (CC)	45	Oophorectomy	Not known	-	Not known	SCC	Lost to follow up	-
10	37	TAH with BSO and omentectomy	Right ovary	IA	21 cm	Bilateral MCT with SCC in right ovary	Radiotherapy	DOD, 9 mo.
11	55	Right salpingo-oophorectomy	Right ovary	IA	16.5 cm	SCC	Radiotherapy	DOD, 3 mo.
12	45	Oophorectomy	Not Known	-(received in multiple pieces)	20 cm	PC in struma ovarii	Chemotherapy	DOD, 15 mo.
13	38	TAH with BSO and omentectomy	Left ovary	IA	11 cm	Bilateral MCT with adenosquamous carcinoma in left ovary	Chemotherapy	NED, 4 yrs. and 2 mo.
14 (CC)	40	TAH with BSO	Not known	-	Not Known	MCT with coexistent Endometrioid ca.	Chemotherapy	DOD, 2 yrs.
15	50	TAH with BSO and omentectomy	Right ovary	IA	17 cm	Poorly differentiated carcinoma	Lost to follow up	-
16 (CC)	52	Not known	Not known	-	Not known	SCC	Lost to follow up	-
17	50	TAH with BSO	Unilateral	IA	14 cm	SCC	Lost to follow up	-
18 (CC)	42	TAH with BSO	Left ovary	-	11cm	PC in struma ovarii	chemotherapy	NED, 2 yrs. and 2 mo.
19	32	Right salpingo-oophorectomy	Right ovary	IC	13 cm	SCC	No further treatment	DOD, 9 mo.
20 (CC)	40	Right Oophorectomy	Right ovary	-	18 cm	SCC	Lost to follow up	-
21	40	Left Oophorectomy	Left ovary	IA	11 cm	SCC	chemotherapy	NED, 7 mo.
22	18	Right salpingo-oophorectomy	Right ovary	IC	12 cm	Adenocarcinoma with mucinous differentiation	chemotherapy	NED, 3 mo.
23	50	Right Oophorectomy	Right ovary	IC	7 cm	SCC	Lost to follow up	-
24	45	TAH with BSO, segmental intestinal resection and omentectomy	Unilateral ovary and intestine	IIIC	10	SCC	No further treatment	DOD, 4 mo.
25	45	TAH with BSO	Right ovary		11	SCC	No further treatment	NED, 3 mo
26	60	TAH with BSO	Left ovary		10.5	SCC	Chemotherapy	NED, 3 mo

CC: Consultation cases in which representative blocks were received, TAH: Total abdominal hysterectomy, BSO: Bilateral salpingo-oophorectomy, SCC: squamous cell carcinoma, APST: Atypical proliferating serous tumor, PC: papillary carcinoma, MCT: mature cystic teratoma, NED: no evidence of disease at latest follow-up check, DOD: died of disease.

Table 1: Summary of cases of epithelial malignancies arising in MCT.

muscle, bone, lobules of mature hyaline cartilage and thyroid follicles, in variable proportions and frequencies. Mature glial tissue, however, was not noted. Malignant transformation in form of squamous cell carcinoma was seen in 20 cases (Figure 1). In one case, in addition to squamous cell carcinoma, atypical proliferative serous tumor and high grade sarcomatous component was also present. Adenosquamous carcinoma (Figure 2), poorly differentiated carcinoma, Endometrioid adenocarcinoma (Figure 3) and adenocarcinoma with mucinous

differentiation represented malignant components in additional four cases respectively. Two of the cases had papillary carcinoma (follicular variant) of thyroid (Figure 4) arising within monodermal teratoma (struma ovarii). Three cases (cases 6,8,24) with squamous cell carcinoma had extra-ovarian involvement, one had omental involvement, and another had ipsilateral fallopian tube, terminal ileum and sigmoid colon involvement, while the third had intestinal involvement. In only two cases (case 13,14) serum tumor markers were

performed and serum CA-125 levels were raised 581 U/ml and 440 U/ml respectively (normal range 0-35 U/ml), while serum β hCG and AFP were within normal limits. Clinical follow up: Follow up of 13 patients was available. Of these, 8 cases had squamous cell carcinoma as the malignant component. Two of these patients (cases 10,11 respectively) received radiotherapy, but both died of disease after 9 and 3 months of surgery respectively. Two patients (cases 21,26) received chemotherapy; are alive with no evidence of disease after 7 and 3 months of surgery respectively. Case 5 was a teenage girl in which occasional foci of SCC were reported within a MCT. She received postoperative chemotherapy and is free of disease at 7 years and 3 months follow up. Two patients (cases 19,24) did not receive any additional therapy and died within one year of surgery, while one patient (Case 25), who did not receive any further treatment is free of disease at 3 months follow up. Patients with endometrioid type of adenocarcinoma (case 14) died after 2 years of surgery and post-operative chemotherapy. Extent of disease was not known as this was a consultation case. Patients with adenocarcinoma having mucinous differentiation (case 22) and with adenosquamous transformation (case 13) received chemotherapy and are disease free (follow up period; 27 months and 60 months respectively). Both patients (cases 12,18) with papillary carcinoma received chemotherapy, one of them died of disease after fifteen months of surgery. The other is free of disease till date (follow up period; 49 months).

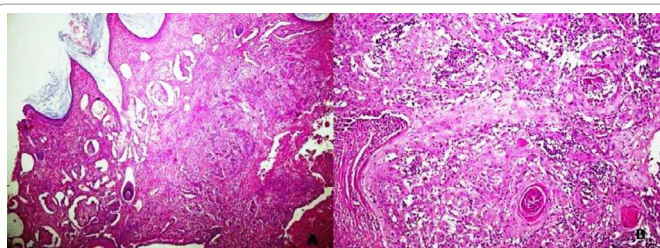


Figure 1: Squamous cell carcinoma arising in MCT. Keratinizing stratified squamous epithelium with underlying adnexal structures. Deep infiltrating tumor is seen (A, H & E, low power examination); Keratinizing squamous cell carcinoma (B, H & E, high power examination).

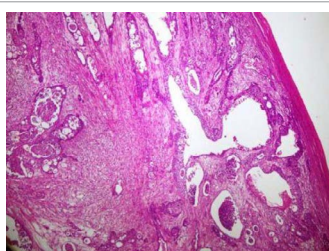


Figure 2: Adenosquamous cell carcinoma exhibiting glandular differentiation and squamous nests (H & E, 100X magnification).

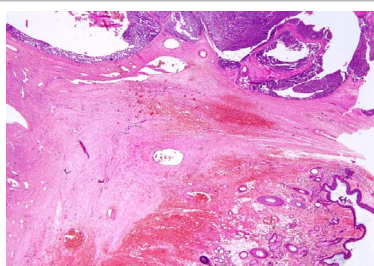


Figure 3: Endometrioid type adenocarcinoma (top) arising in MCT (bottom) (H & E, 100X magnification).

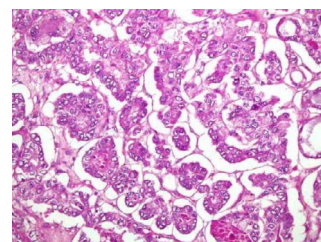


Figure 4: Follicular variant of papillary carcinoma arising in struma ovarii (H & E, 200X magnification).

Discussion

Malignant transformation within MCT occurs rarely, with an incidence of 1-2% [2-4]. The chance of malignant transformation is more in peri-menopausal and post-menopausal patients. Previous studies have identified some risk factors for this malignant transformation especially squamous cell carcinoma; these factors include older age at presentation, tumor size and serum tumor markers. The frequency of malignant transformation increases with age, and is reported to be as high as 19% in postmenopausal patients [7-9]. Some studies suggest that patients age can be used as an indication for a higher suspicion of malignancy in patients with MCT, the mean age range being 45-60 years [10,11]. Kikkawa et al. [11] studied 37 cases of SCC arising from MCT in a 17-year period (1979-1996). Mean age of patients with SCC was 55.2 in contrast to 37.5 years in patients with benign MCT. Similarly in a case series by Bal et al. [12] the mean age was 46 years and the mean tumor size was 11.6 cm in five patients diagnosed with SCC arising in MCT in six years study duration. Dos Santos et al. [9] studied 17 cases of SCC arising in an MCT of the ovary during a 22 year period (1983-2005). The median age was 55 (mean, 54.8; range, 37-75 years) and mean tumor size was 14.2 cm. The mean age is 42.5 years in our study while the mean size of ovarian tumors is 13 cm (range 7-21 cm). This is a decade less than previous reports mainly because two patients were in second decade of life when diagnosed. But a Korean study showed a similar mean age (42.5 years) and a mean tumor size of 12.6 cm. MCT have mature elements derived from the three germ cell layers. Carcinomas can arise from any of the mature epithelial tissue present. Commonest malignant transformation reported is squamous cell carcinoma (80%) followed by adenocarcinoma, accounting for 6.8% [13]. In our study 26 cases (1.8%) showed malignant transformation, squamous cell carcinoma (20/26 cases) being the commonest (76.9%). The incidence of squamous cell carcinoma in the Korean study was very low (0.06%) which looked at 6260 cases of MCT [14]. Apart from squamous cell carcinoma other epithelial malignancies reported in MCT are basal cell carcinoma, sebaceous tumor, adenocarcinoma and neuroendocrine tumors [15]. In our series one case each of adenocarcinoma with mucinous differentiation, poorly differentiated carcinoma and adenosquamous carcinoma is present. Malignant component with endometrioid features and presence of atypical proliferative serous tumor most likely represent an example of collision tumor. Collision tumors involving the ovary are again a rare occurrence, and various combinations have been reported. Such tumors could arise either from 2 different cell lines growing at the same time or these originate from a common precursor pluripotent stem cell [16].

Among monodermal teratomas, struma ovarii is the commonest type, accounting for approximately 3% of all ovarian teratomas [11]. Commonest secondary malignancy reported within it is Papillary thyroid carcinoma (PTC) [17]. Our series include two cases of PTC (follicular variant) arising in struma ovarii.

SCC arising in MCT of the ovary has been associated with a very poor prognosis [10]. Age, tumor size, clinical stage, capsular invasion and the presence of vascular invasion can provide valuable information for predicting the prognosis.

Majority of deaths from SCC transformation in ovarian teratoma occur within a year of diagnosis [18,19]. In our series follow up was available in thirteen of the cases. Out of these eight were of squamous cell carcinoma transformation. Excluding case no 5, three patients had a stage 1A disease and all died within a year of diagnosis despite receiving radiotherapy and chemotherapy. Patients with stage IC and IIIC did not receive any additional treatment and also died within a year of diagnosis. Rest of the cases (malignancies with adeno-carcinomatous components) appears to have a more favorable prognosis. The challenge is to predict the risk of malignancy within MCT. Beside age and tumor size other reported factors that may raise a suspicion of malignancy within MCT are markers like squamous cell carcinoma (SCC) antigen, macrophage-colony stimulating factor (M-CSF) and carcino-embryonic antigen (CEA) [12]. These markers are reported to be better than CA-125 and CA-19-9 [17].

Raised pre-operative serum level of SCC antigen may require an early surgery. However, in our series SCC antigen levels are not available as the test is not available countrywide. In only two cases serum CA-125, β -hCG and AFP were performed out of which CA-125 was raised in both the cases. In the study by Choi et al., preoperative SCC antigen was elevated, suggesting malignancy and was helpful to decide surgery [14]. In our series malignant change was only suspected radiologically in three of the cases.

Conclusion

Malignant transformation in a MCT is a rare occurrence, squamous cell carcinoma being the most common which is also seen in our case series. Preoperative evaluation and diagnosis of malignant transformation within MCT is extremely difficult and challenging. Factors such as age of the patient, tumor size, and radiological characteristics may help in preoperative risk assessment however these are not specific therefore it is important to be aware of this possibility when cystic teratomas are encountered in a peri or postmenopausal women for proper management of the case.

References

- Kurman RJ, Ellenson LH, Ronnett BM (2011) *Blaustein's Pathology of the Female Genital Tract*: 6th edition. New York: Springer Verlag.
- Pins MR, Young RH, Daly WJ, Scully RE (1996) Primary squamous cell carcinoma of ovary. Report of 37 cases. *Am J Surg Pathol* 20: 823-833.
- Oranratanaphan S, Khemapech N (2013) Characteristics and treatment outcomes of patients with malignant transformation arising from mature cystic teratoma of the ovary: experience at a single institution. *Asian Pac J Cancer Prev* 14: 4693-4697.
- Sakuma M, Otsuki T, Yoshinaga K, Utsunomiya H, Nagase S, et al. (2010) Malignant Transformation Arising From Mature Cystic Teratoma of the Ovary. *Int J Gynecol Cancer* 20: 766-771.
- Curling ON, Potsides PN, Hudson CN (1979) Malignant change in benign cystic teratoma of the ovary. *Br J Obstet Gynaecol* 86: 399-402.
- Comerci JT Jr, Jones JG, Fields AL, Runowicz CD, Goldberg GL (1996) Squamous cell carcinoma in mature cystic teratoma in a young woman: a diagnostic and management dilemma. *Eur J Gynaecol Oncol* 17: 501-503.
- Suranagi VV, Malur PR (2009) Squamous Cell Carcinoma Arising From Mature Cystic Teratoma of Ovary. *Malur. JK Science: Journal of Medical Education and research* 11: 154-156.
- Peterson WF (1957) Malignant degeneration of benign cystic teratomas of the ovary. A collective review of the literature. *Obstet Gynecol Surv* 12: 793-830.
- Dos Santos L, Mok E, Iasonos A, Park K, Soslow RA, et al. (2007) Squamous cell carcinoma arising in mature Cystic teratoma of the ovary: A case series and review of the literature. *Gynecologic Oncology* 105: 321-324.
- Gordon A, Rosenheim N, Parmley T, Bhagavan B (1980) Benign cystic teratoma in postmenopausal women. *Am J Obstet Gynecol* 138: 1120-1123.
- Kikkawa F, Nawa A, Tamakoshi K, Ishikawa H, Kuzuya K, et al. (1998) Diagnosis of squamous cell carcinoma arising from mature cystic teratoma of ovary. *Cancer* 82: 2249-2255.
- Bal A, Mohan H, Singh SB, Sehgal A (2007) Malignant transformation in mature cystic teratoma of the ovary: report of five cases and review of the literature. *Arch Gynecol Obstet* 275: 179-182.
- Lee JM, Kim JW, Song JY (2008) Adenocarcinoma arising in mature cystic teratoma: a case report. *J Gynecol Oncol* 19: 199-201.
- Choi EJ, Koo YJ, Jeon JH, Kim TJ, Lee KH, et al. (2014) Clinical experience in ovarian squamous cell carcinoma arising from mature cystic teratoma: A rare entity. *Obstet Gynecol Sci* 57:274-280.
- Ulker V, Gedikbasi A, Numanoglu C, Ozluk Y, Saygi S, et al. (2009) Mucinous adenocarcinoma arising in ovarian mature cystic teratoma in pregnancy. *Arch Gynecol Obstet* 280: 287-291.
- Ahmed E, Shah SP, Adikesavalu K (2012) Unusual Collision Tumor of Ovary: Endometrioid adenocarcinoma and teratoma. *Clinical Ovarian & Other Gynecologic Cancer* 5: 33-36.
- Roth LM, Talerman A (2007) The enigma of struma ovarii. *Pathology* 39: 139-146.
- Ismail NAM, Rose IM, Mahdy ZA (2005) Bilateral Ovarian teratoma with squamous cell malignancy in a young woman: A diagnostic and management challenge. *Int Med J* 4: 51-53.
- Stamp GWH, Mc Connell EM (1983) Malignancy arising in cystic ovarian teratomas. A report of 24 cases. *Br J Obstet Gynaecol* 90: 671-675.