

Endoscopic Spine Surgery: Navigating the Learning Curve

Sohrab Gollogly^{1*} and Anthony Yeung²¹Department of Surgery, Monterey Spine and Joint Center, Monterey, California, USA²Department of General Orthopaedics and Endoscopic Spine Surgeons, Desert Institute for Spine Care, Phoenix, Arizona, USA

Abstract

Endoscopic spine surgery is emerging as an effective intervention for the minimally invasive treatment of symptomatic degenerative disease of the cervical and lumbar spine. There are an increasing number of sound indications for the use of endoscopic techniques, including, but not limited to: extruded and contained disc herniations, annular tears, facets cysts, central, lateral recess, and neuroforaminal stenosis. The same goals of safe and effective decompression of the neural elements with equivalent clinical results can be achieved endoscopically with less tissue disruption, less post-operative pain, and faster recovery than traditional open or microscopic approaches in the hands of well-trained surgeons. Navigating the learning curve is a critical part of the process of adopting endoscopic techniques. A thoughtful plan for the sequential acquisition of endoscopic skills and appropriately graduated technical difficulty of cases increases the likelihood of success.

Keywords: Neuroforaminal stenosis; Endoscopic treatment; Spinal stenosis; Disc herniations

Introduction

Endoscopic spine surgery has been routinely performed worldwide for nearly 30 years and there is an extensive body of peer reviewed literature that demonstrates clinical effectiveness [1-8]. The progression of surgical techniques for the treatment of spinal disease towards more effective, less invasive, and less costly care is influenced by academic, regulatory, financial, and consumer driven factors [9-11]. Inertia created by the current CPT based system for reimbursement for surgical services has delayed the development of endoscopic procedures for spinal surgery in the United States. This area of spine surgery has historically not seen the same investments in instrumentation, training, and techniques as other surgical subspecialties such as arthroscopic and laparoscopic surgery. The recent introduction of a CPT code for the reimbursement of endoscopic treatment of herniated discs and symptomatic spinal stenosis in the lumbar spine has resulted in an increased interest in this area of minimally invasive spine surgery. The appropriate standards for teaching endoscopic techniques in surgical training programs or adopting the same techniques into an established surgical practice have not been formally defined [12,13].

One of us i.e., Sohrab Gollogly, M.D. is a board-certified, fellowship trained spinal surgeon in active private practice with no endoscopic experience. The other i.e., Anthony Yeung, M.D. is an internationally recognized pioneer and master of endoscopic spinal surgery. We describe our experience navigating the learning curve together.

The pupil

After completing an orthopedic surgery residency and receiving fellowship training in adult and pediatric spinal deformity surgery I was in my 12th year of practice when I made the decision to investigate the applicability of endoscopic techniques. A primary motivation was personal experience with degenerative disease of my own cervical and lumbar spine. At age 39, I developed a broad based herniation at C5-C6 with a moderate to severe C6 radiculopathy. At age 45, I herniated a lumbar disc at the L2-L3 level that resulted in partial paralysis of my abdominal wall. Both herniations were severe enough to consider surgical intervention but appropriate physical therapy and non-operative management resulted in a completely satisfactory resolution of symptoms. This experience reinforced the fact that the natural history of untreated or minimally treated spinal disease is often more favorable than early intervention with fusion techniques. This is not to imply that an operation at either site may not be necessary in the future,

but we can all agree as surgeons that we serve our patients best when we delay or minimize our interventions until they are absolutely necessary. I sought to expand that part of my practice that allowed me to intervene in cases of symptomatic disc herniations and spinal stenosis with the minimal amount of tissue disruption, faster rehabilitation, and a more rapid return to work. After 12 years of practice in the same location, I also sought to learn techniques that were less likely to initiate a cycle of spinal surgery leading to adjacent segment disease leading to more spinal surgery.

I completed a thorough literature review but found the material published on Dr. Yeung's website and on his YouTube channel to be much more instructive in terms of beginning to appreciate the indications for endoscopic surgery, the appearance of normal and pathologic anatomy, and the range of possible techniques for decompression of the neural elements. To be perfectly honest, I also found it quite difficult to identify the same structures that I was intimately familiar with through the microscope. Identifying the ligamentum flavum, nerve roots, annulus, and disc material and recognizing their relationships to each other as seen through the spinal endoscope on Dr. Yeung's narrated surgical videos was challenging.

In January of 2017 I attended a day long endoscopic cadaver course held contemporaneously with the annual meeting of the International Society for Minimal Intervention in Spinal Surgery meeting in Chicago, IL. It was not until I had the opportunity to insert an endoscope through the far lateral approach into the intervertebral disc, standing at the side of a cadaver in exactly the same orientation that one would while performing surgery, that I began to appreciate the three-dimensional anatomy of the spine seen from this perspective.

Next, I wanted to identify an established endoscopic spinal surgeon who mentors me in the clinical application of these skills. I convinced Dr. Yeung to allow me to observe him in the clinic, injection suite, and operating room of his practice in Arizona. He was exceedingly

***Corresponding author:** Sohrab Gollogly, Minimally Invasive Spine Surgeon, Department of Surgery Monterey Spine and Joint Center, Monterey, California, USA, Tel: +8312779172, E-mail: sohrab.gollogly@gmail.com

Received July 21, 2018; **Accepted** August 08, 2018; **Published** August 13, 2018

Citation: Gollogly S, Yeung A (2018) Endoscopic Spine Surgery: Navigating the Learning Curve. J Spine S7: 010.doi:10.4172/2165-7939.S7-010

Copyright: © 2018 Gollogly S, et al. This is an open-access article distributed under the terms of the Creative Commons Attribution License, which permits unrestricted use, distribution, and reproduction in any medium, provided the original author and source are credited.

generous with his time. During the time that I spent with him I had the opportunity to observe the complete cycle of care from initial consultation, injection as necessary, endoscopic surgical procedure, and follow-up. We also had the opportunity to spend a significant amount of time discussing numerous “pearls and pitfalls” with a level of detail that is impossible to replicate in more public settings such as cadaver courses or instructional lectures.

I was already performing a significant percentage of my surgical operations in an outpatient surgical center in Monterey, California, so it was relatively easy to start performing oblique selective nerve root blocks and epidurograms on my own patients. I did these procedures in the same operating room, on the same operating table, in the same position, and using the same fluoroscopic equipment and technician, as I would normally use during a traditional open or microscopic discectomy. The oblique selective nerve root block and epidurogram technique, as taught by Dr. Yeung, gave me a new appreciation of the location and course of the nerve roots as they exit the spine and traverse the intervertebral disc (Figure 1). Performing these injections also gave me the confidence that I would be able to accurately establish the correct trajectory and positioning of the nitinol needle into Kambin’s triangle for the progressive dilation of the surgical approach to a herniated disc using the transforaminal technique.

After performing approximately 20 oblique selective nerve root blocks and epidurograms, I performed my first ever endoscopic spinal operation for a far lateral herniated disc using conscious sedation and local anesthesia (Figure 2 and Video 1). My initial indications were limited to far lateral and foraminal disc herniations since those are locations that can be difficult to access using a standard intra-laminar approach. Postero-lateral herniations are obviously significantly more common so after my first four successful procedures I expanded my indications to include broad based central protrusions in patients who were overweight. In my hands, this can be a difficult operation using an intra-laminar approach with co-morbid obesity and there are real and theoretical advantages of using a cannula to access the disc via a truly minimal incision and a far lateral approach where there is minimal

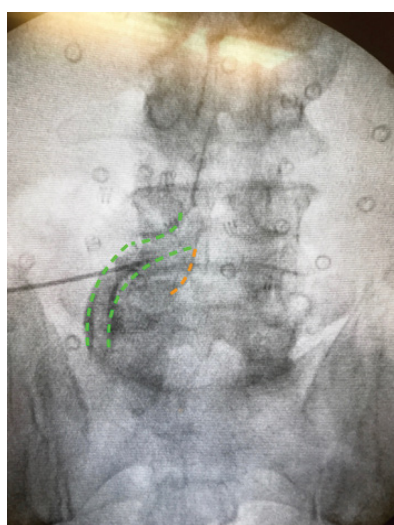


Figure 1: An AP view of an oblique selective nerve root block performed for diagnostic and therapeutic purposes at the L4-L5 level. The path of the exiting L4 nerve root is outlined in orange and the path of the traversing L5 nerve root is outlined in green. Performing these procedures gave one of us (S.G.) a new appreciation of the path of these anatomic structures in relationship to foraminal and postern-lateral disc herniations.

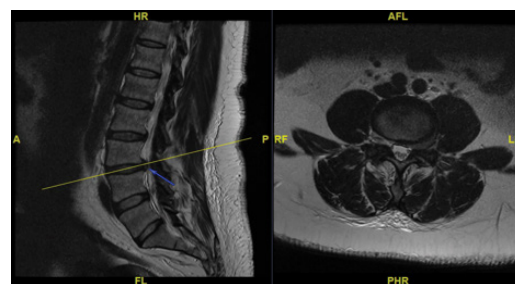
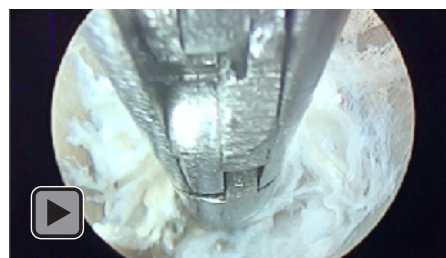


Figure 2: A far lateral disc herniation on the left side at the L3-L4 level. This is an ideal initial case for a transforaminal far lateral endoscopic discectomy.



Video 1: The view through the cannula of the endoscopic removal of the herniated portion of the disc seen in Figure 2.

disruption of the subcutaneous and muscular tissues, no dead space, and minimal damage to the tension-bearing posterior aspects of the annulus fibrosis.

Finally, after approximately 15 far-lateral, foraminal, or central contained herniations, I expanded my indications to include selected recurrent disc herniations after prior open discectomy, and some select free fragment herniations (Figure 3 and Videos 2 and 3).

Over the course of the next 12 months, I performed 55 endoscopic spinal operations for herniated discs and degenerative disease of the lumbar spine. Early results have been very encouraging. In this cohort of patients there have been two symptomatic recurrences requiring re-operation, no hospital transfers or admissions within 5 days of the index procedure, no infections, and a very high degree of patient satisfaction. This initial cohort of cases has resulted in recognition of the anatomic landmarks as seen from the transforaminal approach (Figure 4), an understanding of the relative indications for this approach over other forms of treatment of disc disease, and have created a foundation for consideration of other forms of endoscopic surgery such as intra-laminar decompression, decompression for bony stenosis, and potentially cervical applications.

Concomitantly with introducing endoscopic spinal procedures into my practice I also developed a protocol for reducing the amount of opiate pain medications my patients were given for post-operative pain for both endoscopic and minimally invasive surgery in the ambulatory surgery center setting. Using a combination of 500 mg of Tylenol + 200 mg of Ibuprofen every 6 hours and 5 mg of Oxycodone or 10 mg of cyclobenzaprine PRN pain or muscle spasms, substantial reductions in the number of opiate table prescribed were seen (Table 1, Pie Diagrams 1-4). This pattern of post-operative pain medication consumptions represents a significant change towards less opiate use in comparison with my personal experience performing traditional open spine surgery in an inpatient setting.

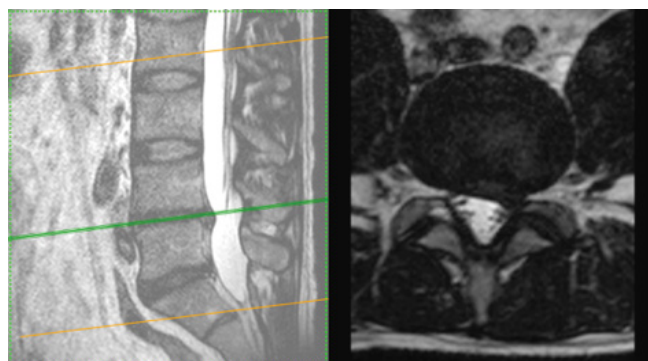
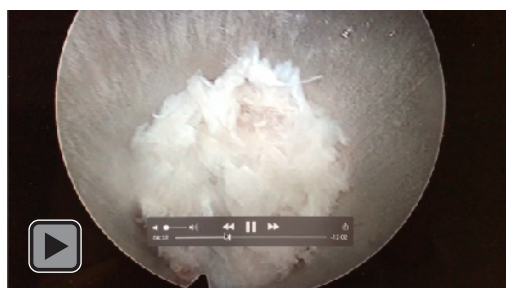
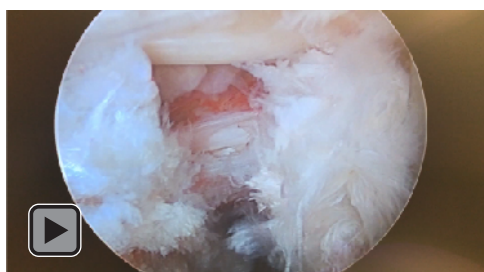


Figure 3: A paracentral/lateral recess disc herniation on the left side at the L4/L5 level. This disc herniation was found to be an extruded free fragment which was successfully retrieved from the dural side of the posterior longitudinal ligament using a transforaminal approach.



Video 2: The view through the cannula of the endoscopic removal of the herniated portion of the disc seen in Figure 3.



Video 3: Completed decompression of the L4-L5 disc as seen from the right transforaminal approach.

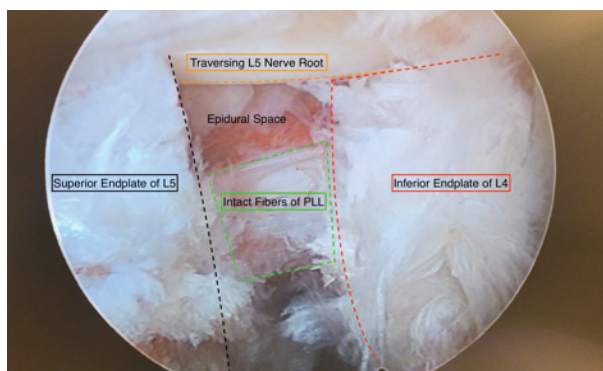
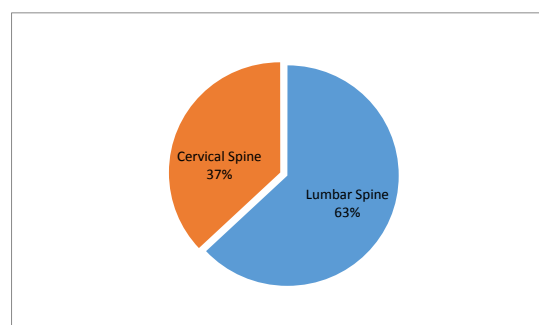


Figure 4: The transforaminal view of a completed decompression as seen from the transforaminal approach to the right L4-L5 disc space.

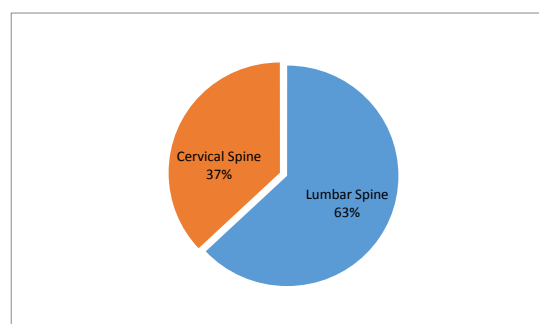
Type of Surgery	% of Total Cases
Lumbar Spine	63
Cervical Spine	37
For how many days did you take Tylenol + Ibuprofen?	% of Patients
1-3 days	17
3-5 days	24
5-7 days	43
1 week +	16
How many oxycodone tablets did you Take after surgery?	% of Patients
None	26
less than 5	40
5 - 10	20
10 +	16
Compared to other operations that you Have had, was this plan for pain control Better, the same, or worse?	% of Patients
Better	57
The Same	29
Worse	14

Patient reported use of post-operative pain medications 14 days after minimally invasive spine surgery using a regime of 500 mg of Tylenol + 200 mg of Ibuprofen scheduled every 6 hours and 5 mg of oxycodone or 10 mg of cyclobenzaprine PRN pain or muscle spasm.

Table 1: The pattern of post-operative pain medication consumptions.



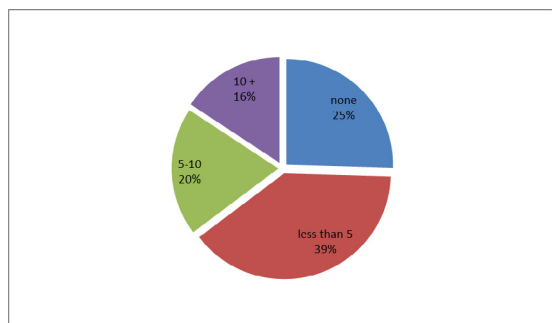
Pie Diagram 1: Diagram representing the type of surgery and the % of total cases.



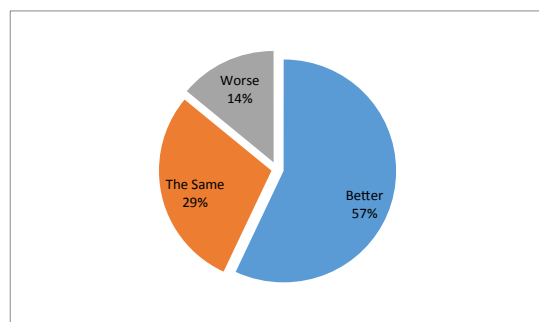
Pie Diagram 2: Diagram representing for how many days did the patient take Tylenol + Ibuprofen and the % of patients.

The master

Dr. Anthony Yeung has performed more than 10,000 endoscopic spinal operations over the last 27 years and has become a voice of experience and authority on the role of endoscopy in the management of symptomatic spinal disease [14-20]. Over the course of his career, he



Pie Diagram 3: Diagram representing how many oxycodone tablets did you take after surgery and the % of patients.



Pie Diagram 4: Diagram representing the comparison to other operations that had this plan for pain control better, the same, or worse and the % of patients.

has been an active participant in the development and dissemination of endoscopic techniques. Dr. Yeung's philosophy of minimally invasive spine surgery posits that the surgeon appreciates the importance of the following four principles:

1. The patho-physiology of neurological pain and neurogenic claudication must be understood.
2. This understanding must be correlated with the ability to identify the anatomic structures responsible for pain and dysfunction.
3. A staged approach to therapeutic interventions should be utilized, beginning with the least invasive treatment options
4. Extensive salvage procedures, such as fusion, should be utilized as the last resort for the management of pain, except in the presence of gross instability or deformity.

Discussion

Dr. Yeung has instructed and mentored hundreds of aspiring surgeons and, through personal experience, has reservations about the ability of aspiring surgeons to understand these principles completely and learn new surgical techniques in the course of relatively short surgical workshops. He has been a life-long advocate of cadaveric dissection and anatomic study, graduated application of surgical techniques to appropriate selected patients, participation in professional societies, and mentoring relationships. In a recent publication he summarized the current state of affairs regarding the adoption of endoscopic techniques and advanced 3 proposals for the responsible credentialing of endoscopic spine surgeons:

1. Endoscopic spine surgeons must accrue technical and clinical expertise in training programs of adequate breadth and quality.

2. Endoscopic spine surgeons must demonstrate technical proficiency and expertise standardized and reviewed by peers.
3. Endoscopic spine surgeons must be able to manage potentially harmful complications, or have a relationship with a system of providers that will assist in the management of such complications.

At the moment, there is no clear consensus on the appropriate qualifications and mechanisms for demonstrating competence in the field of endoscopic spinal surgery. At every institution offering endoscopic procedures, the medical staff must craft their own standards. As professional interest in this subspecialty grows, we anticipate that there may be some controversy who can be credentialed to perform these procedures and after what type of training. In the absence of formal mechanisms for credentialing spine surgeons to perform endoscopic spinal surgery, Dr. Yeung advocates for a cautious, thoughtful, and methodical study of these techniques.

Conclusion

Endoscopic spinal surgery may represent the next major frontier in the management of symptomatic spinal disease. The combination of an aging population, the recognition that minimally invasive endoscopic techniques can offer significant advantages in terms of less surgical morbidity and complications, and the recent introduction of a CPT code for reimbursement, may represent an inflection point in the curve of adoption of these procedures. Philosophical and technical details unique to this approach to spinal disease mandate a thoughtful approach to learning these procedures and applying them in clinical practice. Until formal standards for credentialing endoscopic spine surgeons are established, we encourage the development of strong relationships with professional societies, peers, and mentors.

References

1. Choi G, Pophale CS, Patel B, Uniyal P (2017) Endoscopic Spine Surgery. J Korean Neurosurg Soc 60: 485-497.
2. Yeung AT (2017) Transforaminal endoscopic decompression for painful degenerative conditions of the lumbar spine: A review of one surgeon's experience with over 10,000 cases since 1991. J Spine Neurosurg 6: 266.
3. Yeung AT (2018) The Yeung Percutaneous Endoscopic Lumbar Decompressive Technique (YESSTM). J Spine 7: 408.
4. Yeung AT, Kotheeranurak V (2018) Transforaminal endoscopic decompression of the lumbar spine for stable degenerative spondylolisthesis as the least invasive surgical treatment using the YESS surgery technique. J Spine 7: 407.
5. Yeung AT (2017) In-vivo endoscopic visualization of pain generators in the lumbar spine. J Spine 6: 385.
6. Komp M, Hahn P, Oezdemir S, Giannakopoulos A, Heikenfeld R, et al. (2015) Bilateral spinal decompression of lumbar central stenosis with the full-endoscopic interlaminar versus microsurgical laminotomy technique: a prospective, randomized, controlled study. Pain Physician 18: 61-70.
7. Birkenmaier C, Komp M, Leu HF, Wegener B, Ruetten S (2013) The current state of endoscopic disc surgery: review of controlled studies comparing full-endoscopic procedures for disc herniations to standard procedures. Pain Physician 16: 335-344.
8. Ruetten S, Komp M, Merk H, Godolias G (2008) Full-endoscopic interlaminar and transforaminal lumbar discectomy versus conventional microsurgical technique: a prospective, randomized, controlled study. Spine (Phila Pa 1976). 33: 931-939.
9. Belatti DA, Phisitkul P (2013) Trends in orthopedics: an analysis of Medicare claims, 2000-2010. Orthopedics 36: e366-e372.
10. Pannell WC, Savin DD, Scott TP, Wang JC, Daubs MD (2015) Trends in the surgical treatment of lumbar spine disease in the United States. Spine J 15: 1719-1727.

11. Morgenstern R, Morgenstern C, Yeung AT (2007) The learning curve in foraminal endoscopic discectomy: experience needed to achieve a 90% success rate. SAS J 1: 100-107.
12. Meyers JE, Wang J, Khan A, Davies JM, Pollina J (2018) Trends in Physician Reimbursement for Spinal Procedures Since 2010. Spine (Phila Pa 1976 43: 1074-1079.
13. Huang TJ, Kim KT, Nakamura H, Yeung AT, Zeng J (2017) The State of the Art in Minimally Invasive Spine Surgery. Biomed Res Int 1-4.
14. Yeung A, Yeung CA (2017) Endoscopic identification and treating the pain generators in the lumbar spine that escape detection by traditional imaging studies. J Spine 6: 369.
15. Yeung AT, Yeung CA, Salari N, Field J, Navratil J, et al. (2017) Lessons learned using local anesthesia for minimally invasive endoscopic spine surgery. J Spine 6:377.
16. Yeung AT (2017) Endoscopic decompression for degenerative and isthmic spondylolisthesis. J Neurol Disord 5: 371.
17. Yeung AT (2017) The role of endoscopic surgery in the treatment of conditions of an aging spine: State of the Art. J Neurol Disord 5: 372.
18. Yeung AT (2006) Selective endoscopic discectomy: twelve years' experience" in Kambin P (ed) Atlas of Arthroscopic and Endoscopic Spinal Surgery, Text and Atlas, (2nd edn), Humana Press, Inc., Totowa, NJ, USA.
19. Yeung AT, Yeung CA, Zheng Y (2010) Endoscopic decompression, ablation and irrigation: A minimally invasive surgical technique for painful degenerative conditions of the lumbar spine. Cosar, Khoo (eds). J Spine Neurosurg 5: 3.
20. Gore S, Yeung AT (2014) The "inside out" transforaminal technique to treat lumbar spinal pain in an awake and aware patient under local anesthesia: Results and a review of the literature. Int J Spine Surg 8: 28.

This article was originally published in a special issue, [Minimally Invasive Spine Surgery -II](#) handled by Editor(s). Anthony T. Yeung, M.D. Clinical professor, University of New Mexico School of Medicine Associate Desert Institute for Spine Care, Phoenix, Arizona, Executive director International Intradiscal therapy Society Phoenix, Arizona