

## Endoscopic Extraction of an Anchored Chest/Mediastinal Tube

Rubchevsky Victor, Kabaha Majed, Yaron D Barac\* and Aravot Dan

Department of Cardiothoracic Surgery, Rabin Medical Center, Petah Tikva, Israel

### Abstract

Cardiac wound bed drainage is achieved via large-bore plastic tube(s), which are typically removed within 48 hours, to lower risk of arrhythmia and tissue damage. While standard tube removal is simple and rapid, tubes inadvertently sutured to the chest wall are removed through a complex surgical procedure. Herein, we describe a novel tube extraction procedure, using an endoscopic scissor under bronchoscopic guidance. Tube extraction was achieved in all three presented cases, and patient recovery and wound healing periods were similar to those standard removal of nonsutured tubes. This report demonstrates the safety and convenience of the proposed method as a feasible alternative to invasive chest tube extraction.

**Keywords:** Cardiac surgery; Endoscopic technique; Chest tube; Mediastinitis

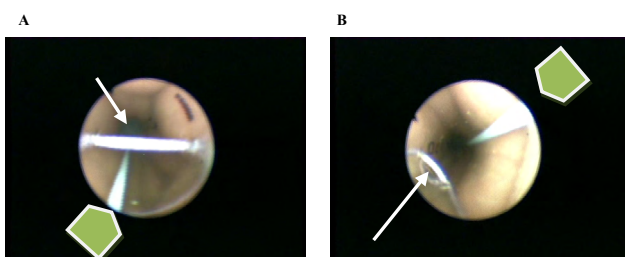
### Introduction

One or more large-bore plastic tubes are usually introduced to the pericardial space after open cardiac procedures, to facilitate wound bed drainage of blood, fluid and air that accumulates in either the mediastinum or the pleural space and to prevent tamponade and pneumothorax. However, use of these large, stiff tubes is painful and may result in hypoventilation, atelectasis, and heightened use of analgesic agents. These tubes can also impinge on the heart, particularly as the patient becomes more active, increasing risk of arrhythmias and damage of coronary grafts or adjacent structures. Therefore, the drains are usually removed within 48 hours, after confirming minimal fluid drainage and absence of air leaks. While the tube removal technique is well-established, usually performed by junior residents, it can be complex, especially following inadvertent tube suturing to the chest wall during chest closure. In such cases, forceful removal may result in tube rupture and retention or in organ/tissue damage. To date, fixed tubes are removed via surgical procedures. In order to prevent the need to open the surgical site, we present a novel endoscopic method for chest tube extraction, requiring a bronchoscope and endoscopic scissors. The minimally invasive technique, performed thus far in three patients, provides a cost effective means of releasing sutured chest tubes, while avoiding surgical intervention and the challenges and risks of the associated convalescence period.

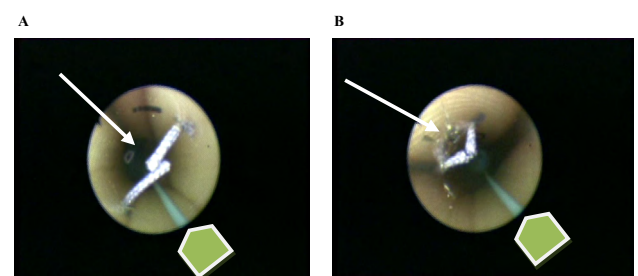
### Case Report

All anchored tubes were Biometrix plastic tubes ranging from 28-32 Fr; all tubes contained a radiopaque line for better visualization by

X-ray. A standard bronchoscope (Karl Storz Ø 4.5 mm) was introduced through the lumen of the tube of patients #1 and #2, to locate the position of the securing thread, its distance from the external tip of the tube, and its position in relation to the radiopaque line (Figure 1). It should be noted that the endoscopic scissors and the bronchoscope cannot be simultaneously inserted into the tube, due to the narrow tube diameter. The bronchoscope was then removed and the endoscopic scissors (ENDO SHEARS 5 mm, Tyco) were inserted and directed to the determined depth and position of the thread. The thread was then blindly cut. Following scissor extraction, the bronchoscope was inserted again to confirm proper execution of the cutting step (Figure 2). The tubes were then extracted as usual, as previously described [1]. A third patient presented a mediastinal tube trapped within the two sternum edges, as identified by the bronchoscope. In this case, the procedure was performed with the addition of delicate sedation and application of extra tension while extracting the tube [2,3]. Patient recovery and



**Figure 1: Position of the securing thread.** The arrows point to the thread and the arrow heads depict the radiopaque line. (A) Patient #1: the thread traversed the tube lumen. (B) Patient #2: the thread secured the tube to the left side of the lumen.



**Figure 2: Thread position following endoscope-guided cutting.** The arrows point to the cut thread and the arrow heads depict the radiopaque line. (A) Patient #1: the severed thread was detected at the midline of the tube lumen. (B) Patient #2: the severed thread was detected on the left border of the tube lumen.

\*Corresponding author: Yaron D. Barac, Department of Cardiothoracic Surgery, Rabin Medical Center, Petah Tikva, Israel, Tel: 972 39376701; E-mail: [byaron@tx.technion.ac.il](mailto:byaron@tx.technion.ac.il)

Received July 08, 2013; Accepted November 01, 2013; Published November 07, 2013

Citation: Victor R, Majed K, Barac YD, Dan A (2013) Endoscopic Extraction of an Anchored Chest/Mediastinal Tube. J Gen Pract 1: 132. doi: [10.4172/2329-9126.1000132](https://doi.org/10.4172/2329-9126.1000132)

Copyright: © 2013 Victor R, et al. This is an open-access article distributed under the terms of the Creative Commons Attribution License, which permits unrestricted use, distribution, and reproduction in any medium, provided the original author and source are credited.

wound healing periods were similar to those of patients undergoing standard removal of nonsutured tubes; patients were discharged, as expected, five days post-operation.

## Discussion

Cardiac surgeries harbor numerous complications, each independently impacting patient morbidity and mortality and each demanding solutions of varying complexities. Erroneous suture of chest or mediastinal tubes to the wound bed is a known complication, typically conservatively managed to avoid graft laceration [4]. However, reopening of the chest wound or even the sternum bears a substantial risk of wound infection or sternal dehiscence and increased risk of mediastinitis [5].

## Conclusion

The proposed technique is safe and convenient and provides an alternative to invasive reoperation, by exploiting endoscopic tools and internal landmarks for identification of thread location. While

providing a significantly less invasive, cost effective approach, which fully avoids infliction of a transthoracic wound, one might of course argue that this method introduces risk of potential heart or lung damage as a result of blind cutting. However, future developments of smaller devices are expected to allow for simultaneous viewing and cutting, thereby mitigating the risk mentioned above.

## References

1. Kinney MR, Kirchoff KT, Puntillo KA (1995) Chest tube removal practices in critical care units in the United States. *Am J Crit Care* 4: 419-424.
2. Gift AG, Bolgiano CS, Cunningham J (1991) Sensations during chest tube removal. *Heart Lung* 20: 131-137.
3. Carson MM, Barton DM, Morrison CC, Tribble CG (1994) Managing pain during mediastinal chest tube removal. *Heart Lung* 23: 500-505.
4. Sulimovic S, Noyez L (2006) Postoperative myocardial ischemia caused by compression of a coronary artery by chest tube. *J Cardiovasc Surg (Torino)* 47: 371-372.
5. Serry C, Bleck PC, Javid H, Hunter JA, Goldin MD, et al. (1980) Sternal wound complications. Management and results. *J Thorac Cardiovasc Surg* 80: 861-867.