

## Endoscopic Decompression for Degenerative and Isthmic Spondylolisthesis

Anthony T Yeung<sup>1,2,3\*</sup>

<sup>1</sup>University of New Mexico School of Medicine, Albuquerque, New Mexico, USA

<sup>2</sup>Society of International Intradiscal and Transforaminal Therapy, Phoenix, Arizona, USA

<sup>3</sup>Desert Institute for Spine Care, Phoenix, Arizona, USA

### Abstract

Current surgical philosophy by traditionally trained spinal surgeons focuses on decompression with or without fusion as the “ultimate cure” for a painful spinal segment. Endoscopic surgery—the least invasive of current minimally invasive surgical options—focuses on treating the patho-anatomy of the pain generator. Spondylolisthesis is traditionally represented as a “gold standard” for fusion, but with minimally invasive techniques evolving, there is a new path between traditional open decompression and fusion that offers an alternative. A review of a database of patients who refused fusion, but opting to an endoscopic decompression with sciatica, even in the face of back pain determined that transforaminal decompression for a disc herniation or foraminal stenosis is effective in some patients and result in a decrease in the need for fusion.

The endoscopic transforaminal decompression technique is discussed as a stand-alone or staged procedure that may reduce the number of surgical fusions in the face of degenerative and isthmic spondylolisthesis. When combined with surgical rhizotomy for low back pain, this hybrid procedure includes rhizolysis for posterior column back pain, may offer a cost-effective method for treating common debilitating chronic low back pain.

**Keywords:** Isthmic spondylolisthesis; Fusion techniques; Endoscopic decompression; Degenerative; Spine

### Introduction

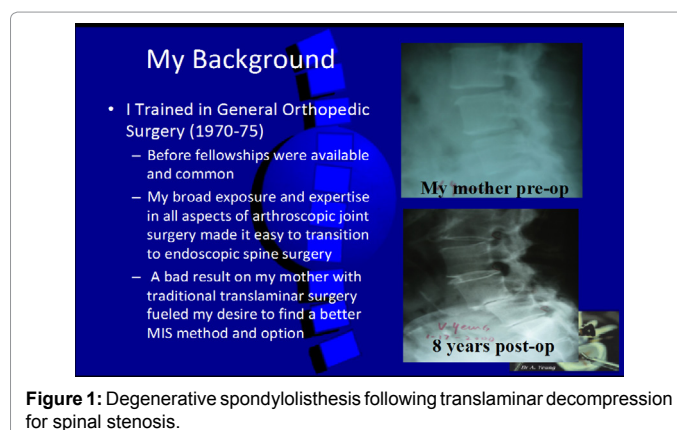
Chronic low back pain, whether affecting lifestyle or considered debilitating, will afflict most people in their lifetime due to disc degeneration from trauma or from events from the normal aging process. Recent clinical studies demonstrate that imaging studies detecting disc degeneration even in asymptomatic patients will eventually result in the development of low back pain severe enough for patients to seek medical and surgical treatment [1]. Degenerative Conditions in an aging spine is well documented in Cadaver cryosections by Wolfgang Rauschnig and a degenerative cascade described by Pfirrmann. It is also recognized that lower back and neck pain is 3rd only after #1 diabetes, and essentially tied with ischemic heart disease, listed as #2, in the top 5 common health condition expenditures according to an analysis published by JAMA in 2013.

### Fusion

Fusion has also evolved throughout its modern history, with new concepts changing every few years since the pedicle screw revolution that promotes instrumented stabilization for spondylolisthesis. Multiple minimally invasive fusion implants and techniques have emerged in the past 10 years, fuelled and supported by surgeons and industry, creating an explosion of surgical procedures over the past 10 years. Current emphasis is now also on attaining sagittal alignment and balance, another phase in the evolution of fusion techniques. Now, with the advent of MIS decompression techniques, some key opinion leaders among spine surgeons are recognizing that not all patients require instrumented fusion. Endoscopic decompression, whether translaminar or transforaminal (the least invasive) will eventually lead the way for staging procedures and offering the patient more treatment choices. Of the endoscopic techniques, the transforaminal approach is the least invasive (Figure 1).

### Discussion

The cost of health care and spine care specifically, is contributing to the escalation and affordability of health care costs. Payment by government and insurance payers is also increasingly governed by



**Figure 1:** Degenerative spondylolisthesis following translaminar decompression for spinal stenosis.

guidelines developed by payers and stakeholders. Reimbursement, focusing on validation by evidenced-based medicine (EBM) before payment is approved, may have to be re-evaluated. Each stakeholder must consider the rationale and cost of health care delivery with a consideration of affordability. Spondylolisthesis is a spinal condition where 10-15 years ago, fusion was accepted as a “gold standard” for surgical stabilization. Patients who underwent traditional translaminar decompression with removal of the medial 1/3 of the posterior facet for stenosis were observed to develop back pain from

**\*Corresponding author:** Anthony T. Yeung, Voluntary Professor, University of New Mexico School of Medicine, Albuquerque, New Mexico, Executive Director, Society of International Intradiscal and Transforaminal Therapy, Phoenix, Arizona and Associate Desert Institute for Spine Care, Phoenix, Arizona, USA, Tel: +1 602-944-2900; E-mail: [ayeung@sciatica.com](mailto:ayeung@sciatica.com)

**Received** December 13, 2017; **Accepted** December 26, 2017; **Published** December 29, 2017

**Citation:** Yeung AT (2017) Endoscopic Decompression for Degenerative and Isthmic Spondylolisthesis. J Neurol Disord 5: 371. doi:10.4172/2329-6895.1000371

**Copyright:** © 2017 Yeung AT. This is an open-access article distributed under the terms of the Creative Commons Attribution License, which permits unrestricted use, distribution, and reproduction in any medium, provided the original author and source are credited.

lumbar spondylosis and facet arthrosis as part of the post-operative or aging process. In some patients, degeneration resulted in deterioration to a grade 1-2 spondylolisthesis. The rationale that spondylolisthesis was a result of instability because of surgical decompression or aging, created a surgical thought process that fusion for instability should be a part of any primary or revision surgery. This may be further validation confirmed by flexion/ extension x-rays or imaging software documenting instability to warrant fusion as part of the surgical procedure. Fusion surgery was then supplanted by various dynamic stabilization schemes ranging from pedicle based versus interspinous-based dynamic stabilization. With over 20 years' experience-treating patients who sought endoscopic decompression to avoid the "dreaded" fusion recommended by spine surgeons, a personal database of my patients who refused fusion by opting for endoscopic decompression first, were reviewed. This resulted in the publication of a series of opinion based level 4 and 5 EBM articles in open access Journals dating back to December 2015. A review of the benefits of transforaminal endoscopic decompression as the least invasive surgical procedure in the lumbar spine demonstrated great patient satisfaction from patients who elected to avoid fusion.

My first article, moving away from fusion, was published on Dec 2, 2015 in the Journal of Spine. A review of 58 patients with degenerative and isthmic spondylolisthesis from 2003 to 2013 was studied. No statistical analysis was performed nor powered for this study, but trends from the review were noted from my returning patients who maintained contact or who returned with minor symptoms seeking further surgical advice. These patients were instructed to notify me if their spinal condition worsened after discharge. Their satisfaction of the index surgery universally expressed in follow-up visits stimulated my interest in following these patients more formally. 58 patients with 10-year follow-up were surveyed. The patients included high performance athletes and spine surgeons who maintained contact after they sought a less invasive endoscopic decompression procedure over fusion, the "gold standard" for spondylolisthesis at the time. Some of the patients were featured on my practice website as patient case reports or patient testimonials, and their surgeries were featured on playlists of spondylolisthesis and placed on you tube. From my review of the 58 patients with a 5-10 year follow up, the life time analysis found that approximately 36% avoided additional surgery and 100% was satisfied with their decision to delay fusion as their first surgical option (Figure 2).

In the past 5 years, I continued stratification of patient selection from my evolving endoscopic surgery technique, aided by new instrumentation and decompressive techniques that surgically facilitated decompression utilizing my "inside out" intradiscal therapy

philosophy and transforaminal decompression methods. I identified those patients most likely to benefit from endoscopic transforaminal decompression, even with degenerative spondylolisthesis. Patients with isthmic spondylolisthesis were more reluctantly offered foraminal decompression when their main complaint was sciatica. These carefully selective patients also responded with favorable clinical results. Further stratification through favorable response to pre-operative transforaminal epidural blocks performed by myself, (ATY), helped define patients who could expect at least reasonable intermediate term results when the patients chose endoscopic decompression first, as a "staged procedure".

If a patient returned with worsening pain, they were referred considered candidates for fusion. The patients who opted for staged fusion were still relatively young, working, or had active lifestyles that they did not want to curtail. All were satisfied with their original decision to avoid fusion and even if their the back pain was still present, but decreased enough when they were satisfied to curtail their physical activity level.

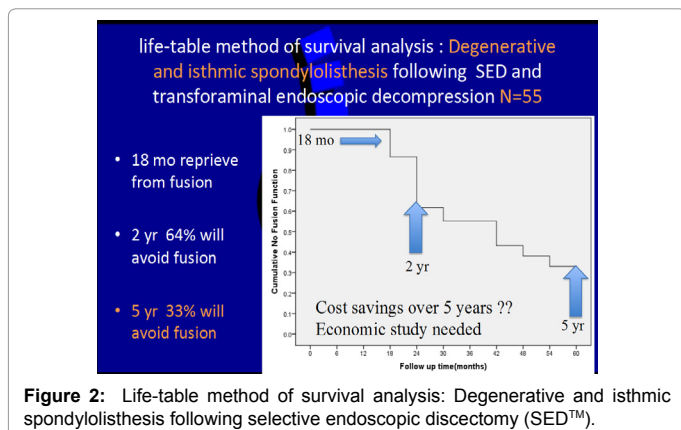
The lessons learned by foraminal endoscopic decompression and endoscopic rhizolysis in the past 27 years are as follows:

- The horizontal sagittal alignment of the facet at the level of the index surgery was helpful in predicting further slippage following endoscopic decompression.
- Endoscopic transforaminal decompression did not cause additional slippage.
- Patients with a favorable response to transforaminal epidural.
- Blocks performed by an experienced endoscopic surgeon predicted a favorable response to transforaminal endoscopic decompression.
- Foraminal Endoscopic Decompression did not result in further slippage, especially if the sagittal alignment of the facet was more horizontal than vertical.
- Patients over 65, who were laborers and who had retired from their day job responded better than younger active patient who were still working, but none regretted to have their surgery staged.
- If back pain represented 30-50% of their pain complaint, a hybrid procedure that included dorsal endoscopic rhizotomy relieved back pain as well.

## Health care reforms

Health care reform in the United States is focused on providing universal health care for all citizens, but it must be affordable. Government and insurance payers want to seek the most effective treatment for a reasonable cost. To accomplish the goals of offering universal health care to all citizens, the reimbursement must be adequate for all providers to be appropriately paid or re-imbursed and at the same time be most cost efficient and deliver care in a rational and cost-effective manner.

The cost of back care, the third most costly condition second only to diabetes and ischemic heart disease is 10 times most expensive to treat in the US compared to Asian countries such as China where the cost expenditures are approximately 1/10 of that in the USA. If a focus on treating the patho-physiology and patho-anatomy of back pain in a staged manner, the cost of health care can be effectively curtailed while allowing continued innovation and development based on cost and value, much like how consumer products are marketed and warranted. Our ability to respond to the individual pain needs of our patients



will help facilitate cost containment. This will encourage innovation by preserving physician autonomy with incentive to develop new treatment through clinical and basic science research. This will allow physicians autonomy to treat patients for their individual needs with minimal interference from payers and regulators.

## Conclusion

Clinical research can still be validated with traditional level 4 and 5 EBM methods of validation as long as they are also peer reviewed by qualified reviewers [1-5]. The treatment algorithm in spine is evolving and changing due to a better understanding of the patho-anatomy, well correlated with its pathophysiology. I have written about my own evolving technique in publications including a series of articles in Surgical Technology International.

## References

1. Samartis D (2010) Disc degeneration in asymptomatic patients increases risk of low: Back pain, a prospectively assessment of Southern Chinese.
2. Yeung AT, Gore S (2012) *In-vivo* endoscopic visualization of patho-anatomy in symptomatic degenerative conditions of the lumbar spine II: Intradiscal, foraminal, and central canal decompression. Surg Technol Int 21: 299-319.
3. Yeung AT (1999) Various articles (1991-2011) Surg Tech Int; VIII, XI, XV, XXI editions.
4. Yeung AT, Gore SR (2014) Evolving methodology in treating discogenic back pain by Selective Endoscopic Discectomy (SED) and thermal annuloplasty. J Minim Invasive Spine Surg Tech 1: 8-16.
5. Gore SR, Yeung AT (2003) Identifying sources of discogenic pain. J Minim Invasive Spine Surg Tech 3: 21-24.