

Empyema Caused by *Streptococcus Constellatus*: Atypical Presentation of a Typical Pneumonia

Merlán Hermida Alejandro* and Perdomo Pérez Laura

Department of Internal Medicine, Hospital Universitario de Gran Canaria Doctor Negrín, Spain

Abstract

A 27-year-old man, with no known diseases, was admitted to our hospital with respiratory insufficiency and sepsis after 21 days of low-grade fever and non-productive cough without any other symptoms. He was diagnosed with fever of intermediate duration and doxycycline was initiated. An X-ray showed severe pleural effusion and a right lower lobe atelectasis. A pleural effusion sample study revealed an empyema, and an emergent thoracic tube was placed. Five days of empyema sample culture did not show pathological findings; thus, we performed a time-extended culture. After 8 days, *Streptococcus constellatus* was isolated. We completed 10 days of intravenous empiric treatment followed by oral cephalosporin. The patient required two thoracic drainages; there were no complications. He was completely asymptomatic 3 months after discharge. This report summarises the importance of oral microbiota as pathogens involved in community-acquired pneumonia among healthy young people and the atypical presentation of a typical complicated pneumonia.

Keywords: *Streptococcus constellatus*; Empyema; Pneumonia; *Streptococcus anginosus* group

Introduction

Streptococcus constellatus (SC) empyema is a clinical entity that has been specifically described in the scientific literature in very few studies and with few patients. However, the *Streptococcus anginosus* group (SAG) is one of the most frequently isolated in community-acquired empyemas. In the vast majority of reported cases, it has a typical course and is related to the elderly population specially with prior endoscopic or bronchoscopic manipulation and particularly in those with underlying diseases predisposing them to bronchoaspiration.

Case Presentation

We present a 27-year-old man with no underlying diseases, who was admitted to our hospital with respiratory insufficiency and sepsis. Three weeks earlier, his symptoms began with low-grade fever, asthaenia and a non-productive cough. One week after onset, he went to the emergency department suffering from sudden right pleuritic pain and dyspnoea. He presented tachycardia and fever. An urgent blood test and a chest X-ray did not reveal pathological findings; therefore, he was discharged with analgesic treatment.

One week before admission, during his evaluation as an outpatient, he had reported experiencing asthaenia, weight loss, low-grade fever and persistent dry cough. In the anamnesis he reported a non-infectious dental surgery 2 month before the onset of the symptoms.

Results

An urgent blood test was performed, including blood count, renal and hepatic function and markers of inflammation, highlighting only a C-reactive protein of 62.7 mg/dL. Blood cultures and serology testing for intermediate-duration fever (*Coxiella burnetii*, *Rickettsia typhi*, *Mycoplasma pneumoniae*, *Leptospira*, *Treponema pallidum*, human immunodeficiency virus, hepatitis B virus, hepatitis C virus, Epstein-Barr virus and cytomegalovirus) were obtained, and doxycycline treatment was empirically initiated.

After 72 hours, the patient experienced clinical decline with asthaenia, fever, irritating cough, pleuritic pain and haemoptysis; thus, he went to the emergency department. He was pale, diaphoretic and tachycardic (145 bpm). His SatO₂ was 93%, respiratory rate 24 rpm, temperature 39.1°C and there was an abolition of right basal respiratory

sounds. Blood test showed leukocytosis (18,000 leukocytes/uL) with neutrophilia, consumption coagulopathy (IQ 47%) and procalcitonin 0.65 ng/mL. On the chest X-ray (Figure 1), there was a condensation and right basal atelectasis associated with pleural effusion in relation to complicated pneumonia. The patient was transferred to a critical care unit. He needed no vasoactive support or mechanical ventilation.

The pleural effusion biochemistry revealed pH 6.87, 18,058 cells/uL, 70% polymorphonuclear neutrophils, glucose 1 mg/dL, proteins 4.5 g/dL, lactate dehydrogenase 8630 U/L and adenosine deaminase 149.8 U/L. Ceftriaxone plus azithromycin were initiated. The patient required urokinase and pleural drainage twice, obtaining 1700 cc and 2400 cc, respectively. Blood cultures, *Legionella* and *S. pneumoniae* antigen, polymerase chain reaction for mycobacteria and Mantoux

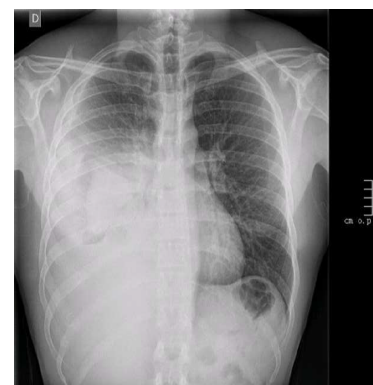


Figure 1: Chest X-ray showing right lower lobe pneumonia with severe empyema.

*Corresponding author: Merlán Hermida Alejandro, Department of Internal Medicine, Hospital Universitario de Gran Canaria Doctor Negrín, Spain, Tel: +34606846959; E-mail: alejandrokun@gmail.com

Received January 30, 2018; Accepted February 16, 2018; Published February 23, 2018

Citation: Alejandro MH, Laura PP (2018) Empyema Caused by *Streptococcus Constellatus*: Atypical Presentation of a Typical Pneumonia. J Clin Case Rep 8: 1079. doi: 10.4172/2165-7920.10001079

Copyright: © 2018 Alejandro MH, et al. This is an open-access article distributed under the terms of the Creative Commons Attribution License, which permits unrestricted use, distribution, and reproduction in any medium, provided the original author and source are credited.

were negative. No sputum was collected due to a lack of secretions. *Streptococcus constellatus* was isolated after 8 days of pleural effusion culture.

The evolution was favourable, and the fever disappeared after pleural drainage and empirical treatment. Oral cephalosporin was continued to complete 14 days of treatment. Six months after discharge, the patient remains asymptomatic.

Discussion

S. constellatus is included in SAG, a group of saprophyte pathogens of the oral, nasopharyngeal, gastrointestinal and genitourinary mucosae [1,2]. Its isolation has been increasingly reported, particularly among the elderly and in patients with underlying diseases predisposing to bronchoaspiration [2-5]. SC is the most frequent isolation in monomicrobial infections [4]. Our case reports a healthy young patient with no underlying diseases and with a prior dental surgery without active infection as the only risk of exposure. The disease onset was subacute, presenting fever and laboratory findings after 21 days, emulating an atypical pneumonia. SC isolation in sputum samples has typically had poor clinical value, underestimating its role as a pathogen [5,6], whereas its isolation in pleural fluid suggests respiratory origin [3]. In our case, as observed in previous literature, the microorganism was sensitive to cephalosporins and required invasive management, as in most of the cases reported [2].

Conclusion

Streptococcus anginosus Group (SAG) are increasingly being

identified as pathogens that cause pneumonia, mainly in elderly patients and in those with predisposing pathologies or previous diagnostic and therapeutic manipulations involving the oropharyngeal mucosa.

Streptococcus constellatus (SC) is the most frequently involved pathogen in monomicrobial pleural infections.

SC pneumonia can be subacute or atypical and should also be considered in healthy young patients with no underlying pathology, especially in those with prior dental surgery.

References

1. Díaz Peromingo JA, Sánchez Leira J, García Suárez F, Padín Paz E, Saborido Froján J (2006) *Streptococcus constellatus* as a causative agent of empyema. Report of one case. Rev Med Chil 134: 1030-1032.
2. Madrid-Carbajal CJ, Molinos L, García-Clemente M, Pando-Sandoval A, Fleites A, et al. (2014) Descripción de casos de derrame pleural secundario a *Streptococcus milleri*. Arch Bronconeumol 50: 404-406.
3. Revilla-Martí P, López-Núñez C (2011) Pleural empyema caused by *Streptococcus constellatus*. Rev Clin Esp 211: 612-613.
4. Hirai J, Sakanashi D, Haranaga S, Kinjo T, Hagihara M, et al. (2016) Case-control study of pneumonia patients with *Streptococcus anginosus* group bacteria in their sputum. J Infect Chemother Off J Jpn Soc Chemother 22: 794-799.
5. Noguchi S, Yatera K, Kawanami T, Yamasaki K, Naito K, et al. (2015) The clinical features of respiratory infections caused by the *Streptococcus anginosus* group. BMC Pulm Med Oct 26: 133.
6. Noguchi S, Yatera K, Kawanami T, Yamasaki K, Fukuda K, et al. (2014) Pneumonia and empyema caused by *Streptococcus intermedius* that shows the diagnostic importance of evaluating the microbiota in the lower respiratory tract. Intern Med Tokyo Jpn 53: 47-50.