

## Efficacy of Pulse Steroid Therapy in Acute Viral Encephalopathy (Case Report)

Barış Adakli<sup>1</sup>, Nedim Çekmen and Tolga Tezer

Department of Anesthesiology and Intensive Care, Güven Hospital, Turkey

**Corresponding author:** Barış Adakli, Department of Anesthesiology and Intensive Care, Güven Hospital, Hüseyin Rahmi sok 8/6, Turkey, Tel: (90)05336122066; E-mail: badakli@hotmail.com

**Rec date:** Apr 17, 2016; **Acc date:** May 24, 2016; **Pub date:** May 26, 2016

**Copyright:** © 2016 Adakli B, et al. This is an open-access article distributed under the terms of the Creative Commons Attribution License, which permits unrestricted use, distribution, and reproduction in any medium, provided the original author and source are credited.

### Abstract

Viral encephalopathy is a very rare, but a serious neurologic condition. We present a patient who was admitted to our hospital because of drowsiness, memory disturbances, non-compliance, and disorientation. Treatment with methylprednisolone pulse treatment facilitated recovery without severe sequela. Therefore; when acute viral encephalopathy is actually suspected, steroid pulse therapy should be considered during the treatment.

**Keywords:** Encephalitis; Pulse steroid therapy; MRI

### Introduction

Encephalopathy corresponds to an inflammation of the brain parenchyma caused by both infectious (influenza A, HHV6, HSV, VZV, measles) and non-infectious diseases (limbic encephalitis, Rasmussen's syndrome, metabolic diseases). Viruses are the most common infectious agents associated with acute encephalitis. In developed countries, HSV type 1 is the most common sporadic encephalitis reason in adults and varicella zoster virus (VZV) is responsible nearly 22% of paediatric cases. The main symptoms are fever, altered level of consciousness, headache, focal neurological deficits and seizure. Noteworthy, about 70% of viral encephalitis cases remain of unknown origin, even with modern laboratorial techniques [1].

In our case, we present an unknown virus infection associated with a rapid recovery of encephalopathy with successful treatment of steroid pulse therapy and aim to discuss this case in company with literature.

### Case Report

A 65 years old woman was admitted to our hospital because of drowsiness, memory disturbance, un-cooperation and disorientation. Her comorbidities were hypertension, hypothyroidis, vertigo and rheumatoid arthritis. The medication she had taken was 50 mg tenoretic (atenolol+chlorthalidone), 200 mg plaquenil (hydroxicloroquine), 50 µg euthyrox (levothroxine), 24 mg betaserc (betahistine dihydrochloride) and 100 mg corasprin (acetylsalicylicacid) also she had already been taking 1500 mg/day klovirex (acyclovir) and 1600 mg/day brufen (ibuprofen) for three days because of her grippal symptoms.

On admission, neurological examination revealed the following; she was confused, un-cooperated, disoriented and Glasgow Coma Scale (GCS) was of 11/15, Acute Physiology and Chronic Health Evaluation II (APACHE II): 20, Multiple Organ Dysfunction Score (MODS): 5, Sequential Organ Failure Assessment (SOFA): 5. Her left pupil was reactive to the light but right pupil reaction was reduced. Deep tendon reflexes were normal and there were no motor deficits. Her physical

examination revealed the following; body temperature 37.8°C (centigrade degree), blood pressure 138/63 mmHg, pulse rate 95 beats/min, regular, respiration rate 18/min, peripheral oxygen saturation (sPO<sub>2</sub>) 98% on room air, arterial blood gas; PO<sub>2</sub>: 66 mmHg, pCO<sub>2</sub>: 28.2 mmHg, sPO<sub>2</sub>: 96.7%, pH: 7.53, HCO<sub>3</sub>: 23.6, Be: 1.0 Mmol/L. Laboratory findings are shown in Table 1. There were no abnormal findings. On the second day of her admission, leukocytosis with neutropile and AST, BUN, creatinine, glucose, LDH, CRP and d-dimer were increased which are shown in Table 2.

| Laboratory findings (day 0) |             |
|-----------------------------|-------------|
| WBC                         | 75600/µL    |
| Neutrophils                 | 67.0%       |
| Lymphocytes                 | 20.2%       |
| Eosinophils                 | 0.16%       |
| Basophils                   | 0.8%        |
| Monocyte                    | 11.8%       |
| RBC                         | 518×104/µL  |
| Hgb                         | 13.2 g/dL   |
| Hct                         | 40.4%       |
| Platelets                   | 229×103/µL  |
| AST                         | 19 U/L      |
| ALT                         | 13 U/L      |
| LDH                         | 213 U/L     |
| Albumin                     | 4.1 g/L     |
| Glucose                     | 104 mg/dL   |
| BUN                         | 18 mg/dL    |
| Creatinine                  | 0.7 mg/dL   |
| Procalcitonin               | <0.05 ng/mL |

|                 |                 |
|-----------------|-----------------|
| Total bilirubin | 0.76 mg/dL      |
| Na              | 138 mEq/L       |
| K               | 3.16 mEq/L      |
| Cl              | 100.5 mEq/L     |
| CRP             | 1.65 mg/L       |
| ST3             | 3.3 pmol/L      |
| ST4             | 18.8 pmol/L     |
| TSH             | 0.48 U/mL       |
| CSF cell count  | rare leukocytes |
| Protein         | 62.4 g/dL       |
| Glucose         | 59 mg/dL        |

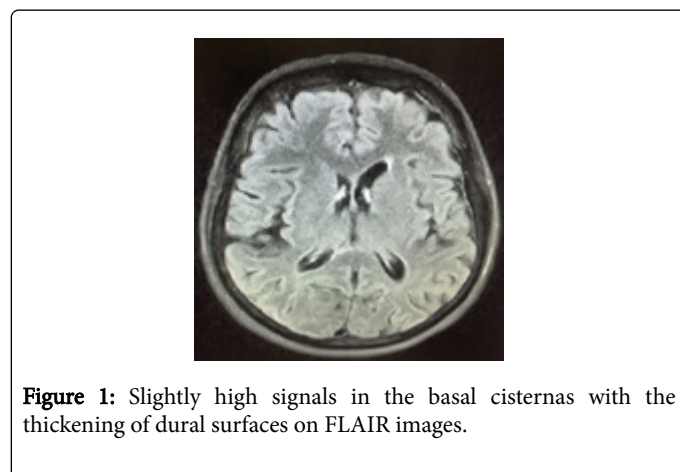
**Table 1:** Laboratory findings (day 0).

| Laboratory findings (day 2) |  |
|-----------------------------|--|
| WBC                         | 134000/ $\mu$ L                        |
| Neutrophils                 | 82.5%                                  |
| Lymphocytes                 | 7.34%                                  |
| Eosinophils                 | 0.01%                                  |
| Basophils                   | 0.4%                                   |
| Monophils                   | 9.7%                                   |
| RBC                         | 448 $\times$ 10 <sup>4</sup>           |
| Hgb                         | 11.2 g/dL                              |
| Hct                         | 35.4 g/dL                              |
| Platelet                    | 190 $\times$ 10 <sup>3</sup> / $\mu$ L |
| AST                         | 46 U/L                                 |
| ALT                         | 22 U/L                                 |
| LDH                         | 397 U/L                                |
| Albumin                     | 3.2 g/L                                |
| Glucose                     | 162 mg/dL                              |
| BUN                         | 36.9 mg/dL                             |
| Creatinine                  | 3.8 mg/dL                              |
| Pro-calcitonin              | 1.58 ng/mL                             |
| Total bilirubin             | 0.2 mg/dL                              |
| Na                          | 144 mEq/L                              |
| K                           | 4.2 mEq/L                              |
| Cl                          | 109.8 mEq/L                            |
| CRP                         | 151 mg/L                               |

|         |             |
|---------|-------------|
| D-dimer | 522.6 ng/mL |
|---------|-------------|

**Table 2:** Laboratory findings (day 2).

On admission, brain computerized tomography (CT) was normal. Follow up brain magnetic resonance imaging (MRI) study showed slightly high signals in the basal cisternas with thickening of the dural surfaces on the fluid-attenuated inversion-recovery (FLAIR) images but no abnormal signal in diffusion weighted imaging (DWI), T2W1, T1W1 and enhanced T1W1 (Figure 1). Electrocardiogram and the chest radiography showed no significant changes. Electroencephalogram showed normal basic activity without epileptiform discharges. Analysis of cerebrospinal fluid (CSF) showed high protein levels with normal glucose level and no pleocytosis. Hepatitis (HBsAg, AntiHBs, HCV) and HIV 1-2 antibodies were negative. Immunoglobuline profile (HSV tip 1/2-IgG/M, CMV IgG/M) and CMV DNA was negative. Septic screening including nasopharyngeal aspiration, blood, sputum and urine cultures, CSF gram stain and culture were normal. No pathogens that might cause meningitis (Herpes simplex virus, Epstein bar virus, Cytomegalovirus) were detected by multiplex polymerase chain reaction (PCR) in her CSF samples.

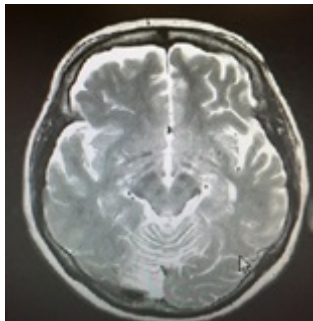


**Figure 1:** Slightly high signals in the basal cisternas with the thickening of dural surfaces on FLAIR images.

On the first day of her admission, she was still not able to talk with her family and did not get well by feeding nutrition, acyclovir (1500 mg/day) and supportive treatments like low molecular weight heparin (LMWH) in case of an embolism. She was still confused, un-cooperated, and disoriented. GKS: 9, APACHE II: 23, MODS: 6, SOFA: 6. Her pupils were bilateral reactive to the light. According to her physical examination; body temperature 36.8°C, blood pressure 150/85 mmHg, pulse rate 170 beats/min, respiratory rate 24/min, 90% sPO<sub>2</sub> with the 4 L/min nasal O<sub>2</sub>, deep metabolic acidosis and hypoxemia on the arterial blood gas, she was electively intubated although non-invasive mechanic ventilation had been performing.

On the 2nd day we started to treat her with IV methylprednisolone pulse therapy (1000 mg/day within 100 ml, 0.9% NaCl approximately in half an hour) under the diagnosis of suspected viral encephalopathy. On the 5th day after the three day methylprednisolone treatment she was extubated and able to speak, oriented and cooperated. On the 10th day, her MRI showed persistent thickening but reduced contrast agent uptake on dural surfaces and subdural hygroma on the right frontal lobe with mild cerebellar atrophy (Figure 2) she was discharged from

intensive care unit to neurology department with mild disturbance in her gait.



**Figure 2:** Persistent thickening on dural surfaces and subdural hygroma on the right frontal lobe.

## Discussion

We present a case report of an adult with acute viral encephalopathy. Although none of pathogenic virus genome was detected in her CSF, her clinical manifestations like fever, confusion, disorientation, un-cooperation and high protein levels in CSF, supported encephalopathy due to viral infection as a clinical diagnosis. Because of acute inflammation via suspected viral infection we decided to treat patient with methylprednisolone pulse therapy. After corticosteroid treatment the patient recovered quickly with mild disturbance of gait.

Encephalopathy corresponds to an inflammation of the brain parenchyma caused by some infectious (mostly the viruses) and non-infectious diseases (limbic encephalitis, Rasmussen's syndrome, metabolic diseases) [1]. Acute viral encephalopathy is often associated with influenza A infection but also has been described in human herpes virus 6 (HHV6), herpes simplex virus (HSV), mycoplasma and measles [2-7]. The pathogenesis of viral encephalopathy is not entirely explained but recent studies showed that high levels of cytokines (IL-6, TNF- $\alpha$ ), nitrogen oxides (NOx) and histiocytosis in some organs were detected as the cause of inflammation [8,9].

Treatments for acute viral encephalopathy have shown much progress during the last years. Primarily, critical care management, close clinical monitoring and MRI studies are needed. Various kinds of modalities have been performed for the treatment; steroid pulse therapy, plasma exchange transfusion, therapeutic hypothermia, intravenous immunoglobulin to modulate immune-mediated neurovascular and cell injury.

Kawano et al. [10] initiated therapeutic hypothermia within 12 hours after onset may have pivotal impacts on the outcome of the patients with acute encephalopathy. Okumura et al. [11] concluded

that administration of steroid within 24 hours after the onset was related to better outcome of the patients with acute encephalopathy. Tabarki et al. [12] showed that in spite of the late administration of the steroids the outcome of the patients was relatively good. Kimura et al. [13] pointed in their study that after administration of 3 days steroid therapy (1000 mg/day) the patient was responded quickly. In our case, the outcome was relatively good in spite of the late administration (on the second day of admission) of pulse steroid therapy (1000 mg/day).

We think that steroid pulse therapy should be considered during the treatment of the encephalopathy even in the lack of controlled studies.

## References

1. Kramer AH (2013) Viral encephalitis in the ICU. *Crit Care Clin* 29: 621-649.
2. Lyon JB, Remigio C, Milligan T, Deline C (2010) Acute necrotizing encephalopathy in a child with H1N1 influenza infection. *Pediatr Radiol* 40: 200-205.
3. Kansagra SM, Gallentine WB (2011) Cytokine storm of acute necrotizing encephalopathy. *Pediatr Neurol* 45: 400-402.
4. Gika AD, Rich P, Gupta S, Neilson DE, Clarke A (2010) Recurrent acute necrotizing encephalopathy following Influenza A in a genetically predisposed family. *Dev Med Child Neurol* 52: 99-102.
5. Neilson DE, Adams MD, Orr CM, Schelling DK, Eiben RM, et al. (2009) Infection-triggered familial or recurrent cases of acute necrotizing encephalopathy caused by mutations in a component of the nuclear pore, RANBP2. *Am J Hum Genet* 84: 44-51.
6. Kim JH, Kim IO, Lim MK, Park MS, Choi CG, et al. (2004) Acute necrotizing encephalopathy in Korean infants and children: imaging findings and diverse clinical outcome. *Korean J Radiol* 5: 171-7.
7. Weng WC, Peng SS, Lee WT (2010) Acute necrotizing encephalopathy of childhood with spinal cord involvement: a case report. *J Child Neurol* 25: 1539-1541.
8. Kawashima H, Watanabe Y, Ichiyama T, Mizuguchi M, Yamada N, et al. (2002) High concentration of serum nitrite/nitrate obtained from patients with influenza-associated encephalopathy. *Pediatr Int* 44: 705-707.
9. Kawashima H, Watanabe Y, Morishima T, Togashi T, Yamada N, et al. (2003) NOx (nitrite/nitrate) in cerebral spinal fluids obtained from patients with influenza-associated encephalopathy. *Neuropediatrics* 34: 137-140.
10. Kawano G, Iwata O, Iwata S, Kawano K, Obu K, et al. (2011) Determinants of outcomes following acute child encephalopathy and encephalitis: pivotal effect of early and delayed cooling. *Arch Dis Child* 96: 936-941.
11. Okumura A, Mizuguchi M, Kidokoro H, Tanaka M, Abe S, et al. (2009) Outcome of acute necrotizing encephalopathy in relation to treatment with corticosteroids and gammaglobulin. *Brain Dev* 31: 221-7.
12. Tabarki B, Thabet F, Shafi AS, Adwani N, Chehab M, et al. (2013) Acute necrotizing encephalopathy associated with enterovirus infection. *Brain Dev* 35: 454-457.
13. Kimura E, Goto H, Migita A, Harada S, Yamashita S, et al. (2010) An adult norovirus-related encephalitis/encephalopathy with mild clinical manifestation. *BMJ Case Rep* 2010.