

## Dieulafoy's Lesion-like bleeding of the Ileum- Iatrogenic or Traditional Lesion?

Kowsika SS<sup>1\*</sup> and Madhira MS<sup>2</sup>

<sup>1</sup>Department of Gastroenterology, Henry Ford Hospital, MI, USA

<sup>2</sup>Department of Gastroenterology, Monroe Gastroenterology Clinic, MI, USA

\*Corresponding author: Sree S Kowsika, Department of Gastroenterology, Henry Ford Hospital, USA, E-mail: sskowsika@gmail.com

Received date: February 25, 2018; Accepted date: March 07, 2018; Published date: March 13, 2018

Copyright: ©2018 Kowsika SS, et al. This is an open-access article distributed under the terms of the Creative Commons Attribution License, which permits unrestricted use, distribution, and reproduction in any medium, provided the original author and source are credited.

### Abstract

Dieulafoy's lesion is an aberrant submucosal arteriole that erodes through the overlying mucosa in the absence of an ulcer. They are a rare cause of gastrointestinal (GI) hemorrhage and can cause rapid blood loss. Dieulafoy's lesions are usually located in the upper GI tract along the lesser curvature of the stomach or duodenum. However, lesions in other areas of the GI tract including post-surgical bowel, have also been found. Angiogenesis at the anastomotic junctions can sometimes lead to the formation of Dieulafoy's -like lesions. A very high index of suspicion is needed to establish the diagnosis of such lesions.

**Keywords** Dieulafoy's; Dieulafoy's-like lesions, Obscure GI hemorrhage

### Introduction

Dieulafoy's lesion is a relatively rare but potentially life threatening cause of GI hemorrhage. Dieulafoy's lesions are accounted for about 1-2% of acute GI bleeds [1,2]. They are believed to be under recognized more than being rare. These lesions are due to an aberrant submucosal blood vessel which usually does not undergo the normal branching within the wall of the GI tract, and as a result its caliber remains large in size. Dieulafoy's lesions are reported in all areas of the GI tract but are most commonly located within 6 cm of gastroesophageal junction [3]. Dieulafoy's lesions in the ileal region and ileo-colonic anastomotic regions are rare. Angiogenesis of the anastomotic junctions of the bowel can lead to the formation of Dieulafoy's-like lesions. Diagnosis is often very difficult due to the obscure nature of the GI hemorrhage caused by these lesions. Endoscopic methods may fail to identify such lesions and tagged RBC scan or angiography may sometimes aid in the diagnosis. Despite all these methods, some patients may end up with surgical interventions. A very high index of suspicion is needed in patients with post-surgical bowel who present with obscure bleeding. Careful examination of the anastomotic junction may help in the diagnosis. We present a case of Dieulafoy's-like lesion in the ileum at the ileo-colonic anastomosis.

### Case

Patient is a 57 year old female who presented to the emergency department with four episodes of bright red blood per rectum. She has history of GERD, and asthma. Her home medications include omeprazole, and as needed albuterol inhaler. She denied using NSAIDs.

10 years ago, patient had a pelvic abscess from inadvertent enterotomy during a laparoscopic hysterectomy. Then she had a laparotomy with temporary loop ileostomy, descending colostomy, formation of Hartman's pouch, drainage of pelvic abscess and repair of

enterotomy. Patient eventually had partial small bowel resection with take down of ileostomy and colostomy to re-establish bowel continuity. Two years prior to the current presentation, patient had an episode of severe GI bleed with no identifiable lesions on EGD, small bowel follow through and colonoscopy.

Physical examination revealed BP 103/50 mm Hg, Pulse 94/min, RR 18/min, and Temp 98 F. Heart and lung examinations were normal. Abdomen was soft, non-tender with normal bowel sounds and no organomegaly. Labs showed hemoglobin 6.7 gm, hematocrit 25, MCV 96, platelet count of 250,000 and INR 1.

She received 4 units of packed RBCs and IV fluids. Repeat EGD showed no source of bleeding. Colonoscopy showed fresh blood throughout the colon and terminal ileum with no clear source of bleeding (Figure 1). CT abdomen showed a mass in the pelvic area and tagged RBC scan showed bleeding corresponding to the mass on the CT scan. She underwent exploratory laparotomy, with extensive lysis of adhesions, repair of enterotomy, resection of previous small bowel anastomosis and creation of new anastomosis of the ileum. Bleeding subsided completely after the surgery. Pathological examination of the resected ileal anastomotic junction showed large blood vessels under the mucosa with superficial epithelial disruption which was consistent with Dieulafoy's lesions.

### Discussion

Acute GI bleeding ranges from 50-150 per 100,000 of the population each year [2]. Most common causes include peptic ulcer disease or erosions of the esophagus or gastroduodenal junctions. Obscure bleeding accounts for less than 5% of GI bleeding [3]. Dieulafoy's lesions are one of the causes of obscure bleeding. They are particularly important because they can cause rapid blood loss and death of the patients and can be very difficult to diagnose. They are formed by an aberrant submucosal blood vessel that erodes the superficial mucosa and causes GI bleed. Even though they can be located anywhere in the GI tract, most common locations include the gastric or gastro-esophageal junctions. Eddie et al first presented a case of Dieulafoy's-like lesion in the afferent loop of a Billroth II gastric

resection [3]. The proportion of Dieulafoy's-like lesion bleeding at the anastomotic junctions range from 10-58% [1]. Etiology of these lesions

is unknown, but is believed to be due to vascular malformation during the angiogenesis of the anastomotic junction [1].

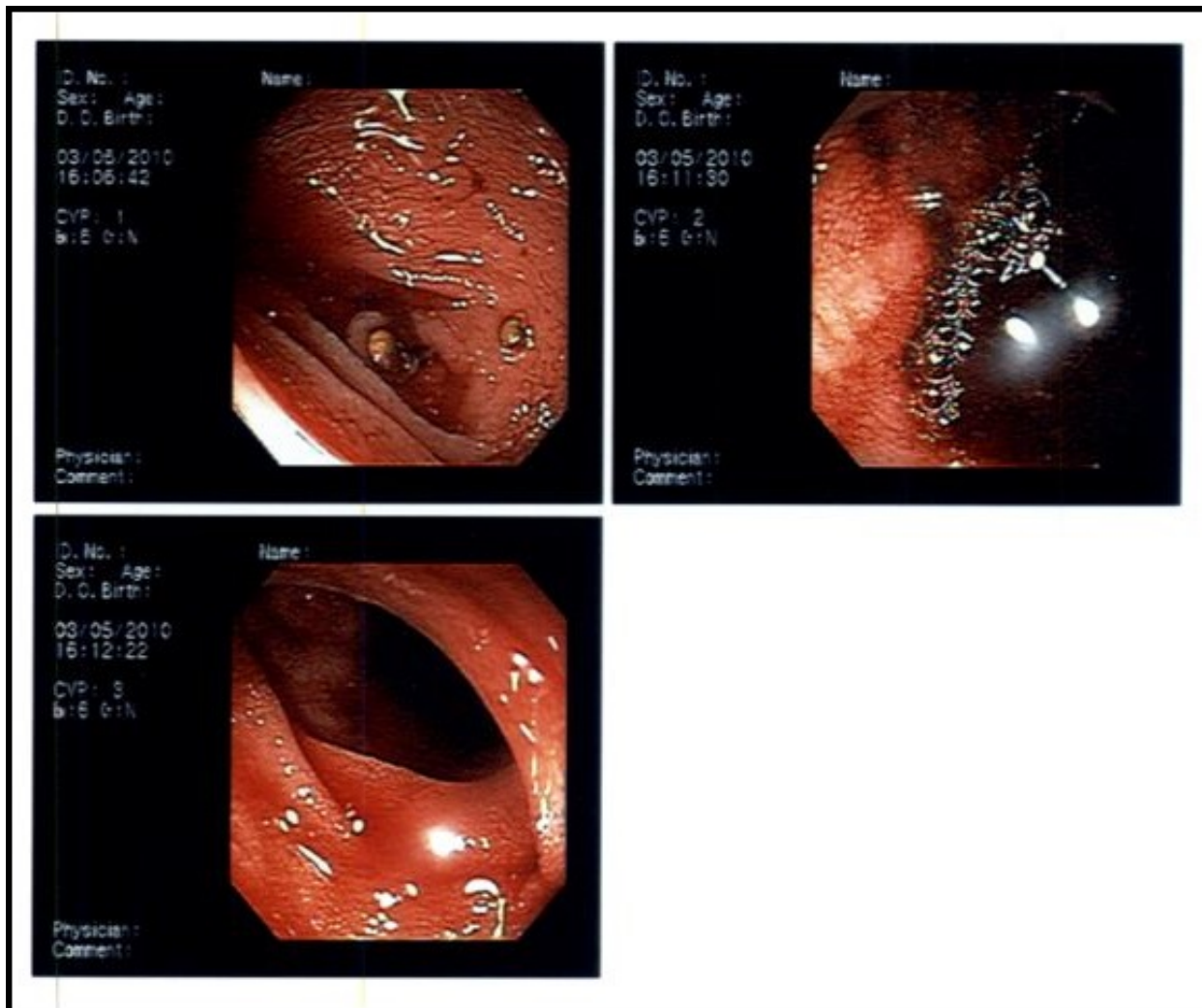


Figure 1: Colonoscopy showed fresh blood throughout the colon and terminal ileum with no clear source of bleeding

Initial diagnostic approach includes endoscopic methods as these procedures are both diagnostic and therapeutic. When a Dieulafoy's lesion is suspected, some non-specific endoscopic criteria could be used which include [2], active arterial spurting or micropulsatile bleeding from a minute mucosal defect less than 3 mm or normal mucosa. Visualization of a protruding vessel with or without bleeding within a small mucosal defect. The appearance of a fresh adherent clot to the mucosal defect or normal mucosa.

However, initial endoscopic methods may fail for several reasons like presence of excessive blood in the gut, or a subtle lesion being overlooked. In these cases, endoscopic aids can be used. One such method is endoscopic ultrasound which enables the use of doppler. Doppler ultrasound helps with identification of submucosal arteries that induce hemorrhage [4]. Push enteroscopy allows assessment of small intestine of up to 150 cm from the pylorus [2]. When endoscopic methods fail, angiography or tagged RBC scan could be used to help in the diagnosis. Angiography can sometimes achieve successful

hemostasis by embolization of the bleeding vessel [1]. If both endoscopic and angiographic methods fail, surgery remains the treatment of choice as in our patient.

## Conclusion

A high index of suspicion is needed to establish the diagnosis of Dieulafoy's lesions especially in patients with history of bowel resection or anastomosis. Careful evaluation of the anastomotic junction of the bowel may aid in early diagnosis and treatment.

Multi-modal diagnostic and treatment modalities may be necessary to be employed to diagnose post-surgical Dieulafoy's lesions [1]. Angiographic embolization or surgical resection may be the treatment options available.

---

**References:**

1. Patel P, Tobi M (2011) Dieulafoy-Like Lesion Bleeding: In the Loop. *Gastroenterol Hepatol* 7: 271-274.
2. Baxter M, Aly E (2010) Dieulafoy's lesion: current trends in diagnosis and management. *Ann R Coll Surg Engl* 92: 548-554.
3. Eddi R, Shah N, Depasquale JR (2011) Gastrointestinal Bleeding Due to a Dieulafoy Lesion in the Afferent Limb of a Billroth II Reconstruction. *Gastroenterol Hepatol* 7: 268-271.
4. Jaspersen D (1993) Dieulafoy's disease controlled by Doppler ultrasound endoscopic treatment. *Gut* 34: 857-858.