

# Diagnostic Discrepancies between Intraoperative Cytological Frozen Section and Permanent Histopathological Diagnosis of Brain Tumors

Maher Kurdi<sup>1\*</sup>, Saleh Baeesa<sup>2</sup>, Yazid Maghrabi<sup>3</sup>, Anas Bardeesi<sup>3</sup>, Rothaina Saeedi<sup>4</sup>, Taghreed Al-Sinani<sup>5</sup>, Alaa Samkari<sup>6</sup> and Ahmed Lary<sup>7</sup>

<sup>1</sup>Department of Pathology, Faculty of Medicine in Rabigh, King Abdulaziz University, Kingdom of Saudi Arabia

<sup>2</sup>Division of Neurosurgery, Faculty of Medicine, King Abdulaziz University, Jeddah, Kingdom of Saudi Arabia

<sup>3</sup>Department of Neuroscience, King Faisal Specialist Hospital, Jeddah, Kingdom of Saudi Arabia

<sup>4</sup>Section of Neurosurgery, Department of Surgery, King Abdulaziz University Hospital, Jeddah, Kingdom of Saudi Arabia

<sup>5</sup>Division of Neurosurgery, Department of Surgery, King Fahad General Hospital, Jeddah, Kingdom of Saudi Arabia

<sup>6</sup>Department of Pathology and Laboratory Medicine, King Saud Bin Abdulaziz University for Health Science, Jeddah, Kingdom of Saudi Arabia

<sup>7</sup>Section of Neurosurgery, Department of Surgery, King Abdulaziz Medical City, Jeddah, Kingdom of Saudi Arabia

## Abstract

**Background:** Intraoperative frozen section (IOFS) diagnosis of brain tumours plays an important role in assessing the adequacy of the sample and determining the treatment plan.

**Objective:** To investigate the diagnostic accuracy between IOFS and permanent paraffin-embedded sections in the endpoint of surgery.

**Method:** The authors reviewed the histopathological results of 383 brain tumours, including IOFS and permanent histological diagnosis. The cases were classified into three diagnostic compatibilities (i) Perfect fit; the diagnosis of IOFS was identical to the permanent diagnosis, (ii) Partial compatibility; IOFS diagnosis was not incorrect but was too broad to be considered full compatibility, (iii) Conflict; IOFS diagnosis is completely different from the permanent diagnosis. The permanent diagnosis used as a primary criterion was compared to the IOFS diagnosis and recurrence rate using different statistical methods.

**Results:** The mean age of the whole cases was 37-years with male: female ratio 1:2. Around 84% of the patients underwent craniotomy and tumour resection, while 15% only underwent tumour biopsy. Approximately, 53.8% of the cases revealed perfect matching in the diagnosis between IOFSs and permanent sections, while 16.2% of the cases revealed complete mismatching in the diagnosis between the sections. The remaining 30% of the cases showed partial compatibility in the diagnosis between the two diagnostic methods. There was no significant difference in recurrence rate among all cases of different diagnostic compatibility (P-value= 0.54).

**Conclusion:** There is a diagnostic discrepancy between IOFSs and permanent sections. However, cases that revealed no consensus in the diagnoses showed no negative effect on the patient outcome. Further studies should be conducted to explore the reasons of this conflict in the diagnosis between the two diagnostic methods.

**Keywords:** Brain tumor • Histopathology • Frozen section • Diagnostic compatibility

## Introduction

Brain tumors, known as intracranial tumors, are abnormal masses of tissue with cells that continuously grow and multiply. More than 150 types of brain tumors have been documented by the World Health Organization (WHO) [1]. They can be categorized as primary and metastatic tumors. Primary tumors arise from brain tissue or surrounding structures, which include neuroglial cells, meninges, or the ependymal layer. They can be benign (low-grade) or malignant (high-grade). Secondary metastatic brain tumors include any systemic organ cancer that hematogenously spreads to the brain. To distinguish primary from secondary brain tumors, a detailed clinical history and body imaging are important to identify the origin of the tumor but not the exact histological subtype. Furthermore, intraoperative examination of tumor tissue is the gold diagnostic tool to differentiate the two types and to

determine the surgical treatment plan.

Intraoperative frozen section (IOFS) diagnosis of brain tumors plays an important role in assessing the adequacy of the specimen, determining the surgical treatment plan, improving surgical procedures, and facilitating postoperative follow-up. In certain cases, when unexpected lesions cannot be identified by radiological imaging, the surgeon can determine the best procedure and endpoint of the operation [2,3]. This can reduce the incidence of surgical complications and avoid unnecessary second surgical procedures. The key criteria and indications for requesting an intraoperative diagnosis by the surgeon are as follows:

- (i) intraoperative surgery would be affected by the diagnosis,
- (ii) an unexpected lesion appears during surgery that is different from what was clinically suspected,
- (iii) the primary goal is to obtain a biopsy diagnosis, and
- (iv) the necessity to assess the margins if a total resection is planned [4-6].

The distinction between primary tumor, lymphoma, metastatic tumor, or unusual lesions are considered the main reasons for requesting intraoperative diagnosis of brain tumors. Sometimes, the tumor is not accessible by surgery, and thus a stereotactic biopsy with IOFS is recommended. The assessment of brain tumors through IOFS is commonly used in clinical practice to verify

\*Address for Correspondence: Maher Kurdi, MD, Assistant Professor of Neuropathology, Department of Pathology, Faculty of Medicine in Rabigh, King Abdulaziz University, Kingdom of Saudi Arabia; E-mail: Ahkurdi@kau.edu.sa

**Copyright:** © 2021 Maher Kurdi, et al. This is an open-access article distributed under the terms of the Creative Commons Attribution License, which permits unrestricted use, distribution, and reproduction in any medium, provided the original author and source are credited.

**Received** 27 May 2021; **Accepted** 13 July 2021; **Published** 20 July 2021

the origin and type of tumor; however, the final diagnosis should be reported later after the permanent section [4,6].

Several studies have discussed the diagnostic accuracy of IOFS in assessing brain tumor type and grading, and inconsistencies were found between IOFS diagnosis and permanent diagnosis. Nevertheless, permanent paraffin-embedded examination remains the gold standard in diagnosing brain tumors.

In Saudi Arabia, no publications have discussed the diagnostic accuracy between IOFS and permanent tissue diagnosis of brain tumors. In this study, we aimed to assess the compatibility between the results of frozen sections and permanent sections in patients diagnosed with brain tumors. We also discuss the reasons attributed to the lack of diagnostic accuracy between the two diagnostic methods.

## Materials and Methods

### Case Stratification

In this retrospective study, we reviewed the histopathological reports of 383 primary and secondary brain tumors between 2013 and 2019 from two medical institutions in Saudi Arabia. The study was ethically approved by the National Biomedical Ethics Committee at King Abdulaziz University (HA-02-J-008) under general ethical approval. Patient age, gender, intraoperative and permanent histological diagnosis and grading, and recurrence rate were used as statistical factors. The permanent section result was used as a primary criterion, and the frozen section diagnosis was compared with the final diagnosis.

### Histopathological Confirmation

The histopathological report of IOFS and permanent paraffin-embedded section of each patient with a brain tumor was examined. The diagnostic compatibility between the two diagnostic methods was determined on the basis of tumor type and grading. The cases were classified into three degrees of diagnostic compatibility as follows:

- i) the diagnosis of IOFS was identical to the final diagnosis (perfect fit);
- ii) the diagnosis of IOFS was not incorrect but was too broad to be considered fully compatible (partial compatibility); and
- iii) the diagnosis of IOFS were incorrect and differs from the final diagnosis (conflict).

### Statistical Analysis

Statistical analysis was performed using SPSS software (version 20). To describe the data, we used means, frequencies, and percentages. To assess the diagnostic compatibility of different methods, we used the linear model, ANOVA and people's Chi-square test. The number and types of discrepancies were identified.

## Results

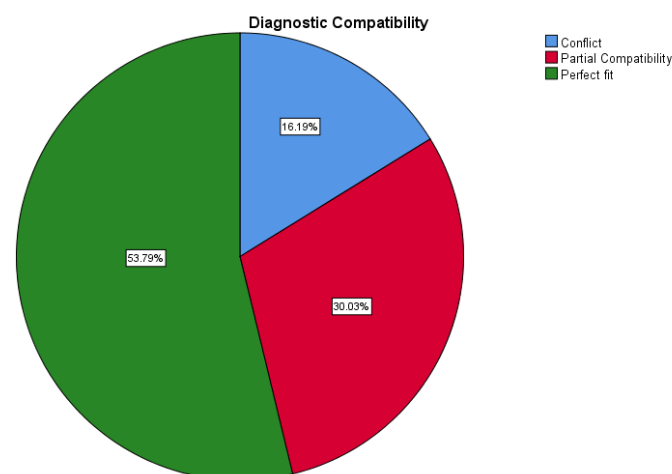
The mean age of the 383 patients was  $37.6 \pm 23.1$  years (females: 212 (55.4%); males: 171 (44.6%)). Around 84% of the patients underwent craniotomy and tumor resection, while 15% only underwent tumor biopsy (open or stereotactic biopsy). Most of the tumors were grade IV ( $n=177$ , 46.2%), followed by grade II ( $n=105$ , 27.4%) (Table 1). Tumour locations are summarized in Figure 1.

### Diagnostic compatibility between IOFS and permanent sections

The diagnostic compatibility between IOFS and permanent section showed comprehensive variability, as 53.8% ( $n=206$ ) of the cases showed perfect match between IOFS and permanent section diagnosis, while 16.2% ( $n=62$ ) cases showed complete mismatch. Furthermore, 30% ( $n=115$ ) of the cases

**Table 1.** Descriptive distribution of the data in this study. There is 53% perfect diagnostic compatibility between intraoperative frozen sections and permanent sections.

|                                 | Overall (N=383) |
|---------------------------------|-----------------|
| <b>Age</b>                      |                 |
| Mean (SD)                       | 37.6 (23.1)     |
| Range                           | 1.0–87.0        |
| <b>Gender</b>                   |                 |
| Female                          | 171 (44.6%)     |
| Male                            | 212 (55.4%)     |
| <b>Type of Tissue Removal</b>   |                 |
| Tumor biopsy                    | 58 (15.14%)     |
| Surgical resection              | 325 (84.9%)     |
| <b>Diagnostic Compatibility</b> |                 |
| Conflict                        | 62 (16.2%)      |
| Partial Compatibility           | 115 (30.0%)     |
| Perfect fit                     | 206 (53.8%)     |
| <b>WHO Grading</b>              |                 |
| Grade I                         | 105 (27.4%)     |
| Grade II                        | 53 (13.8%)      |
| Grade III                       | 36 (9.4%)       |
| Grade IV                        | 177 (46.2%)     |
| Unclassified                    | 12 (3.1%)       |



**Figure 1.** Diagnostic compatibility between intraoperative frozen sections and permanent-paraffine embedded sections in all brain tumors enrolled in this study.

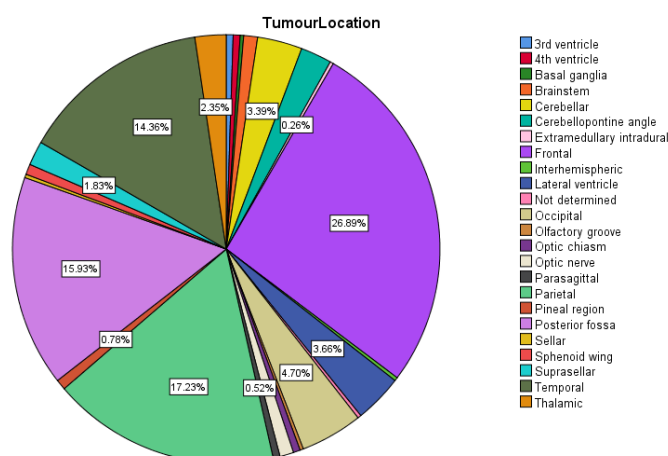
showed partial compatibility between the two diagnostic methods (Table 1, Figure 2). For example, the cases diagnosed as glioblastoma with IOFS were also diagnosed as glioblastoma with permanent section; however, these cases represented 13% perfect compatibility among all investigated brain tumors (Table 2). In a few cases, glioblastomas were misdiagnosed with IOFS as low-grade gliomas, necrotic cells, or glioneuronal tumors (Table 3). Hemangioblastomas, schwannomas, pilocytic astrocytomas, and metastatic carcinomas had perfectly matching diagnoses on both sections (Tables 2,3 & Figure 2).

### Diagnostic compatibility of low-grade and high-grade gliomas

Approximately 9% of the cases diagnosed as low-grade gliomas with IOFS were diagnosed as high-grade gliomas with permanent sections, and one case was found to be a meningioma (Table 2). Conversely, 17% of the cases diagnosed as high-grade gliomas with IOFS were diagnosed on permanent sections as either low-grade gliomas or a different histological subtype such as medulloblastoma or metastasis. Furthermore, 19% of the cases

**Table 2.** Diagnostic compatibilities of the probabilities of all frozen sections compared with permanent final diagnosis in brain lesions. This table compares the diagnostic compatibility of each tumor through the total number of all cases.

|                          | Conflict<br>(n=62) | Partial compatibility<br>(n=115) | Perfect fit<br>(n=206) | Total<br>(n=383) |
|--------------------------|--------------------|----------------------------------|------------------------|------------------|
| Frozen Section Diagnosis |                    |                                  |                        |                  |
| Atypical glial cells     | 2.0 (3.2%)         | 20.0 (17.4%)                     | 0.0 (0.0%)             | 22.0 (5.7%)      |
| Ependymoma               | 1.0 (1.6%)         | 0.0 (0.0%)                       | 8.0 (3.9%)             | 9.0 (2.3%)       |
| Glioblastoma             | 0.0 (0.0%)         | 0.0 (0.0%)                       | 28.0 (13%)             | 28.0 (7.3%)      |
| Glioma                   | 0.0 (0.0%)         | 1.0 (0.9%)                       | 0.0 (0.0%)             | 1.0 (0.3%)       |
| Glioneuronal tumor       | 3.0 (4.8%)         | 3.0 (2.6%)                       | 1.0 (0.5%)             | 7.0 (1.8%)       |
| Hemangioblastoma         | 0.0 (0.0%)         | 0.0 (0.0%)                       | 5.0 (2.4%)             | 5.0 (1.3%)       |
| Hemorrhage               | 2.0 (3.2%)         | 0.0 (0.0%)                       | 0.0 (0.0%)             | 2.0 (0.5%)       |
| High grade glioma        | 17.0 (27.4%)       | 3.0 (2.6%)                       | 101.0 (49%)            | 121.0 (31%)      |
| Infiltrating glioma      | 2.0 (3.2%)         | 19.0 (16%)                       | 2.0 (1.0%)             | 23.0 (6.0%)      |
| Low grade glioma         | 6.0 (9.7%)         | 61.0 (53%)                       | 10.0 (4.9%)            | 77.0 (20%)       |
| Lymphoma                 | 2.0 (3.2%)         | 0.0 (0.0%)                       | 0.0 (0.0%)             | 2.0 (0.5%)       |
| Malignant cells          | 0.0 (0.0%)         | 3.0 (2.6%)                       | 0.0 (0.0%)             | 3.0 (0.8%)       |
| Meningioma               | 1.0 (1.6%)         | 2.0 (1.7%)                       | 27.0 (13%)             | 30.0 (7.8%)      |
| Mesenchymal tumor        | 0.0 (0.0%)         | 2.0 (1.7%)                       | 0.0 (0.0%)             | 2.0 (0.5%)       |
| Metastatic tumor         | 0.0 (0.0%)         | 0.0 (0.0%)                       | 9.0 (4.4%)             | 9.0 (2.3%)       |
| Necrotic cells           | 20.0 (32.3%)       | 1.0 (0.9%)                       | 0.0 (0.0%)             | 21.0 (5.5%)      |
| Pilocytic astrocytoma    | 0.0 (0.0%)         | 0.0 (0.0%)                       | 10.0 (4.9%)            | 10.0 (2.6%)      |
| Reactive cells           | 6.0 (9.7%)         | 0.0 (0.0%)                       | 0.0 (0.0%)             | 6.0 (1.6%)       |
| Schwannoma               | 0.0 (0.0%)         | 0.0 (0.0%)                       | 5.0 (2.4%)             | 5.0 (1.3%)       |



**Figure 2.** Tumour locations of all cases enrolled in this study. There is 0.25% of cases did not have specific location or the location was not mentioned in the report.

diagnosed with infiltrating glioma with IOFS showed partial compatibility on permanent sections. The final diagnosis was grade II, such as cases of oligodendrogliomas (Table 2).

### Diagnostic compatibility between atypical, reactive, and necrotic cells

From the 22 cases diagnosed as atypical glial cells with IOFS, two of them were permanently diagnosed as mature teratoma and hemangioblastoma. The remaining 20 cases of atypical glial cells were compatible with the same glioma histogenesis, regardless of the grading. These cases were considered partially compatible. The cases that were diagnosed as showing reactive cells with IOFS (n=6, 9.6%) were diagnosed differently from permanent sections (Table 2). These cases included teratoma, hemangioblastoma, germinoma, ganglioglioma, pilocytic astrocytoma, and pituitary adenoma. Cases for which IOFS revealed necrotic cells were diagnostically deferred at the time of surgery. Their permanent sections revealed malignant tumors except one case (pilocytic astrocytoma in the brainstem), which was rediagnosed as diffuse midline glioma.

**Table 3.** List of brain tumors with their misdiagnosis with intraoperative frozen sections (IOFS).

|                               | Misdiagnosis in IOFS  |
|-------------------------------|---|
| Glioblastoma                  | Low-grade glioma<br>Glioneuronal tumor<br>Necrotic cells          |
| Metastatic carcinoma          | High-grade glioma   |
| Hemangioblastoma              | Atypical glial cells<br>Reactive cells<br>Hemorrhage              |
| Medulloblastoma               | High-grade glioma<br>Necrotic cells                               |
| Diffuse large B-cell lymphoma | High-grade glioma<br>Infiltrating glioma                          |
| Pilocytic astrocytoma         | High-grade glioma<br>Necrotic cells<br>Lymphoma<br>Reactive cells |
| Schwannoma                    | Meningioma  |

### Relationship between recurrence status and diagnostic compatibility

There was no significant relationship between the recurrence rates and the diagnostic compatibilities of different brain tumors ( $P=0.54$ ) (Table 4). Cases that showed conflicts in diagnostic compatibility showed no significant differences in recurrence rates compared to cases with perfect diagnosis matches.

## Discussion

Different types of brain tumors have been documented by the WHO [1]. They are categorized as primary and metastatic tumors. Primary tumors arise from brain tissue or surrounding structures and are benign (low-grade) or malignant (high-grade). Secondary metastatic brain tumors arise from any systemic organ cancer. To distinguish primary from secondary brain tumors,

**Table 4.** Relationship between recurrence rate and diagnostic compatibilities of intraoperative frozen sections and permanent sections. There is no significant relationship between recurrence rate and different diagnostic compatibilities of different brain tumors ( $P=0.54$ ).

|                          | No recurrence<br>(n=216) | Recurrence<br>(n=167) | Total<br>(n=383) | P value            |
|--------------------------|--------------------------|-----------------------|------------------|--------------------|
| Diagnostic Compatibility |                          |                       |                  | 0.547 <sup>1</sup> |
| Conflict                 | 36.0 (16.7%)             | 26.0 (15.6%)          | 62.0 (16.2%)     |                    |
| Partial Compatibility    | 69.0 (31.9%)             | 46.0 (27.5%)          | 115.0 (30.0%)    |                    |
| Perfect fit              | 111.0 (51.4%)            | 95.0 (56.9%)          | 206.0 (53.8%)    |                    |

<sup>1</sup> Linear model ANOVA

body imaging and intraoperative examination of tumor tissue are considered the best diagnostic methods, which can also determine the surgical treatment plan. Our current study included 369 primary brain tumors and 14 metastatic tumors to the brain.

Surgeons usually request IOFS mainly if an unexpected lesion appears during surgery that differs from what is clinically suspected or if the primary goal is to obtain a biopsy diagnosis [4,5]. In brain tumors, the distinction between primary tumor, lymphoma, metastasis, and unusual lesions is considered the main reason for requesting IOFS.

The IOFS analysis was first introduced in 1891 by a pathologist at Johns Hopkins Hospital and is currently used worldwide. The application of this method became much easier through improvements in cryostat devices [7]. IOFS is mainly useful for solid and stretchy tumors such as meningiomas, schwannoma, and most metastases in which well cell smears are difficult to prepare [8-10]. It also provides good architectural detail of the lesion and better reveals histological patterns and cell morphology [11]. IOFS is commonly used to verify the competence and origin of brain tumors [4,6].

There are two methods to assess the diagnostic compatibility between IOFS and permanent sections. The first method is to determine whether the IOFS diagnosis matches the permanent diagnosis, e.g., glioblastoma diagnosed with IOFS is also diagnosed as glioblastoma with permanent section. The second method is to determine whether the permanent diagnosis is histologically close to the IOFS diagnosis, e.g., glioblastoma diagnosed on permanent section is observed as atypical glial cells in frozen sections. In our current study, both methods were used; however, we focused more on the first method as it represents the foundation of the general diagnostic accuracy of brain tumors [12,13].

The diagnostic compatibility between IOFS and permanent section showed much variation. Only 53% of the lesions diagnosed on permanent sections matched the diagnosis with IOFS, while 16% showed complete mismatching (Figure 2). This variation is considered clinically significant as it reveals that IOFS itself should not be used solely as a definitive diagnostic method. Most of the discordances between IOFS and permanent sections were observed in high-grade gliomas, medulloblastomas, and hemangioblastomas. It is sometimes difficult to identify the cytoplasmic processes in the frozen cut, which makes it difficult to differentiate glial background from other types of tumors, particularly metastasis. For example, glioblastomas may be misdiagnosed as low-grade gliomas with IOFS. The distinction between high-grade gliomas and metastasis is also difficult unless the malignant glial cells are clearly seen [14].

In some cases, the incorrect IOFS diagnosis of astrocytomas could be due to the thickness of the sections and technical problems with staining, which disrupts the cellular morphology. The difficulties in diagnosing hemangioblastoma with IOFS were because most hemangioblastomas are bloody and vascular, which masks the cellular features of the tumors. Cases that showed reactive or necrotic cells with IOFS revealed different diagnostic results on permanent sections. For example, most of the cases diagnosed as necrotic cells with IOFS had permanent section diagnosis of glioblastoma, while IOFS diagnosis of reactive cells had permanent section diagnosis of teratoma, hemangioblastoma, germinoma, ganglioglioma, pilocytic astrocytoma, or pituitary adenoma. These findings depended on the biopsy location and the size of the necrotic component in the tumor.

The diagnostic accuracy in our study was 53%. In other studies, the diagnostic accuracy was 92.4% in Talan Hernilovic et al. [15] and 95% in Roessler et al. [16] with 89% complete concordance among 4,172 patients. The most accurate IOFS diagnoses in Roessler's study were made in cases of meningioma (97.9%), metastasis (96.3%), and glioblastoma (95.7%) [16]. Although the high-grade gliomas showed high discordance between IOFS and permanent section, the diagnostic compatibility is still acceptable. We also found that 97% of meningioma cases showed perfect matching between the IOFS and permanent section diagnoses. One case turned out to be a schwannoma.

Several reasons can be attributed to this mismatching. Theoretically, the reasons can either be related to the surgical procedure or laboratory and diagnostic techniques. If the neurosurgeon takes the biopsy from the necrotic part of the tumor or from the surrounding reactive area, the tissue will be fragmented, nonviable, and nondiagnostic. An experienced neurosurgeon should navigate the tumor through brain imaging before taking the biopsy. However, multiple punch biopsies are recommended in this case. Improper freezing processes may also mask the tissue diagnosis. Calcification, autolysis, improper hematoxylin and eosin staining, or inappropriate usage of hemostatic agents all contribute to incorrect diagnosis.

One of the common reasons for diagnostic disagreements between IOFS and permanent paraffin-embedded sections are variable microscopic interpretations. Most pathologists who observe brain tumors during IOFS are non-neuropathologists with limited experience in diagnosing brain tumor tissues. Pathologists who observe brain tumors under the microscope must also know how to correlate brain imaging with histology. This would help pathologists minimize differential diagnoses and approximate the diagnostic probabilities between neurosurgeons and pathologists. This problem is common in developing countries with health care systems that lack neuropathologists.

## Conclusion

The role of frozen sections during intraoperative consultation is important. Our results showed some diagnostic discrepancies between the intraoperative diagnosis of brain tumors and permanent final diagnosis. Appropriate knowledge of pathologists regarding radiological findings and microscopic interpretation with proper communication with neurosurgeons are required to minimize IOFS misdiagnosis. Further studies should be conducted to determine the reasons for this discrepancy and to solve the problems related to this incompatibility.

## References

1. Louis David N, Hiroko Ohgaki, Otmar D Wiestler and Webster KCavenee, et al. "The 2007 WHO classification of tumours of the central nervous system." *Acta Neuropathol* 114(2007):97-109.
2. Taxy Jerome B, Aliya N Husain and Anthony G. Montag. "Biopsy interpretation: the frozen section." Lippincott Williams & Wilkins (2009):301-3.
3. Somerset Hilary Lynch and Bette Kay Kleinschmidt-DeMasters. "Approach to the intraoperative consultation for neurosurgical specimens." *Adv Anat Pathol* 18(2011):446-9.

4. Di Stefano Domenica, Luigi Faticanti Scucchi, Lucio Cosentino and Cesare Bosman, et al. "Intraoperative diagnosis of nervous system lesions." *Acta Cytol* 42(1998):346-56.
5. Ironside James W, David N Louis, Tim H Moss and James S Lowe, et al. "Diagnostic Pathology of Nervous System Tumours." Churchill Livingstone, Elsevier Science Limited (2002):39-52.
6. Yachnis Anthony T. "Intraoperative consultation for nervous system lesions." *Semin Diagn Pathol* 19(2002):192-206.
7. Shrestha S, R Basyal, T Shrestha S Pathak, MC Lee and H Dhakal et al. "Comparative study of frozen section diagnoses with histopathology." *Postgrad Med J* 9(2009).
8. Adams HJ, Graham DI and Doyle D. "The Smear Technique for Surgical Biopsies." London:Chapman and Hall (1981).
9. Folkerth Rebecca D. "Smears and frozen sections in the intraoperative diagnosis of central nervous system lesions." *Neurosurg Clin N Am* 5(1994):1-18.
10. Plesec Thomas P and Richard A Prayson. "Frozen section discrepancy in the evaluation of central nervous system tumors." *Arch Pathol Lab Med* 131(2007):1532-1540.
11. Sharma Nishant, Vatsala Misra, Singh PA and Shiv Kumar Gupta and Sharmistha Debnath, et al. "Comparative efficacy of imprint and squash cytology in diagnosing lesions of the central nervous system." *Asian Pac J Cancer Prev* 12(2011):1693-1696.
12. Regragui A, Maher M, A El Khamlichi and A. Saidi. "Accuracy of intraoperative diagnosis in central nervous system tumors: report of 1315 cases." *Neuro-chirurgie* 49 (2003):67-72.
13. Savargaonkar Pratima and Peter M Farmer. "Utility of intra-operative consultations for the diagnosis of central nervous system lesions." *Ann Clin Lab Sci* 31(2001):133-139.
14. Brat Daniel J, Richard A Prayson, Timothy C Ryken and Jeffrey J Olson. "Diagnosis of malignant glioma: role of neuropathology." *J Neuro Oncol* 89(2008):287-311.
15. Talan-Hranilović Jasna, Majda Vučić, Monika Ulamec and Mladen Belicza. "Intraoperative Frozen Section Analyses of the Central Nervous System and Pituitary Gland Pathology." *Acta Clin Croat* 44(2005):217-221.
16. Roessler Karl, Wolfgang Dietrich and Klaus Kitz. "High diagnostic accuracy of cytologic smears of central nervous system tumors." *Acta Cytol* 46(2002):667-74.

**How to cite this article:** Maher Kurdi, Saleh Baeesa, Yazid Maghrabiand, Anas Bardeesi . "Diagnostic Discrepancies between Intraoperative Cytological Frozen Section and Permeant Histopathological Diagnosis of Brain Tumors." *J Cytol Histol* 12 (2021): 585.