

Determining the Ossification Status of Sternal End of the Clavicle using CT and Digital X-ray: A Comparative Study

Gakhar GK^{1*}, Gupta V¹, Jasuja OP² and Khandelwal N²

¹Department Radiodiagnosis and imaging, P G I M E R, Chandigarh, India

²Punjab University, Patiala, Punjab, India

Abstract

Objective: Age criterion in case of livings plays an important role in clarifying the issues concerning legal and social aspect. An additional assessment of medial clavicular epiphysis by X-ray or CT examination helps in criminal proceedings to ascertain the age of suspect above 18 years, if skeletal development of hand is complete. A comparative study was conducted using two radiological techniques i.e. digital Radiography and CT scan to find out the preferred technique for finding the accurate clavicular ossification status for forensic age diagnostics in living subjects above 18 years of age.

Material and method: CT scan images and digital X-rays of a patient population of 100 individuals falling in the age group of 13-30 years (originally preformed for their respective diagnostic purpose) were retrospectively examined for finding the ossification status of clavicle.

Results: It was found that CT scan permitted the evaluation in all the subjects included in the study, but the evaluation was not possible in 6% of the sample with digital X-rays and the results of both modalities were not concordant in 18.5% of the evaluated sample.

Conclusion: It was concluded that CT scan is the better modality for finding the ossification stages of medial clavicular epiphysis, as the interpretation was easier and the target area could be visualized without the superimposition of other bones in all the cases.

Keywords: Ossification; Computed tomography; Digital X-ray; Resolution

Introduction

Age estimation in case of living individuals is generally needed for clarifying the issues with significant legal and social ramification for individuals as well as community in situations which can be criminal as well as civil [1]. It is also required in developing countries where births are not always recorded properly [2] to ascertain that whether a defendant of questionable age has attained the age of criminal responsibility and applying general criminal law for adults is justified in that case [3].

According to the updated recommendations of 'Study group on age diagnostics for criminal proceedings', in order to increase the accuracy of age estimation examination, the basic examinations to be performed are, firstly, general physical examination, secondly, X-ray of hand and thirdly, odontological examination by dentist for dental status and orthopantomogram. To assess the age of a person above 18 years, an additional assessment of the medial clavicular epiphyses by X-ray or computed tomography (CT) is recommended if skeletal development of hand is complete [4,5].

Medial clavicular ossification is of particular interest in establishing whether an individual has attained the criminal liability threshold age of 21 years. There are several radiological imaging techniques like conventional X-ray, CT, magnetic resonance imaging (MRI) and ultrasound which have been employed so far to study the clavicular ossification status [3,6-15]. Conventional radiography has been successfully employed in this context in some studies [6-8], but the major problems faced in using this technique were suboptimal image quality and misinterpretation due to the overlapping of other skeletal parts like ribs, vertebrae and mediastinal soft tissue structures. Ultrasound is an easily assessable and radiation-free imaging technique, but it is operator

dependent and it is not easy to re-evaluate stored images. MRI is another radiation-free modern imaging tool, especially useful in under-aged or young patients, but it is costly as well as time-consuming and it also provides lower resolution in region of the epiphysis using standard MR protocols. This is because the MRI of this region is compromised by many factors such as motion artifacts from respiration or pulsations and hence, long duration sequences (high resolution sequences) are not generally used in this region due to motion artifacts. Computed Tomography has a very short scan time and it acquires high resolution data in a single breath hold. Thus all these problems (overlapping in X-ray and spatial resolution in MRI) were found to be eliminated by using computed tomography in some modern studies [3,9-12]. CT also provides vastly better anatomical details of bony structures. A comparative study for the assessment of medial clavicular ossification status using conventional radiography and CT scan of sterno-clavicular joints was conducted by Schutz et al. [11] for forensic age estimation in 57 individuals undergoing criminal proceedings. Reliable assessment of ossification stage was not possible with conventional X-rays in 15 out of 114 clavicles. Results were found to be different in 2 clavicles, owing to suboptimal quality and misinterpretation due to overlapping of other

***Corresponding author:** Gakhar GK, Department of Radio diagnosis, P G I M E R, Chandigarh, India, Tel: +91-9417779850; E-mail: gurdeep_suresh35@rediffmail.com

Received January 14, 2014; **Accepted** February 18, 2014; **Published** February 28, 2014

Citation: Gakhar GK, Gupta V, Jasuja OP, Khandelwal N (2014) Determining the Ossification Status of Sternal End of the Clavicle using CT and Digital X-ray: A Comparative Study. J Forensic Res 5: 223 doi:[10.4172/2157-7145.1000223](https://doi.org/10.4172/2157-7145.1000223)

Copyright: © 2014 Gakhar GK, et al. This is an open-access article distributed under the terms of the Creative Commons Attribution License, which permits unrestricted use, distribution, and reproduction in any medium, provided the original author and source are credited.

Staging with CT	Staging with DR					Total
	Stage 1	Stage 2	Stage 3	Stage 4	Stage 5	
Stage 1	11	0	0	0	0	11
%within CT	100%	0%	0%	0%	0%	100%
% of total						11.3%
Stage 2	1	7	1	0	0	9
%within CT	11.1%	77.8%	11.1%	0%	0%	100%
% of total						9.3%
Stage 3	0	4	22	2	3	31
%within CT	0%	12.9%	71.0%	6.5%	9.7%	100%
% of total						32%
Stage 4	0	0	2	26	6	34
%within CT	0%	0%	5.9%	76.5%	17.6%	100%
% of total						35.1%
Stage 5	0	0	0	2	10	12
%within CT	0%	0%	0%	16.7%	83.3%	100%
% of total						12.4%
Total count	12	11	25	30	19	97
% Total	12.4%	11.3%	25.8%	30.9%	19.8%	100%

(Foot note for understanding the contents of tables 3 and 4): Blue color shows over estimation in staging with DR in comparison with CT and red color coding shows under estimation in the similar way.)

Table 1: Comparative results for right clavicles with CT and DR.

Staging with CT	Staging with DR					Total
	Stage 1	Stage 2	Stage 3	Stage 4	Stage 5	
Stage 1	10	0	0	0	0	10
%within CT	100%	0%	0%	0%	0%	100%
% of Total						11.0%
Stage 2	2	7	1	0	0	10
%within CT	20.0%	70.0%	10.0%	0%	0%	100%
% of Total						11.0%
Stage 3	0	2	24	1	1	28
%within CT	0%	7.1%	85.7%	3.6%	3.6%	100%
% of Total						30.8%
Stage 4	0	0	2	26	5	33
%within CT	0%	0%	6.1%	78.8%	15.2%	100%
% of Total						36.3%
Stage 5	0	0	0	2	8	10
%within CT	0%	0%	0%	20.0%	80.0%	100%
% of Total						11.0%
Total count	12	9	27	29	14	91
% Total	13.2%	9.9%	29.7%	31.9%	15.4%	100%

(Foot note for understanding the contents of tables 3 and 4): Blue color shows over estimation in staging with DR in comparison with CT and red color coding shows under estimation in the similar way.)

Table 2: Comparative stages for left clavicles with CT and DR.

structures. This is the only comparative study of its kind found so far in published literature, where two techniques are used (CT as well as X-ray) in same subjects.

Present study has also been carried out to compare the results of medial clavicular ossification stages using two radiological methods i.e. digital X-ray (DR) and CT in same subjects, coincidentally been performed on same day. The study has been performed in larger subject size (N=100) as compared to the previously mentioned comparative study [11]. The purpose of this study was to find out the preferred technique for finding accurate clavicular ossification status for performing forensic age diagnostics in living subjects above 18 years of age.

Materials and Methods

A retrospective study of CT scans and digital X-rays of a patient population of 100 individuals (55 male and 45 female) falling in the age group of 13-30 years was carried out to access the ossification status of bilateral clavicles. CT scan and digital X-ray of thorax of these patients were coincidentally preformed on the same day for their respective diagnostic purposes in between 2008-2010. The study was aimed to compare the staging results of medial clavicular ossification found with these two modalities. Institutional ethical clearance was obtained prior to the study.

CT parameters

CT thorax in all the subjects was performed on 16-row MDCT scanner (Siemens Sensation-16, Siemens Medical Solution, Forchheim, Germany) using the following technical parameters---KVp (kilo-volt)-120, mAs (milli Amperes × seconds)-150, pitch factor-1.15, rotation time 0.5 second and slice collimation 1.5×16 . The raw data was reconstructed in 2 mm thick slices from the region of bilateral sterno-clavicular joints at bone window using a sharp kernel (filter, B60f).

Digital X-ray parameters

Digital X-ray of chest (Posterior-anterior or PA view) of each one of the subjects was also performed on a flat panel detector (Philips Healthcare, Digital Diagnost Optimus-50, Hamburg, Germany) digital radiographic system using high KV technique (120 KVp) and AEC (Automatic Exposure Control) technique for automatic adjustment of mAs according to the requirement.

Evaluation criterion

The ossification stages of the medial clavicular epiphyseal cartilage were categorized on the basis of classification criterion used by Schmeling et al. [7].

Stage 1 ---- Ossification centre has not yet ossified.

Stage 2 ---- Ossification centre has been ossified, but epiphyseal cartilage not ossified.

Stage 3 ---- Epiphyseal cartilage partially ossified.

Stage 4 ---- Epiphyseal cartilage completely ossified, but epiphyseal scar is still visible.

Stage 5----- Epiphyseal scar is no longer visible.

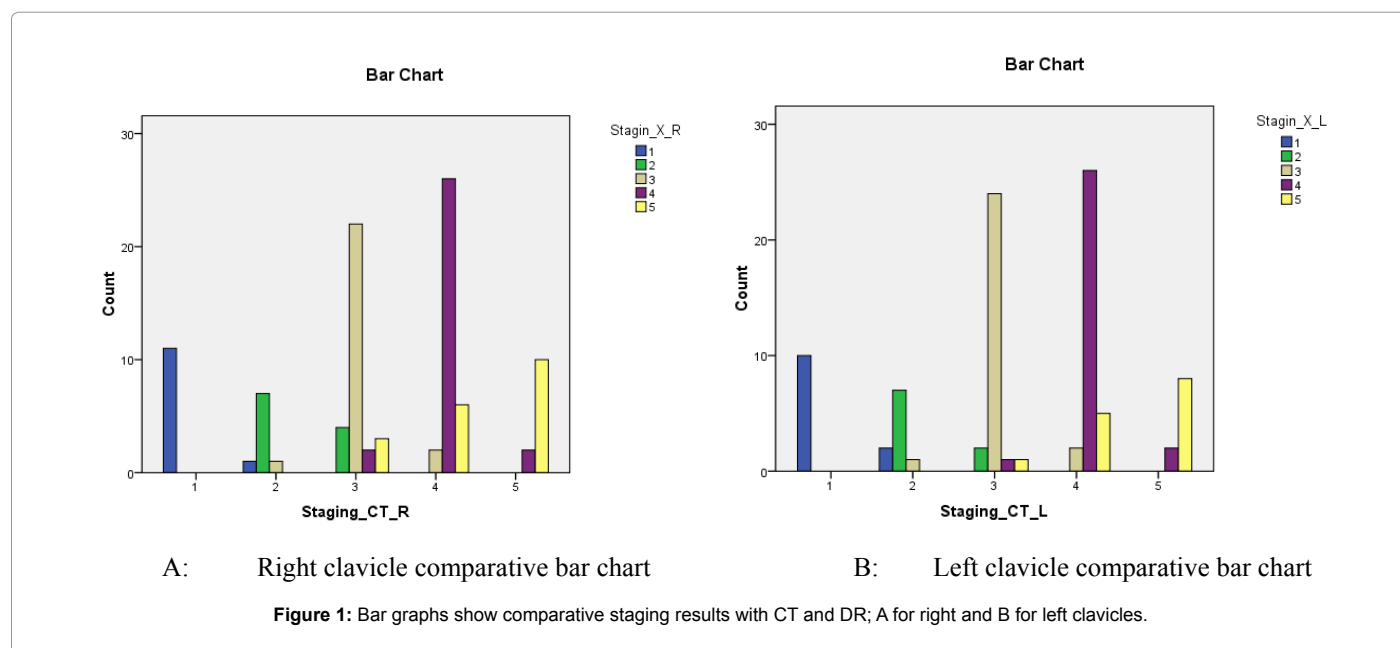
The data was interpreted for staging by a Ph.D senior research fellow with the help of an anthropologist and cross-examined for the same by two radiologists; one having 7 years of reporting experience and other having more than 20 years of experience. We all were blinded to the age and sex of the subjects while interpreting the stages of ossification. The raters were also blinded to the other rater's results. The ossification stages were evaluated separately for both right and left clavicles in each subject. The percentage of data interpretable with both the modalities was evaluated statistically (using software – SPSS, version 17.0). The correlation between the results of both the modalities (CT and DR) was calculated statistically by 'Spearman's Rank correlation', as staging was done independently for both CT and DR. The comparative results by CT and DR are also evaluated and compiled in Tables 1 and 2 separately for right and left clavicle. The agreement level in their results was evaluated by calculating another statistical parameter 'Kappa' separately for both the clavicles.

Feasible Interpretation performed with both the modalities		
Side	DR	CT
Right	97 (97%)	100 (100%)
Left	91 (91%)	100 (100%)
Total	188 (94%)	200 (100%)

Table 3: Determination of ossification stages with CT and digital x-ray (DR).

Stage-wise distribution with CT and DR (% proportion)										
Clavicles	Stage 1		Stage 2		Stage 3		Stage 4		Stage 5	
	CT	DR	CT	DR	CT	DR	CT	DR	CT	DR
Right	11%	12%	9%	11%	33%	25%	35%	30%	12%	19%
Left	11%	12%	10%	9%	34%	27%	33%	29%	12%	14%

Table 4: Stage-wise distribution of subjects (100 right+100 left clavicles) with CT and DR.



Results

Total 100 subjects were included in the study. The average age in age range of 13-30 years was found to be 22.34 years. In all the subjects bilateral clavicles were evaluated for staging. CT images permitted the successful evaluation of ossification stages in all the subjects for both the clavicles, but the ossification stages were not interpretable from digital X-ray in 3 subjects for right clavicles and in 9 subjects for left side clavicle (Tables 3 and 4). Data could not be interpreted for staging with DR in 3% of sample for right side and 9% for left side.

Comparison of the results with CT and DR

Comparison showing agreement as well as disagreement found in the staging results with both the modalities are elaborated in Tables 1 and 2 and also demonstrated in [Figures 1a and 1b].

Thus, the results were not in agreement in 37 clavicles with both the modalities among the entire evaluated sample of 188 clavicles covering 18.5% of the sample. Symmetric measures of biostatistics were calculated by applying Chi-square test to find out the Spearman's Rank Correlation and measure of agreement between the results. The value of 'Spearman's Rank Correlation' was found to be positive ('R'=0.872 for right clavicles and 0.919 for left clavicles) indicating a positive relationship between them. The results were also found in substantial agreement [16] for

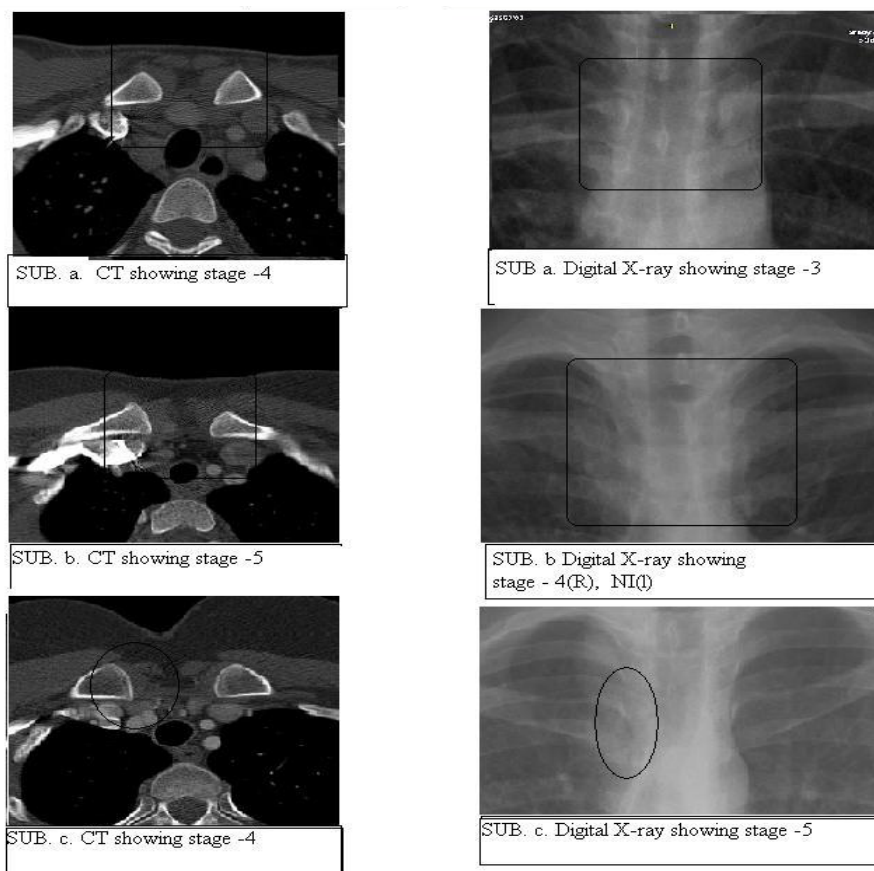
both sides of clavicular ossification stages ('Kappa'=0.715 for right clavicles and 'Kappa'=0.766 for left clavicles).

Correlation of ossification stages with age as revealed by CT in 100 (55 male+45 female) subjects

The stage 2 in the data analyzed from CT first appeared at the age of 14 years in females while 15 years in case of male subjects. Stage 3 in both the sexes appeared at 17 years of age while stage 4 was first observed at the age of 20 years in female subjects and at the age of 21 years in males. Stage 5 appeared at 25 years in females and 26 years in male subjects. The ossification stages analyzed with DR (digital X-ray) were found to be different from those analyzed with CT scan in 15 cases for bilateral clavicles and in 3 cases for unilateral clavicle (2 for right and 1 for left) among all those evaluated (188 clavicles) successfully with both the modalities (Figures 2 and 3).

Discussion

This is yet to be answered which is the most suitable and accurate method of finding the medial clavicular ossification status among all successfully used techniques. The degree of ossification was studied by Jit and Kulkarni using radiographic technique and some of their queries and difficulties regarding staging have been clarified by them using some anatomical samples [6]. A similar study was conducted by



NI stands for not interpretable for staging.

Figure 2: Same subjects (subject a, subject b and subject c) presenting with different results with CT and DR.

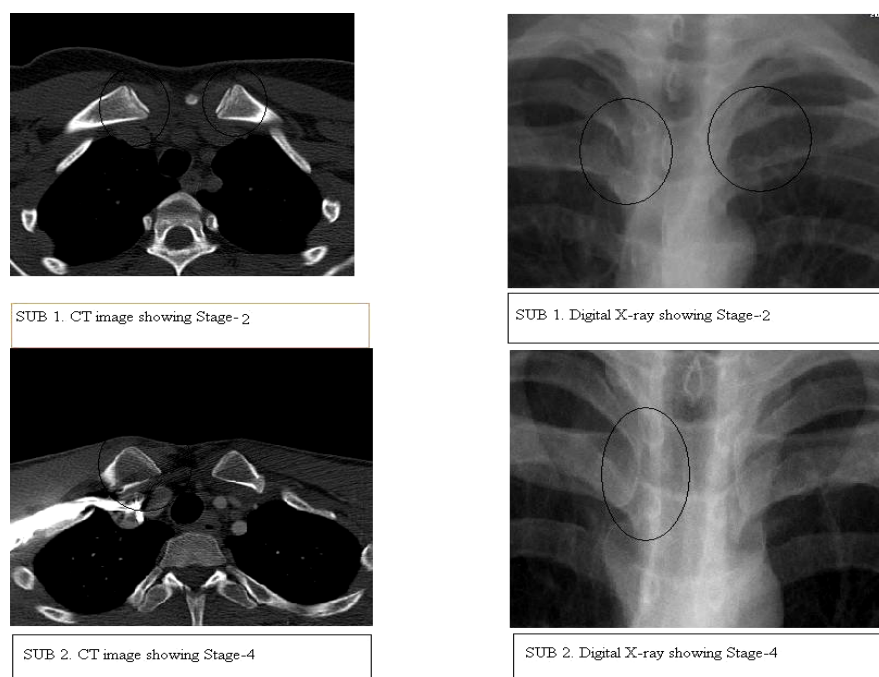


Figure 3: Subjects: 1 and 2 show same staging results on CT as well as DR.

Schmeling et al. [7] retrospectively analyzing the plain chest radiographs of 873 subjects. The reliable assessment of the degree of ossification of the medial clavicular epiphyseal cartilage in 174 out of 873 X-rays was found impossible on both sides due to overlap or some other factors [7].

Kreitner et al. [9] suggested CT as better modality in providing vastly better visualization of fine details of anatomical structures, but they have not performed comparative ossification staging with both the modalities in the same patients. The conventional radiographs are often suboptimal probably due to inaccurate technical factors and the processing of films. This is eliminated in present study by using digital radiographs which are advantageous in modifying the quality of the image by post processing according to the requirement. High latitude images with edge enhancement technique are good to facilitate the dominated view of bones which can be achieved by window leveling/reconstruction on DR. In spite of this misinterpretation due to overlapping of other tissues could not be rectified. All these problems are eliminated with the use of CT in present study.

CT is technically very good for anthropological assessment, but bears the risk of health damage by radiations. A typical thoracic CT scan can give a radiation dose approximately 15 to 70 times higher than single view (posterior-anterior) of chest X-ray, depending on the CT scan protocols (low dose i.e. 1.5 mSv or high dose i.e. 7 mSv) used. The risk of radiation-induced cancer is estimated to be higher in infants and children and lower in the elderly patients. Although CT provides useful information, referring physicians should be aware of the associated radiation risk and need for judicious use. It is at present not clear what radiological method should be used to assess the ossification status of the medial clavicular epiphysis. Although, CT has been discussed to provide better image quality, but radiation dose is considerably higher than other radiographic methods.

Comparative study of medial clavicular ossification staging using conventional radiographs and CT scan in the same patients was conducted by Schulz et al. [11] among 57 living subjects (53 males and 4 females) above 18 years of age. The reliable assessment of ossification status was not possible in 15 out of 114 (57 × 2) clavicles while results were not found in agreement in 2 out of total 99 assessed clavicles with both the modalities. In both the cases divergent results were found in right clavicular ossification status which was classified as stage 2 by CT and stage 3 by conventional X-ray. But in present study the interpretation was not possible in 12 (3 right and 9 left) out of total 200 clavicle (100 bilateral) with DR and the results were divergent in 37 clavicles (21 right and 16 left) out of total 188, due to overlapping of ribs and vertebrae. Schulz et al. [11] have used conventional radiographs in their study whereas we have used digital radiography. In CT, the only difference found in used parameters was that of slice thickness i.e. 1 mm in their study and 2 mm in our study. They found difference in results with CT and X-rays in analyzing stage 2 and 3, although difficulty in interpretation has also been faced in present study in analyzing stage 1 and 2 in 3 clavicles (1 right and 2 left), stage 2 and 3 in 8 clavicles (5 right and 3 left) clavicles, stage 3 and 4 in 7 clavicles (4 right and 3 left), between stage 4 and 5 in 15 clavicles (8 right and 7 left) and stage 3 and 5 in 4 clavicles (3 right and 1 left).

While comparing the published data of CT based study [10] with that of conventional radiography based study [8], the age correlation with regard to stage 5 can be problematic, as this stage was reported 5 years earlier by CT study than that in the corresponding conventional radiography study. But in the later study by Kellinghaus et al. [12], the onset of stage 5 i.e. 26 years of age was found concordant with the data of conventional radiography and greater slice thickness was

stated as the reason behind this [10]. Although Muller et al. [17] has shown that 1 mm is the most ideal slice thickness in CT for attaining maximum accuracy, 2 mm slice thickness has been used in present study presuming that the chances of error while analyzing ossification stages at 2 mm slice thickness are reduced to minimum [18].

The image generation technique in both the modalities is different as X-ray (conventional or digital) gives two dimensional information, but CT provides the proper visualization of three dimensional structures lying in parallel planes in form of axial slices. Multi-planer reconstruction (MPR) and curved reconstruction for proper assessment of ROI (region of interest) in CT is helpful in providing 3D view of structures, but DR can be 2D only. One advantage of conventional or digital radiography over CT is its higher resolution, but superimposition of other skeletal structures is however a major disadvantage for preventing the proper assessment of ossification status. CT is therefore considered as preferred technique for analyzing the three dimensional structures without superimposition.

The purpose of this study was comparative analysis of the performance of these two modalities in the assessment of clavicular ossification status. Because of superimposition the staging of clavicular epiphyseal ossification in 12 clavicles out of 200 (100 bilateral) could not be assessed with digital radiography and results were not identical in 37 clavicles out of 188 assessed successfully with both CT and digital X-ray. The difference in results in CT and DR could be explained by different techniques, one being cross-sectional and other being 2 dimensional. However, image read-out was only performed on PA view of DR which could also have contributed to the differences in the results. So, we support the conclusion made by Schulz et al. [11], that the reference data from CT studies should be used for ossification stage classification from CT for forensic age estimation purpose and that of radiography should be used for the evaluation of stage from radiograph. The bar graph of the comparative study shows that disagreement in staging results with CT and digital X-ray was found for both the sides (right as well as left) in all the 5 stages. Symmetric measures of biostatics shows that the results of ossification stages with both the modalities have positive and significant relationship (Spearman's Rank Correlation 'R' positive and ≥ 0.5). The agreement level in their results has been found to be substantial (value of Kappa ≤ 0.8) [16].

Conclusion

It can be concluded in the present study:

The reliable assessment of medial clavicular ossification was not possible in 6% of sample with DR due to superimposition of other bony structures, whereas CT was found perfect in providing assessment in 100% sample.

As the results were not identical for CT and digital radiography in 18.5% of the sample, it is therefore essential to use the reference data of radiographic study for evaluating ossification stage from radiography and that of CT based study for evaluating the same from CT.

The recommended slice thickness for CT based study should not exceed more than 2 mm.

Recommendation

To make a recommendation concerning the method of choice for the assessment of clavicular ossification:

CT can be stated as beneficial and superior technique in providing successful evaluation in all cases without superimposition as far as single view radiography is concerned, as per the results of present study.

Though CT bears the risk of exposing the tissue with comparatively higher radiation dose and DR gives less radiation dose to young adults if the problem of overlapping by other thoracic bones is solved by using multiple views, as only posterior-anterior view in DR is used for the evaluation of ossification status in present study.

A study must be conducted by evaluating the same in other views in other 2 planes also i.e. left and right anterior oblique views to see whether the problem of superimposition can be eliminated.

References

1. Ritz-Timme S, Cattaneo C, Collins MJ, Waite ER, Schütz HW, et al. (2000) Age estimation: the state of the art in relation to the specific demands of forensic practise. *Int J Legal Med* 113: 129-136.
2. Schmeling A, Olze A, Reisinger W, Rösing FW, Geserick G (2003) Forensic age diagnostics of living individuals in criminal proceedings. *Homo* 54: 162-169.
3. Schulze D, Rother U, Fuhrmann A, Richel S, Faulmann G, et al. (2006) Correlation of age and ossification of the medial clavicular epiphysis using computed tomography. *Forensic Sci Int* 158: 184-189.
4. Schmeling A, Grundmann C, Fuhrmann A, Kaatsch HJ, Knell B, et al. (2008) Criteria for age estimation in living individuals. *Int J Legal Med* 122: 457-460.
5. Schmeling A, Geserick G, Kaatsch HJ, Marré B, Reisinger W, et al. (2001) [Recommendations for age determinants of living probands in criminal procedures]. *Anthropol Anz* 59: 87-91.
6. Jit I, Kulkarni M (1976) Times of appearance and fusion of epiphysis at the medial end of the clavicle. *Indian J Med Res* 64: 773-782.
7. Schmeling A, Schulz R, Reisinger W, Mühler M, Wernecke KD, et al. (2004) Studies on the time frame for ossification of the medial clavicular epiphyseal cartilage in conventional radiography. *Int J Legal Med* 118: 5-8.
8. Flecker H (1932) Roentgenographic Observations of the Times of Appearance of Epiphyses and their Fusion with the Diaphyses. *J Anat* 67: 118-164.
9. Kreitner KF, Schweden FJ, Riepert T, Nafe B, Thelen M (1998) Bone age determination based on the study of the medial extremity of the clavicle. *Eur Radiol* 8: 1116-1122.
10. Schulz R, Mühler M, Mutze S, Schmidt S, Reisinger W, et al. (2005) Studies on the time frame for ossification of the medial epiphysis of the clavicle as revealed by CT scans. *Int J Legal Med* 119: 142-145.
11. Schulz R, Mühler M, Reisinger W, Schmidt S, Schmeling A (2008) Radiographic staging of ossification of the medial clavicular epiphysis. *Int J Legal Med* 122: 55-58.
12. Kellinghaus M, Schulz R, Vieth V, Schmidt S, Schmeling S (2010) Forensic age estimation in living subjects based on the ossification status of the medial clavicular epiphysis as revealed by thin-slice multidetector computed tomography. *Int J Legal Med* 124: 149-154.
13. Schmidt S, Mühler M, Schmeling A, Reisinger W, Schulz R (2007) Magnetic resonance imaging of the clavicular ossification. *Int J Legal Med* 121: 321-324.
14. Schulz R, Zwiesigk P, Schiborr M, Schmidt S, Schmeling A (2008) Ultrasound studies on the time course of clavicular ossification. *Int J Legal Med* 122: 163-167.
15. Quirnbach F, Ramsthaler F, Verhoff MA (2009) Evaluation of the ossification of the medial clavicular epiphysis with a digital ultrasonic system to determine the age threshold of 21 years. *Int J Legal Med* 123: 241-245.
16. Dawson B, Trapp RG (2004) Basic and clinical biostatistics. (4th edn), Mc Graw Hill 118-119.
17. Mühler M, Schulz R, Schmidt S, Schmeling A, Reisinger W (2006) The influence of slice thickness on assessment of clavicle ossification in forensic age diagnostics. *Int J Legal Med* 120: 15-17.
18. Kaur Gurdeep, Khandelwal N, Jasuja OP (2010) Computed tomographic studies on ossification status of clavicle: Effect of slice thickness and dose distribution. *J Indian Acad Forensic Med* 32: 298-302.