

Determination of Sex by Applying Discriminant Function Analysis on the Linear Measurements of the Mental and Mandibular Foramen using OPG-A Retrospective Study

Sukanya Desingurajan*

Department of Oral Medicine and Radiology, Dental College And Hospital, Bengaluru, Karnataka, India

Abstract

Disaster may be caused by natural events such as severe flooding, earthquake or volcanic eruptions. It can also be due to human activities such as mishaps involving mass transport by Land Sea, air and other causes include war, boundary disputes. Identification of individual victims by devital means is one of the most reliable methods. In case of severe disintegration visual recognition of facial features and finger prints are often impossible due to soft tissue destruction. This situation necessitates the use of the hard calcified tissue such as human dentition and jaws, pelvis and skull.

Keywords: Reliable methods • Soft tissue destruction • Human dentition • Visual recognition

Introduction

Skull is the important and dimorphic portion for sexual identification after pelvis. In certain cases when the entire skull is not available mandible plays important role in gender determination [1]. Hence, the morphological features of the mandible are commonly used by forensic specialists in determining sex. Sex determination from skeletal remains is an important aspect of the osteologic analysis of a given population [2,3]. During mass disaster as gender identification is the first step followed by the age and stature, as age and stature are gender dependent [4].

Among many anatomical landmarks, mental foramen and mandibular foramen are stable landmark, hence they are used in morphometric analysis

Orthopantomogram is widely used as the image of the full mouth is obtained in a single film with relatively less exposure, time and cost. Vertical and Horizontal bony dimensions of anatomical structures are also obtained, hence, it can be applied in forensic medicine with the utilization of portable units. This approach is less time-consuming and allows the extra-oral examination of the dental status [5].

This study is carried out to determine sex by applying discriminant function analysis on the linear measurements of the mental and mandibular foramen using OPG.

Materials and Methodology

Sample size estimation

The sample size has been estimated using the GPower software v. 3.1.9.2

Considering the effect size to be measured (d) at 65%, power of the study at 80% and the margin of the error at 5%, the sample size obtained is 78. Rounding off the sample size to 80. So, each study group will comprise of 40 samples [40 samples into 2 groups = 80 samples] (Figure 1).

***Address for Correspondence:** Sukanya Desingurajan, Department of Oral Medicine and Radiology, Dental College And Hospital, Bengaluru, Karnataka, India, E-mail: drsukanyasri@gmail.com

Copyright: © 2021 Desingurajan S. This is an open-access article distributed under the terms of the Creative Commons Attribution License, which permits unrestricted use, distribution, and reproduction in any medium, provided the original author and source are credited.

Received 05 November 2021; **Accepted** 19 November 2021; **Published** 26 November 2021

Input: Tail(s)	=	Two
Effect size d	=	0.65
α err prob	=	0.05
Power (1- β err prob)	=	0.80
Allocation ratio N2/N1	=	1
Output: Noncentrality parameter δ	=	2.8703223
Critical t	=	1.9916726
Df	=	76
Sample size group 1	=	39
Sample size group 2	=	39
Total sample size	=	78
Actual power	=	0.8089174

Figure 1. This formula has proved to be significant in the examined sample.

Materials

A retrospective study was performed in department of oral medicine and radiology, VSDCH (Figure 2). The sample size includes 80 panoramic radiographs of 40 males and 40 females of age 29-59 years were included in the study. These patients were evaluated according to gender; they were divided into four groups according to age;

- First group: Subjects from (20-29) years of age (10 males and 10 females);
- Second group: Subjects from (30-39) years of age (10 males and 10 females);
- Third group: Subjects from (40-49) years of age (10 males and 10 females);
- Fourth group: Subjects from (50-59) years of age (10 males and 10 females).

Ideal OPG of completely dentate patients with clear visible mandibular borders, condyle, ramus, mental and mandibular foramen were selected for study.

Radiographs with artefacts or other lesions which interfere with mental foramen on radiographs fractured, developmental disturbances of the mandible, deformed, completely edentulous mandible and patients below 20 years of age were excluded from the study.

Panoramic image was taken for each patient using Sirona digital X-ray machine.

Images were examined on the monitor, and the resolution was enhanced to optimum. The selected radiographic images were used for making linear measurements on images of the mandibular jaw. Four linear vertical measurements (D1, D2, D3, and D4) were performed on all radiographic images according to [6].

These measurements were done on the right and left sides of the mandible image. Measurements were taken on both the sides of the mandible.

The following measurements were taken, (Figure 2).

D1: Vertical distance from the most inferior point on the mental foramen to the inferior most point on the base of the mandible.

D2: Vertical distance from the most superior point on the mental foramen to the superior most point of THE alveolar crest.

D3: Vertical distance from the most inferior point of the mandibular notch to the most superior point on the mandibular foramen.

D4: Vertical distance from the most inferior point of the mandibular notch to the inferior edge of the mandibular ramus.

The data obtained were tabulated and subjected to discriminant function analysis.

Statistical analysis

Statistical Package for Social Sciences [SPSS] for Windows, Version 22.0. Released in 2013. Armonk, NY: IBM Corp. Was used to perform statistical analyses.

Inferential statistics: Independent Student t Test was used to compare the mean linear measurements at different points on Right and left Sides between males and females. Similar comparisons were performed based on the different age groups.

Student Paired t Test was used to compare the mean linear measurements at different points between Right & Left sides among Males and Females.

Averages were calculated from right & left sides for males & females with respect to different study variables to perform Step-wise discriminant function analysis for Gender Prediction

The level of significance [P-Value] was set at P<0.05.

Discriminant function analysis for the linear measurements of the mental & mandibular foramen for gender discrimination was performed.

As per the analysis outcomes, D1, D2 & D4 were considered has the strong significant predictors for gender prediction. The Unstandardized canonical coefficients for the same were 0.41, 0.19 & 0.07 respectively.

The unstandardized and standardized coefficients, structure matrix, group centroids, and sectioning point for the discriminant function are

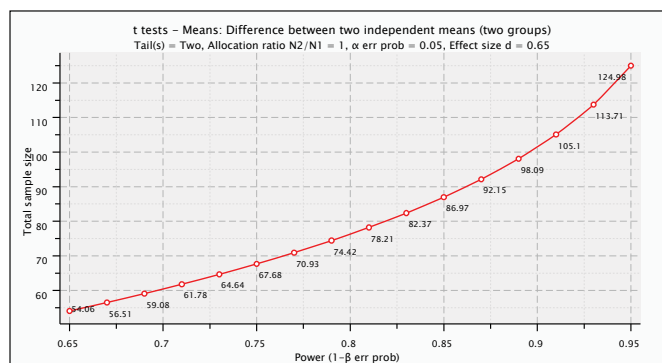


Figure 2. Power analysis curve.

Table 1. Comparison of mean linear measurements at different points on right side between males and females using independent student t test.

Variables	gender	N	Mean	SD	Mean diff	P-value
D1	Males	40	14.7	1.96	2.15	<0.001*
	Females	40	12.55	1.48		
D2	Males	40	19.81	2.68	1.85	0.002*
	Females	40	17.96	2.48		
D3	Males	40	17.75	3.56	1.6	0.04*
	Females	40	16.15	3.09		
D4	Males	40	57.54	4.84	5.17	<0.001*
	Females	40	52.38	4.67		

P value< 0.05 is considered as statistically significant

* - Statistically Significant

Table 2. Comparison of mean linear measurements at different points on left side between males and females using independent student t test.

Variables	gender	N	Mean	SD	Mean diff	P-value
D1	Males	40	14.85	2.08	2.18	<0.001*
	Females	40	12.67	1.79		
D2	Males	40	19.85	2.9	2.43	<0.001*
	Females	40	17.42	2.89		
D3	Males	40	17.48	3.37	1.77	0.02*
	Females	40	15.71	2.96		
D4	Males	40	56.68	4.88	4.04	<0.001*
	Females	40	52.65	5.03		

P value< 0.05 is considered as statistically significant

* - Statistically Significant

provided in Table 1. To predict the gender of an unidentified individual, the linear measurements is correspondingly multiplied with the respective unstandardized coefficient and added to the constant. If the value obtained is greater than the sectioning point, the individual is considered as Male; if the value obtained is less than the sectioning point, the individual is considered as Female.

The Gender Prediction equation from the study sample can be quoted as follows:Figure 3.

The Predicted gender model showed a high sensitivity of 82.5% and specificity of 85.0% and the overall accuracy of 83.8% of grouping correctly the originally grouped cases.

Results and Discussion

In the present study, we tried to establish the distance between mental foramen, mandibular foramen and lower border of mandible as an indicator for sex estimation. The mandible is one of the strongest bone in the body and stays in a well preserved state for a long period [7-9]. Stated that in spite of resorption of alveolar bone above the mental foramen the distance from a mental foramen to the alveolar crest remains constant studies [10]. On mandible have proved the importance of mandible in sex determination.

It was noticed that sexual differences were more in mandibular ramus height proving its significance in sex determination when compared to the body of the mandible [11].

The measurements of the means of D1, D2, D3, D4 between males and females in all the age groups (Table 2). The means of D1, D2, D3, and D4 in all the age groups was higher in males and this was coinciding with the studies [6,12-17]. Indicating that the vertical measurements from mandibular and mental foramen are potent indicators for sex determination and useful in differentiating male gender from female (table 2).

A study conducted in India found sexual dimorphism in the distances from superior and inferior border of the mental foramen to the lower border

of the mandible. Height of the mandible was also found to have sex related differences in the study. The mean values of the D1 and D2 in males and female subjects showed significant differences in our study and the values are higher in male subjects and were in accordance with the previous studies. Another study done by discriminant functional analysis for sex determination using other morphometric variables in the mandible.

Sectioning point is one of the features of the present study by using four different variables. The Predicted gender model showed a high sensitivity of 82.5% and specificity of 85.0% and the overall accuracy of 83.8% of grouping correctly the originally grouped cases.

Conclusion

Results revealed differences between the genders in all of the four measurements in the sampled population. This study has derived an equation for the gender prediction. Further studies are required including subjects from different race and ethnicity to validate the relevance of the study in larger populations.

Acknowledgement

Conflict of interest

Nil.

References

- Molina, Julian R., Ping Yang, Stephen D. Cassivi, Steven E. Schild, and Alex A. Adjei. "Non-Small Cell Lung Cancer: Epidemiology, Risk Factors, Treatment, and Survivorship." *Mayo clin proc* 83(2008): 584-594.
- Matsuzaki, Tatsu, Eri Iwami, Kotaro Sasahara, and Aoi Kuroda, et al. "A Case Report of Metastatic Lung Adenocarcinoma with long-Term Survival for Over 11 Years." *Med* 98 (2019): 360.
- Ishikawa, Takuya, Yoshiki Hirooka, Carolin J Teman, and Hidemi Goto, et al. "An Unusual Case of Pancreatic Metastasis from Squamous Cell Carcinoma of the Lung Diagnosed by EUS-Guided fine Needle Biopsy." *Case Rep in gastrointestMed* 2017 (2017).
- Fujii, Masakuni, Kazuhiko Watanabe, Masafumi Kataoka, Soichiro Nose, and Junji Shiode. "A Case of a Pancreatic Tumor that Was Diagnosed as Metastasis from Lung Cancer by Endoscopic Ultrasound-Guided fine Needle Aspiration." *J Med Ultrasonics* 42 (2015): 405-408.
- Kyriazi, Maria A, Sofoudis Chrisostomos, Katsouri Maria, and Kappos Theocharis, et al. "Acute Cholangitis Due to Pancreatic Metastasis from Squamous Cell Lung Carcinoma: A Case Report and Review of Literature." *Cases J* 2 (2009): 1-5.
- Liratzopoulos, Nikolaos, Efremidou Eleni I, Papageorgiou Michalis S, and Romanidis Konstantinos, et al. "Extrahepatic Biliary Obstruction Due to a Solitary Pancreatic Metastasis of Squamous Cell Lung Carcinoma. Case Report." *J Gastrointes Liver Dis* 15 (2006): 73.
- Machairas, Nikolaos, Paspala Anna, Schizas Dimitrios, and Ntomi Vasileia, et al. "Metastatic Squamous Cell Carcinoma to the Pancreas: Report of an Extremely Rare Case." *Mol Clin Oncol* 10 (2019): 144-146.
- Matt, Laurie, and Rajesh Sehgal. "Metastatic Non-Small-Cell Lung Cancer to the Liver and Pancreas." *Gastrointestcancer res* 7 (2014): 61.
- Soh, Rui Ya, Ho Chia Ming, Soo Kai Ling, and Low Su Ying. "Rare Metastatic Sites of a Lung Adenocarcinoma." *Cureus* 10 (2018): 62819.
- Popper, Helmut H. "Progression and Metastasis of Lung Cancer." *Cancer Metastasis Rev* 35 (2016): 75-91.
- Singh, Navneet, Madan Karan, Aggarwal Ashutosh N, and Das Ashim. "Symptomatic Large Bilateral Adrenal Metastases at Presentation in Small-Cell Lung Cancer: A Case Report and Review of the Literature." *J Thorac Dis* 5 (2013): E83.
- Tamura, Tomohiro, Kurishima Koichi, Nakazawa Kensuke, and Kagohashi Katsunori, et al. "Specific Organ Metastases and Survival in Metastatic Non-Small-Cell Lung Cancer." *Molecular and clinical oncology* 3 (2015): 217-221.
- Milovanovic, Ivana Savic, Stjepanovic Mihailo, and Mitrovic Dragan. "Distribution Patterns of the Metastases of the Lung Carcinoma in Relation to Histological Type of the Primary Tumor: An Autopsy Study." *Annals Thoracic Med* 12 (2017): 191.
- Showalter, Shayna L, Hager Eric, and Yeo Charles J. "Metastatic Disease to the Pancreas and Spleen." In *Seminars Oncol*, vol. 35 (2008): 160-171.
- Moazzam, Nauman, Mir Ali, and Anil Potti. "Pancreatic Metastasis and Extrahepatic Biliary Obstruction in Squamous Cell Lung Carcinoma." *Med Oncol* 19 (2002): 273-276.
- Kawai, Noriyasu, Tozawa Keiichi, Yasui Takahiro, and Moritoki Yoshinobu, et al. "Laparoscopic Adrenalectomy for Solitary Adrenal Metastasis from Lung Cancer." *J Soc of Laparoendoscopic Surgeons* 18 (2014).
- Tsuji, Yoshihiko, Yasuhuku Masao, Haryu Tomoki, and Watanabe Yoshihisa, et al. "Laparoscopic Adrenalectomy for Solitary Metachronous Adrenal Metastasis from Lung Cancer: Report of a Case." *Surge Today* 29 (1999): 1277-1279.

How to cite this article: Desingurajan, Sukanya. "A Determination of Sex by Applying Discriminant Function Analysis on the Linear Measurements of the Mental and Mandibular Foramen using OPG-a Retrospective Study." *J Forensic Res* 12 (2021): 482.