

## D Dimers can be Useful in EVAR Follow Up

Anantha K Ramanathan<sup>1\*</sup> and Mythily Ramanathan<sup>2</sup>

<sup>1</sup>Vascular Surgeon, Surgical Angiology Institute, PO Box 833, Wyong, NSW 2259, Australia

<sup>2</sup>Family Practice at Specialist Center, Hills Street, Gosford, NSW2250, Australia

\*Corresponding author: Anantha K Ramanathan, Vascular Surgeon, Surgical Angiology Institute, PO Box 833, Wyong, NSW 2259, Australia, Tel: +61447000950; E-mail: aram02@gmail.com

Received date: September 09, 2015; Accepted date: September 29, 2015; Published date: September 30, 2015

Copyright: © 2015 Ramanathan AK, et al. This is an open-access article distributed under the terms of the Creative Commons Attribution License, which permits unrestricted use, distribution, and reproduction in any medium, provided the original author and source are credited.

### Abstract

**Introduction:** D Dimer has been shown to be elevated in abdominal aortic aneurysms (untreated).

**Report:** An 80 year old man presented with left calf swelling. During the investigations to exclude deep vein thrombosis a very high level of D Dimer was noted. This prompted evaluation of his previous endovascular aneurysm repair (EVAR) graft when the duplex scan of the left lower extremity was normal. A large Type II endoleak was found. A further two patients with endoleaks had elevated D Dimers. In one of them the D Dimer level came down with resolution of endoleak.

**Conclusion:** D Dimer may play an important role in the follow up after EVAR. This new observation needs to be studied further in this setting.

### Key words:

EVAR; D Dimer; Endoleak; Duplex scan

### Report

An 80 year old man presented to his family physician with swelling of the left calf of one month duration. He had had deep vein thrombosis and varicose vein surgery in the same leg before, in the past. The patient had an Endo Vascular Aneurysm Repair (EVAR) for abdominal aortic aneurysm 6 years prior to this. This was complicated by a type 2 endoleak in 2011, which was treated successfully by onyx injection into the sac. He then had CT scans or duplex scan at 6 - 9 monthly intervals which showed that there was no recurrent endoleak and the sac size remained unchanged at 79 mm. The last scan was 9 months before this presentation.

In the past he had a right nephrectomy for cancer and a left renal artery stent placed for renal ostial stenosis. He also had treatment for carcinoma of the prostate.

The patient was a hypertensive and had hypercholesterolemia; he was an ex-smoker and not a diabetic. No other history or family history of note.

The patient was able to comfortably lie supine. His vital signs were normal. There were a right loin and bilateral groin scars. The large aneurysm was palpable but not tender. The left calf was swollen. All lower extremity pulses were palpable. The feet were well perfused.

Except for mild decrease in renal function the most marked abnormalities were a drop in Haemoglobin from 138 g/l to 126 g/l over 5 months and a markedly elevated D-Dimer level. Plasma D-Dimer was 7.8 mg/L (Ref Range was < 0.75 mg/L)

The initial duplex scan was negative for deep vein thrombosis. Subsequent duplex scan showed a large Type II endoleak with a significant enlargement of the sac size, to 9.58 cm (Figure 1).

Based on this scan the patient was referred for further treatment.

Subsequent to this there were two more patients with type II endoleak. In both of them the D Dimers were markedly elevated (over 5 mg/L). One of them showed spontaneous resolution of the endoleak. The D Dimer level too decreased in this patient, although still above normal range (Figure 2).

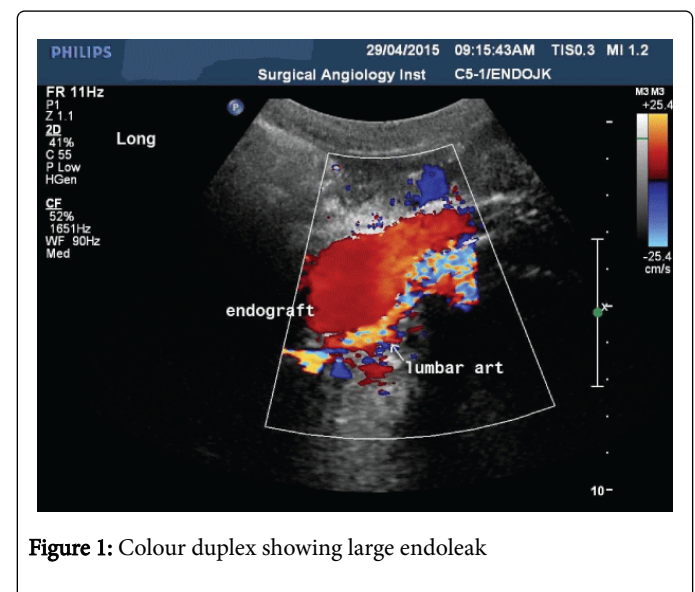


Figure 1: Colour duplex showing large endoleak

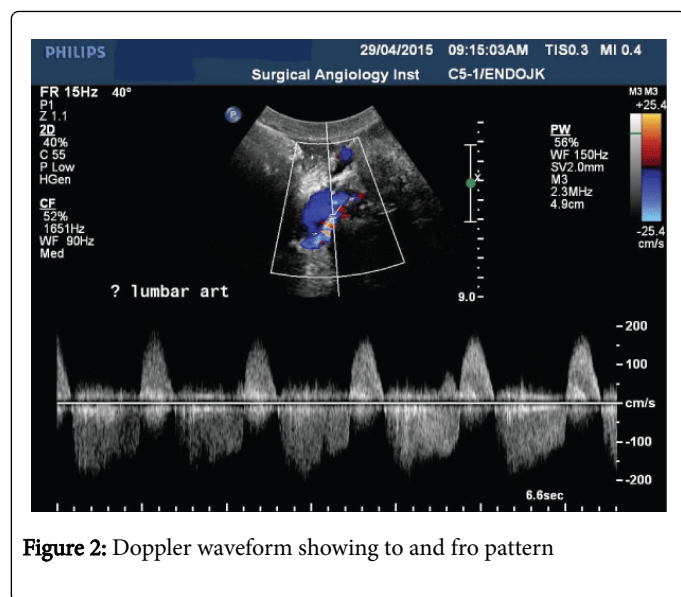


Figure 2: Doppler waveform showing to and fro pattern

## Discussion

This case and the subsequent two cases raise the possibility of D Dimers being elevated in patients with endoleak. This is a new finding. There are many causes for raised D Dimer level and the purpose of this note is not to present a complete case report but to flag the possibility that serial measurements of D Dimers may be useful in the follow up of patients after EVAR.

Type II endoleaks are common and occur in 10-30% of patients after EVAR [1]. While most of these can be treated with careful follow up, persistent type II endoleaks are associated with adverse outcomes [2]. Therefore it is customary to follow up EVAR patients for life. Only 50% of patients are compliant with follow up imaging in the USA at five years from the operation [3].

One of the problems in following up endoleaks is to decide when to intervene, and then decide if the intervention had been successful. Once the presence of endoleak has been determined, progressive enlargement of the sac is considered to be the usual trigger for further intervention. However this may not always be able to predict the natural course of events, if nothing is done. Furthermore there are some patients who show sac enlargement without the presence of a demonstrable endoleak. In such cases the doctor is faced with the dilemma of whether to escalate the level of investigation, such as

invasive catheter based angiography, or to wait. Also endoleaks can occur in the interval between two surveillance imaging.

D Dimers are noted to be elevated in patients with abdominal aortic aneurysms and it has been proposed as a biomarker [4]. It has been extensively studied in the setting of untreated abdominal aortic aneurysm, where there are layers of clot lining the wall of the sac, where the clot is in contact with circulating blood. Logically it should follow that after excluding the aneurysm sac as happens when a patient undergoes an EVAR, the D Dimer levels should improve. And there is evidence that shows that this does indeed happen [5].

Serial measurement of D Dimer in patients who have had an EVAR may add benefit over and above the current serial imaging protocol, and may be used as a test that can provide an alternative to imaging in the intervals between two scheduled imaging follow ups. It may also increase compliance with follow up. Serial D Dimers may also help to differentiate benign endoleaks from those that need to be treated.

A further benefit will be in the follow up of the patients who have had the new Endovascular Aneurysm Sealing (EVAS). These patients cannot be followed up by traditional duplex scans for type II endoleaks and will require CT scans. Measuring serial D Dimer levels may reduce the frequency of CT scans thereby reducing the cumulative radiation dose to the patient.

This is a new observation and further studies are required to validate this finding.

## References

1. Sarac TP, Gibbons C, Vargas L, Liu J, Srivastava S, et al. (2012) Long-term follow-up of type II endoleak embolization reveals the need for close surveillance. *J Vasc Surg* 55: 33-40.
2. Jones JE, Atkins MD, Brewster DC, Chung TK, Kwolek CJ, et al. (2007) Persistent type 2 endoleak after endovascular repair of abdominal aortic aneurysm is associated with adverse late outcomes. *J Vasc Surg* 46: 1-8.
3. Schanzer A1, Messina LM2, Ghosh K3, Simons JP2, Robinson WP 3rd2, et al. (2015) Follow-up compliance after endovascular abdominal aortic aneurysm repair in Medicare beneficiaries. *J Vasc Surg* 61: 16-22.
4. Sidloff DA, Stather PW, Choke E, Bown MJ, Sayers RD (2014) A systematic review and meta-analysis of the association between markers of hemostasis and abdominal aortic aneurysm presence and size. *J Vasc Surg* 59: 528-535.
5. Monaco M, Di Tommaso L, Stassano P, Smimmo R, De Amicis V, et al. (2006) Impact of blood coagulation and fibrinolytic system changes on early and mid term clinical outcome in patients undergoing stent endografting surgery. *Interact Cardiovasc Thorac Surg* 5: 724-728.